

Cochlear Implantation in Patients with Special Situation

Hisashi Sugimoto¹, Makoto Ito², Miyako Hatano¹, Hiroki Hasegawa¹, Masao Noda¹, Tomokazu Yoshizaki^{1*}

ABSTRACT

Objectives: We have been using the "Subtotal petrosectomy" or "Canal wall down mastoidectomy" technique for the cochlear implantation of difficult cases. We also added the "Blind sac closure of external auditory canal (EAC)" and "Middle ear and mastoid Obliteration by abdominal fat" technique as necessary.

Methods: Retrospective analysis of seven special cases of cochlear implantation was carried out. The detailed breakdown of the cases is as follows: Post radical mastoidectomy -- 2 cases, Adhesive otitis media -- 1 case, Eosinophilic otitis media -- 2 cases, Temporal bone malformation -- 2 cases. Complications, hearing threshold results, word recognition, and bleeding were analyzed.

Results: For one of the cases of Post radical mastoidectomy, the patient suffered from a breakdown of the EAC closure. The hearing threshold following the procedures ranged from 25 to 35 dB with an average of 30.3dB. The word recognition results were 0 to 96% with an average of 60% and sentence recognition results ranged from 0 to 100% with an average of 62%. The volume of blood loss ranged between less than 5 mL and 170 mL.

Conclusions: The combination of these techniques has potential to be effective for the cochlear implantation of such difficult cases.

KEYWORDS: Petrosectomy, Cochlear implantation, Auditory canal, Post radical mastoidectomy

INTRODUCTION

Patients with profound hearing loss are able to acquire the ability to hear by receiving an operation to emplace a cochlear implant, and this result in a remarkable improvement in their quality of life. As of this time, many patients have enjoyed the benefits of this procedure. For patients in which the middle and inner ear present a normal form and in which there is no pathological change to the temporal bone, the classical facial recess technique is usually used with extremely few resultant complications. Previous studies of the classic technique report major complication rates of between 3.0 and 13.7% [1-4]. On the other hand, there are quite a few difficult cases for which classical facial recess technique for

cochlear implant cannot be employed. Fisch et al. proposed subtotal petrosectomy in 1988, and five years after that Parnes et al. employed this approach for the first time in a difficult cochlear implant case. This procedure involved a closure of the external auditory canal (EAC) and the Eustachian tube and obliteration of the surgical cavity. Following this case, this procedure became the standard cochlear implant method used for difficult cases, and this in turn has led to debate over the usefulness and safety of the procedure [5-14]. However, since the total number of cases is small, the validity and safety cannot be irrefutably established. Thus, it is extremely important to ascertain the as of yet hypothetical usefulness and safety for patients undergoing such special cases of cochlear implant procedures. In this report we present our experiences with seven such special cases of cochlear implants. In this report we wish to

contribute further to the investigation about the safety and suitability so that even if only by a small amount more patients with difficult cases can enjoy the benefit of cochlear implant.

MATERIAL AND METHODS

PATIENTS

We did a retrospective analysis of seven special cases of cochlear implantation carried out in the Department of Otorhinolaryngology at the Kanazawa University Hospital between 2012 and 2016. The detailed breakdown of the cases is as follows: Post radical mastoidectomy -- 2 cases, Adhesive otitis media -- 1 case, Eosinophilic otitis media -- 2 cases, Temporal bone malformation -- 2 cases (Table 1). For the two cases of eosinophilic otitis media subtotal petrosectomy, cochlear implantation, and obliteration of the mastoid using abdominal fat was carried out (Fig. 1).

¹Department of Otolaryngology-Head and Neck Surgery, Kanazawa University Graduate School of Medical Science, Kanazawa, Japan,

²Pediatric Otolaryngology, Jichi Children's Medical Center Tochigi, Jichi Medical University

*tomoy@med.kanazawa-u.ac.jp.

Table 1. Summary of seven special cases.

Patient	Age	Sex	Side	Etiology	Operative procedure	Complications	Bleeding	Implant	Electrode outside cochlear	Hearing threshold before CI	Hearing threshold after CI	Speech preception (CI2004)	Follow up
1	69	F	Lt	Redical cavity	Simple suture of EAC Canal wall mastoidectomy closure of the eustachian tube	Suture failuer of EAC	100 ml	Cochlear CI24	0/22	105dB	30dB	Word 48% Sentense 61%	45M
2	72	M	Rt	Redical cavity	Blind sac closure to EAC Canal wall down mastoidectomy middle ear and mastoid obliteration by abdominal fat closure of the eustachian tube	No	<5 ml	Cochlear CI24	0/22	105dB	28dB	Word 60% Sentense 40%	31M
3	79	M	Lt	atelectasis	Subtotal petrosectomy blind sac closure of EAC middle ear and mastoid obliteration by abdominal fat closure of the eustachian tube	No	<5 ml	Cochlear CI24	0/22	103.8dB	25dB	Word 64% Sentense 71%	21M
4	64	M	Lt	Eosinophilic otitis media	Subtotal petrosectomy blind sac closure of EAC middle ear and mastoid obliteration by abdominal fat closure of the eustachian tube	No	170 ml	Cochlear CI24	0/22	105dB	30dB	Word 96% Sentense 91%	31M
5	71	M	Rt	Eosinophilic otitis media	Subtotal petrosectomy blind sac closure of EAC middle ear and mastoid obliteration by abdominal fat closure of the eustachian tube	No	50 ml	Cochlear CI24	0/22	102.5dB	34dB	Word 60% Sentense 71%	18M
6	9	M	Lt	Inner ear Malformation	Blind sac closure of EAC Canal wall down mastoidectomy	No	50ml	Cochlear CI24	0/22	105dB	35dB	Word 0% Sentense 0%	57M
7	41	M	Rt	Inner ear Malformation	Blind sac closure of EAC Canal wall down mastoidectomy	No	<5 ml	Cochlear CI24	0/22	97.5dB	30dB	Word 2% Sentense 100%	52M

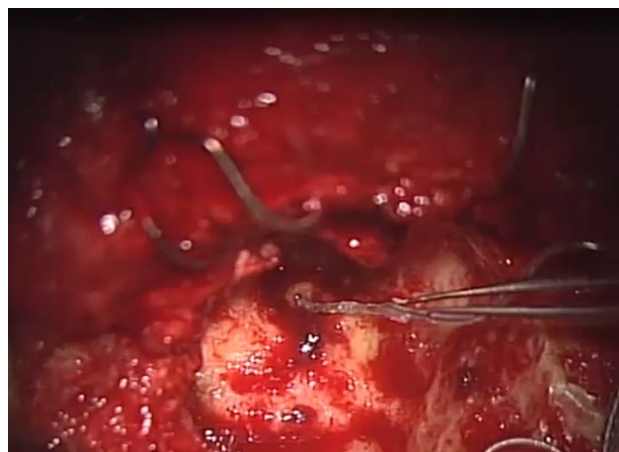


Fig 1. Left ear of patient 4 after subtotal petrosectomy. A good field of view and ample working space was ensured.

For one of the two cases of post radical mastoidectomy closure of the external auditory canal using blind sac closure, cochlear implantation, and obliteration of the mastoid using abdominal fat were carried out (Fig. 2). For the other case of

Post radical mastoidectomy, the external auditory canal was closed, but blind sac closure was not used. Mastoid obliteration was also not performed. For a case of Adhesive otitis media, canal wall down mastoidectomy, cochlear implantation,

and mastoid obliteration using abdominal fat were carried out. For the two cases of Temporal bone malformation, closure of the external auditory canal using blind sac closure, canal wall down mastoidectomy and cochlear implantation were carried

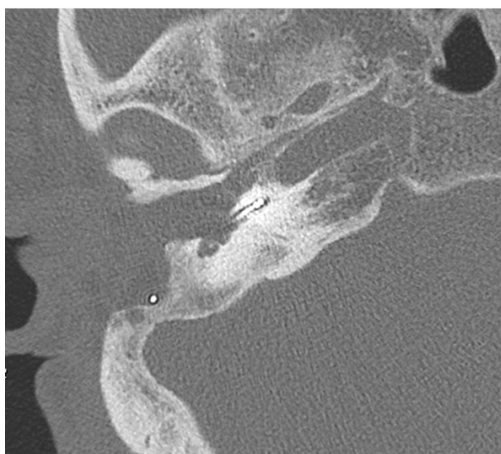

Fig 2. Postoperative CT scan of Patient 2 (right ear).

out. Obliteration of the mastoid was not carried out. Complications, hearing threshold results, word recognition, and bleeding were the four items analyzed in these seven cases. Permission for this retrospective study was obtained from the Kanazawa University Hospital, the local Ethics Committee approved the study protocol. Informed written consent was obtained from all patients.

RESULTS

The average period of observation was 36.4 months. Six of the patients were male, and one was female. Patient age ranged from nine to 79 years with an average age of 57.9. All of the surgical techniques employed in each case were carried out as one combined operation. For all of the cases cochlear implantation was performed using Cochlear CI24 with zero electrodes outside of the cochlear. For one of the cases of Post radical mastoidectomy the patient suffered a breakdown of the EAC closure. In this case ear discharge continued for three months following the procedure, but this complication disappeared with the EAC finally closing again naturally. In this case blind sac closure was not performed and the middle ear and the mastoid were not obliterated. There were no complications in any of the other cases. Hearing threshold results following the procedures ranged from 25 to 35dB with an average of 30.3dB. Word recognition results were 0 to 96% with an average of 60% in the case of words, and 0 to 100% with an average of 62% in the case of sentences. The volume of blood loss

varied between less than 5 mL and 170 mL. Blood transfusion was not required in any of the cases.

DISCUSSION

We have used the "Subtotal petrosectomy" or "Canal wall down mastoidectomy" technique to approach for kinds of difficult cases related to cochlear implantation. A detailed discussion of the cochlear implant technique as it was applied in each of these four clinical states follows.

EARS AFTER RADICAL MASTOIDECTOMY

Of the two cases of ears following radical mastoidectomy in this study, there was a suture failure of the EAC in the first case. In this case we didn't use the blind sac closure technique when suturing the EAC. Furthermore, obliteration of the mastoid was not carried out. Since the diameter of the EAC following radical mastoidectomy is larger as compared to that of a normal EAC, a simple suturing of the EAC may lead to imperfect closure. Fisch considered the EAC suturing using blind sac closure to be a safe, effective procedure [15]. It is also an advisable application when carrying out cochlear implantations in radical cavities. In the second case, the lateral semicircular canal in the right ear had been destroyed in a previous operation. Prior to this operation a caloric test was conducted and CP (canal paresis) was pointed out. Due to this and in order to preserve vestibular function, an operation was carried out on the previously destroyed lateral semicircular canal in the right ear.

The period of hearing loss in the right ear had been long, but following the operation an improvement in the hearing level of up to 25dB was attained. The canal paresis on the right side caused a remarkable reduction in the patient's QOL. Therefore, despite the long period of hearing loss, it is recommended to proceed with caution.

ADHESIVE OTITIS MEDIA

Xenellis et al. reported about cochlear implantations for four patients who were suffering from adhesive otitis media. They concluded that Blind-sac closure of the external auditory canal without obliteration is a rather safe surgical procedure in cases with atelectasis, and a 2-stage procedure may not always be necessary and indeed might best be limited to those patients who have active inflammatory disease at the time of the primary procedure [16]. The cases that we dealt with in this study had no inflammation, so the operations were carried out as single, comprehensive procedures. There were no complications in these cases. The difference between our cases and those reported by Xenellis et al. was as concerns the inclusion of Mastoid obliteration. We perform mastoid obliteration to prevent hemorrhage effusion and prevent infection in the post-operative dead space. However, we believe that the most important purpose of mastoid obliteration is to counter post-operative spinal fluid leakage. It is not necessarily always required to take these precautions in cases of adhesive otitis media in which these risks are not present. In order to determine which is

best, more reports from further cases are required. In the cases related to this study a caloric test was carried out, the absence of canal paresis was confirmed, and the operative side was selected. Similar to the cases of mastoidectomy, we feel that consideration of the vestibular function in cases of adhesive otitis media is important for selecting the operative side.

EOSINOPHILIC OTITIS MEDIA

In this study there were two cases of eosinophilic otitis media for which cochlear implantation was performed. The surgical procedure was a subtotal petrosectomy. The concepts of the surgery consist of the following two points: (i) Removal of mucosa from the middle ear and the mastoid cavity as completely as possible in order to remove the theater of eosinophilic infiltration; (ii) Closure of the Eustachian tube and the external auditory canal in order to prevent leaching of foreign substances and entry of stimuli which are the cause of eosinophilic inflammations. There were no complications or recurrent inflammation following surgery in the cases of both patients. Following the procedure, the hearing threshold results of the two patients were 30dB and 34dB [17]. This is the first discussion focusing on cochlear implantations for cases of eosinophilic otitis media. To further confirm the efficacy and safety of our surgical concept, we need to administer this treatment concept for a larger number of cases in a future study.

TEMPORAL BONE MALFORMATION

As for the cases of temporal bone malformation, because the anatomical landmark cannot be trusted, the identification of the place to open the cochlea is problematic. Furthermore, in cases of temporal bone malformation it has been reported that carrying out the cochleostomy can result in gushers. Therefore, for temporal bone malformation cases we feel it is critical to ensure that there is a good operative field of view and ample working space. Canal wall down mastoidectomy technique resolves these two problems. Mistakes in the location for opening the cochlea are reduced. What's more, the measures for dealing with gushers become much easier.

In the first temporal bone malformation case in this study, the first operation employed was a classical facial recess technique. However, due to a traveling abnormality of the facial nerve and a deformity in the inner ear, we couldn't identify the location to open the cochlea. In the second operation a subtotal petrosectomy was employed resulting in a good operative field of view. Thus, we could open the cochlea. Therefore, we think that in cases of temporal bone malformation this canal wall down technique is extremely useful for cochlear implantation.

SUBTOTAL PETROSECTOMY AND CANAL WALL DOWN MASTOIDECTOMY

Ensuring a good operative field and ample working space are two common, important points when performing cochlear implantation for special cases. Use of subtotal petrosectomy and canal wall down mastoidectomy can overcome difficulties related to these two points. Also, closure of the Eustachian tube and the EAC can isolate them from the exterior preventing operation related infection [18]. Thus we feel that for special cases this is a useful procedure.

STAGED OPERATION

Linder et al. recommended a staged operation for cases with the following four conditions: 1. Suppurative and continuously draining otitis media, 2. Previous tympanomastoid surgeries with "unstable" disease, 3. Extended cholesteatomas, and 4. Previously irradiated temporal bone [14]. We regard this strategy as appropriate. For the cases in this study none of these four conditions applied. Thus, a single operation was selected. There were no severe complications.

MASTOID OBLITERATION

Whether or not to employ mastoid obliteration is an essential topic that must be discussed. In cases where mastoid obliteration is employed, the choice of the obliterating materials is also an important issue. We feel that it is necessary to fill the mastoid space in cases for which post-operative inflammation is possible. We especially feel that in cases in which

dura mater is exposed or in which there is CSF leakage, filling the mastoid space is necessary. Following radical mastoidectomy, eosinophilic otitis media, and adhesive otitis media, amongst other conditions, it is favorable to fill the mastoid space to prevent inflammation caused by exuded liquid or blood. On the other hand, in cases such as temporal bone malformation in which there has been no inflammation and the dura mater or CSF leakage is not occurring, filling the mastoid space is not necessary. Previous reports indicate that for blood flow in the temporal muscle, abdominal fat is the filling material used. Hellingman suggests that the most suitable material to obliterate the cavity appears to be abdominal fat because of its resistance to necrosis and easy removal if cochlear implantation is performed later. On the other hand, Fisch et al. propose that, after subtotal petrosectomy, if dura mater exposure or CSF leakage are involved and there is inflammation, then the temporal muscle with blood flow or the sternocleidomastoid muscle should be adopted [15]. For our cases in this study there was no exposure of dura mater nor was there any CSF leakage involved, so abdominal fat was adopted as the filling material, and there were no post-operative complications.

VESTIBULAR FUNCTION

When selecting on which side to perform the procedure, evaluation of the vestibular function is essential. Especially in cases of Radical cavity or ears following inner ear procedures, it is necessary to administer the caloric test and confirm the presence or absence of paralysis of the semicircular canal. Bilateral loss of vestibular function is a complication that must be avoided, and we believe this takes priority over post-operative hearing acquisition. We think that compared to more mainstream cases, cochlear implantation following radical mastoidectomies and other special cases can result in a higher risk of deterioration of vestibular function, so as much as possible it is necessary to make pre-operative evaluations.

CONCLUSION

We have performed cochlear implantations in cases of Radical cavity,

Adhesive otitis media, Eosinophilic otitis media, and Temporal bone malformation. For all of the cases subtotal petrosectomy or canal wall down mastoidectomy was applied. We also added the "Blind sac closure of EAC" and "Middle ear and mastoid Obliteration by abdominal fat" technique as necessary. As a result of the combination of these methods, a good field of view and ample working space were ensured. Except for EAC breakdown, there were no complications. Hearing threshold results and word recognition were markedly improved following the operation, and blood loss volume was extremely small. In the future we hope to increase the number of patients with special cases who will receive the benefits of this cochlear implant method.

REFERENCES

1. Proops DW, Stoddart RL, Donaldson I (1999) Medical, surgical and audiological complications of the first 100 adult cochlear implant patients in Birmingham. *The Journal of Laryngology & Otology* 113: 14-17. doi: 10.1017/s002221510014602x PMID: 10664723
2. Hoffman RA, Cohen NL (1995) Complications of cochlear implant surgery. *The Annals of otology, rhinology & laryngology. Supplement* 166: 420-422. PMID: 7668733
3. Collins MM, Hawthorne MH, El-Hmd K (1997) Cochlear implantation in a district general hospital: problems and complications in the first five years. *The Journal of Laryngology & Otology* 111: 325-332. doi: 10.1017/s0022215100137235 PMID: 9176612
4. Aschendorff A, Marangos N, Laszig R (1997) Complications and reimplantation. *Advances in Oto-Rhino-Laryngology* 52: 167-170. doi: 10.1159/00058982
5. Hellingman CA, Dunnebie EA (2009) Cochlear implantation in patients with acute or chronic middle ear infectious disease: a review of the literature. *European Archives of Oto-Rhino-Laryngology* 266: 171-176. doi: 10.1007/s00405-008-0828-0
6. Baranano CF, Kopelovich JC, Dunn CC, Gantz BJ, Hansen MR (2013) Subtotal petrosectomy and mastoid obliteration in adult and pediatric cochlear implant recipients. *Otology & Neurotology* 34: 1656-1659. doi: 10.1097/mao.0b013e3182a006b6 PMID: 24136310
7. Basavaraj S, Shanks M, Sivaji N, Allen AA (2005) Cochlear implantation and management of chronic suppurative otitis media: single stage procedure?. *European Archives of Oto-Rhino-Laryngology* 262: 852-855. doi: 10.1007/s00405-004-0907-9 PMID: 15756568
8. Pasanisi E, Vincenti V, Bacciu A, Guida M, Berghenti T et al. (2002) Multichannel cochlear implantation in radical mastoidectomy cavities. *Otolaryngology-Head and Neck Surgery* 127: 432-436. doi: 10.1067/mhn.2002.129822 PMID: 12447237
9. Babighian, G (1993) Problems in cochlear implant surgery. *Advances in Oto-Rhino-Laryngology*, 48: 65-69. doi: 10.1159/000422560
10. Axon PR, Mawman DJ, Upile T, Ramsden RT (1997) Cochlear implantation in the presence of chronic suppurative otitis media. *The Journal of Laryngology & Otology* 111: 228-232. doi: 10.1017/s0022215100136977 PMID: 9156058
11. Leung, R, Briggs RJ (2007) Indications for and outcomes of mastoid obliteration in cochlear implantation. *Otology & Neurotology* 28: 330-334. doi: 10.1097/mao.0b013e318031161f PMID: 17414038
12. Issing PR, Schonermark MP, Winkelmann S, Kempf HG, Ernst A (1998) Cochlear implantation in patients with chronic otitis: indications for subtotal petrosectomy and obliteration of the middle ear. *Skull base surgery* 8: 127-131. doi: 10.1055/s-2008-1058571 PMID: 17171047
13. Polo R, Del Mar Medina M, Aristegui M, Lassaletta L, Gutierrez A, et al. (2015) Subtotal Petrosectomy for Cochlear Implantation: Lessons Learned After 110 Cases. *The Annals of otology, rhinology, and laryngology* 25: 485-494. doi: 10.1177/0003489415620427 PMID: 26658067
14. Szymanski M, Ataide A, Linder T (2016) The use of subtotal petrosectomy in cochlear implant candidates with chronic otitis media. *European archives of oto-rhino-laryngology* 273: 363-370. doi: 10.1007/s00405-015-3573-1 PMID: 25708413
15. Fisch U, Mattox, D (1998) Microsurgery of the skull base. Thieme.
16. Xenellis J, Nikolopoulos TP, Marangoudakis P, Vlastarakos PV, Tsangaroulakis A, et al. (2008) Cochlear implantation in atelectasis and chronic otitis media: long-term follow-up." *Otology & neurotology* 29: 499-501. doi: 10.1097/MAO.0b013e31816a8986 PMID: 18520585
17. Sugimoto H, Hatano M, Noda M, Hasegawa H, Yoshizaki T (2016) Cochlear implantation in deaf patients with eosinophilic otitis media using subtotal petrosectomy and mastoid obliteration. *European archives of oto-rhino-laryngology* 274: 1173-1177. doi: 10.1007/s00405-016-4091-5 PMID: 27168402
18. Polo R, Del Mar Medina M, Aristegui M, Lassaletta L, Gutierrez A, et al. (2015) Subtotal Petrosectomy for Cochlear Implantation: Lessons Learned After 110 Cases. *The Annals of otology, rhinology, and laryngology* 125 (2015): 485-494.