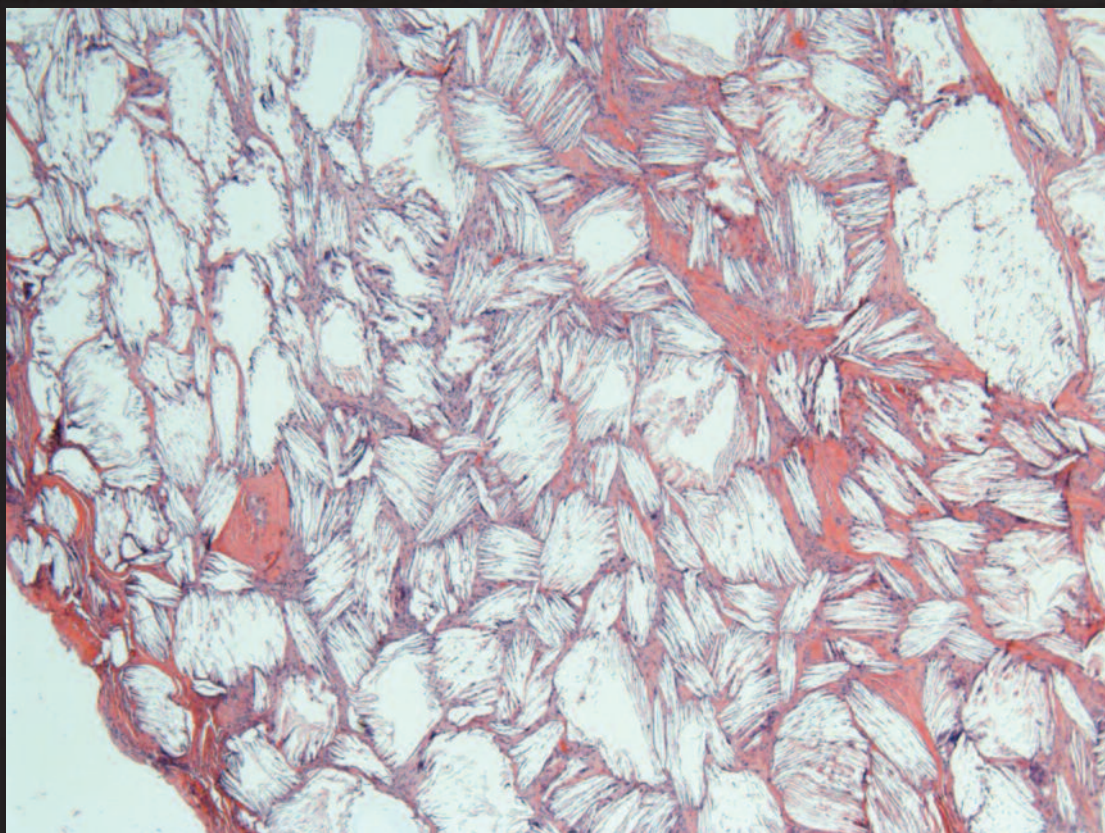


Canadian Journal of

Volume 5, Issue 4 • Winter 2013-2014

Pathology

Official Publication of the Canadian Association of Pathologists



**Reporting on Histopathology Specimens
from the Cervix and Vagina
Cancer Stem Cells: Clinical Relevance**

Publications Agreement Number 40025049 • ISSN 1918-915X



www.cap-acp.org



Published by
ANDREW JOHN
PUBLISHING INC.



Join us for our **65th Annual Meeting of the Canadian Association of Pathologists**



“Celebrating 65 years of Excellence
in Pathology”

July 12-15, 2014 | TORONTO

Hyatt Regency
370 King Street, Toronto, ON

For more information please visit,
cap-acp.com

EDITOR-IN-CHIEF

J. Godfrey Heathcote, MA, MB BChir, PhD, FRCPC

EDITORIAL BOARD

Manon Auger, MD, FRCPC, Cytopathology;
Calvino Cheng, BSc, MD, FRCPC, Pathology Informatics
and Quality Management;
Pierre Douville, MD, FRCPC, Medical Biochemistry;
David K. Driman, MB ChB, FRCPC, Anatomical Pathology;
Lawrence Haley, MD, FRCPC, Hematopathology;
Todd F. Hatchette, BSc, MD, FRCPC, Medical Microbiology;
Michael J. Shkrum, MD, FRCPC, Forensic Pathology;

FOUNDING EDITOR

Jagdish Butany, MBBS, MS, FRCPC

MANAGING EDITOR

Susan Harrison

COPY EDITORS

Scott Bryant, Susan Harrison

PROOFREADER

Scott Bryant

ART DIRECTOR

Andrea Mulholland, amuholland@allegrahamilton.ca

TRANSLATOR

Suzanne Legendre

SALES AND CIRCULATION COORDINATOR

Brenda Robinson, robinson@andrewjohnpublishing.com

ACCOUNTING

Susan McClung

GROUP PUBLISHER

John D. Birkby, jbirkby@andrewjohnpublishing.com

Canadian Journal of Pathology is published four times annually by Andrew John Publishing Inc., with offices at 115 King Street West, Dundas, ON, Canada L9H 1V1. We welcome editorial submissions but cannot assume responsibility or commitment for unsolicited material. Any editorial material, including photographs that are accepted from an unsolicited contributor, will become the property of Andrew John Publishing Inc.

FEEDBACK

We welcome your views and comments. Please send them to Andrew John Publishing Inc., 115 King Street West, Dundas, ON, Canada L9H 1V1. Copyright 2013 by Andrew John Publishing Inc. All rights reserved. Reprinting in part or in whole is forbidden without express written consent from the publisher.

Publications Agreement Number 40025049 • ISSN 1918-915X
Return undeliverable Canadian Addresses to:



115 King Street West, Suite 220, Dundas, ON L9H 1V1



Contents

124 Editorial: Screening, Over-diagnosis, and Uncertainty
J. Godfrey Heathcote, MA, MB BChir, PhD, FRCPC

126 Éditorial : Dépistage, surdiagnostic et incertitude
J. Godfrey Heathcote, MA, MB BChir, PhD, FRCPC

CAP-ACP News

128 Pathologists' Assistants: Defining a Standard in a Uniquely Diverse Population of Professionals
Danielle Lee, BSc (MLS)

Consensus Statements

130 Reporting on Histopathology Specimens from the Cervix and Vagina: Consensus Statements from the Pan-Canadian Cervical Screening Initiative
Submitted by Dr. C. Meg McLachlin on behalf of the Pan-Canadian Cervical Screening Initiative Working Group

Original Articles

134 Orbital Osteitis in Clinically Unsuspected Syphilis
J. Godfrey Heathcote, MB, PhD, FRCPC, Ridas Juskevicius, MD, Alejandra A. Valenzuela, MD

138 Case Report: Cholesterol Granuloma in the Anterior Mediastinum
Abbas Akhdar, MD, Marco Sirois, MD, FRCSC, Eric Turcotte, MD, FRCPC, Sameh Geha, MD

Current Review

141 Cancer Stem Cells: Clinical Relevance
Krysta M. Coyle, BSc, and Paola Marcato, PhD

Book Reviews

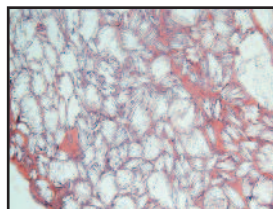
150 Pathology Review
Reviewed by David Driman, MBChB, FRCPC

151 In Situ Molecular Pathology and Co-Expression Analyses
Reviewed by G. Dellaire, PhD

Professional Development/Employment Opportunities

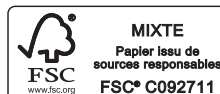140 McGill University

About the Cover



The cover image shows the microscopic appearance of cholesterol granuloma.

For Instructions to Authors, please visit
<http://www.andrewjohnpublishing.com/CJP/instructionstoauthors.html>



Screening, Over-diagnosis, and Uncertainty

One of the intriguing developments of the past few years has been the increasing scrutiny applied to screening programs for cancer. It is now almost impossible to scan a general medical journal without coming across a scientific study, editorial, opinion piece, or “news” item on the risks and benefits of such programs. At the same time as laboratory physicians are focusing attention on the over-utilization of laboratory tests, our clinical colleagues are dealing with the potential for over-diagnosis and patient harm associated with screening tests. Given that the majority of these programs are based on laboratory investigations, it behoves pathologists and laboratory physicians to follow the changing evidence and recommendations.

Cervical cytology, the undoubted success story of cancer screening, has come under scrutiny recently. With the recognition that some of the cytological abnormalities seen in young women under the age of 25 years may resolve spontaneously and not progress to cancer, there has been a move away from screening in this age group. The guidelines published earlier this year by the Canadian Task Force on Preventive Health Care are clear on this point: there is “no benefit to outweigh the potential harms.”¹ Although false-positive tests clearly cause anxiety and may lead to over-treatment, a change in guidelines such as this may provoke controversy, as it has in the United Kingdom.² With the possible replacement of cervical cytology by human papillomavirus testing, new screening guidelines will in any case be required.

There is now a bewildering number of articles relating to the benefits and harms of mammographic screening for breast cancer. Although mammography is not of itself a laboratory test, the interpretation of the radiographic appearance influences whether or not a lesion is biopsied, with the attendant risk of over-diagnosis and over-treatment. But what is over-diagnosis? As defined by Welch,³ over-diagnosis is “the detection of abnormalities that will never cause symptoms or death during a patient’s lifetime,” and it has become a major concern. One Norwegian study suggested that for every life saved from invasive breast cancer, six to 10 women are over-diagnosed by screening.⁴ Jorgensen et al. reported that, although the incidence of ductal carcinoma

in-situ (DCIS) had increased as a result of screening, there was no reduction in the incidence of invasive carcinoma and that reductions in the mortality of breast cancer were not the result of screening but, rather, the introduction of tamoxifen therapy and an overall heightened awareness of the significance of lumps in the breast.⁵ Esserman et al. have suggested that use of the word *cancer* should be restricted to lesions that are likely to be lethal if left untreated, and that pre-malignant lesions, such as DCIS, should be termed *indolent lesions of epithelial origin* (IDLE).⁶ These authors recommend the establishment of observational registries of such lesions to determine the risk of, and time required for, the development of invasive cancer, as well as the prognosis of the resulting invasive tumours.

Decades ago Sammy Franks, a pathologist in London, England, demonstrated a high rate of malignant changes in prostate glands examined at autopsy and concluded that most, if not all, men would develop these changes if they lived long enough. Put simplistically, the question for all men as they age is whether they will die *with* prostate cancer or *of* prostate cancer. The introduction of screening for prostate cancer by measuring the serum concentration of prostate-specific antigen (PSA) has increased the incidence of the cancer dramatically but has not reduced the death rate.⁷ Moreover, PSA-based screening does not provide a clear answer to the above question. Low-risk disease is still often treated by radical prostatectomy even though the mortality is low (~3%).⁸ The Prostate cancer Intervention Versus Observation Trial (PIVOT) has suggested that surgery is of value in high-risk disease but that the standard of care for low-risk disease is continued observation.⁸ Again it appears that the easy availability, and promotion, of a screening test has led to over-diagnosis and over-treatment. Most men, whatever their age, would not consider the complications of radical prostatectomy to be trivial, and the diagnostic transrectal biopsy itself carries serious risks, including septic shock. In the absence of bio-markers for serious, that is, life-threatening, disease, the UK National Screening Committee and the US Preventive Services Task Force do not recommend screening with the PSA test.⁹

What then is the role of pathologists and laboratory

physicians in these screening controversies? Firstly we need to remind ourselves, our clinical colleagues, and the public that screening is for asymptomatic people and screening tests are not necessarily sound diagnostic tests. We need to continue to study the natural history of pre-malignant lesions and the bio-markers associated with them. In particular, we need to identify genetic bio-markers that will predict aggressive behaviour in malignant tumours. Lastly we need to be very precise in our use of terminology and ensure that our students and residents understand the importance of this. If pathologists do not protect the nomenclature and terminology of disease, who will?

J. Godfrey Heathcote, MA, MB BChir, PhD, FRCPC
Editor-in-Chief

[Editor's note: A future issue of the Journal will contain articles on the PSA test and the morphological diagnosis of prostate cancer.]

References

1. Canadian Task Force on Preventive Health Care. Recommendations on screening for cervical cancer. *CMAJ* 2013;185:35–45.
2. McCartney M. Why it is wrong to promote cervical screening in under 25s. *BMJ* 2011;343:673.
3. Welch HG. Overdiagnosis and mammography screening. *BMJ* 2009;339:182–3.
4. Kalager M, Adami H-O, Bretthauer M, Tamimi RM. Overdiagnosis of invasive breast cancer due to mammography screening: results from the Norwegian screening program. *Ann Intern Med* 2012;156:491–9.
5. Jorgensen KJ, Keen JD, Gotzsche PC. Is mammographic screening justifiable considering its substantial overdiagnosis rate and minor effect on mortality? *Radiology* 2011;260:621–7.
6. Esserman LJ, Thompson IM Jr, Reid B. Overdiagnosis and overtreatment in cancer. An opportunity for improvement. *JAMA* 2013;310:797–8.
7. Sandblom G, Varenhorst E, Rosell J, et al. Randomised prostate cancer screening trial: 20 year follow-up. *BMJ* 2011;342:908.
8. Parker C. Treating prostate cancer. *BMJ* 2012;345:9.
9. Wilt TJ, Ahmed HU. Prostate cancer screening and the management of clinically localized disease. *BMJ* 2013;346:28–33.

Dépistage, surdiagnostic et incertitude

L'un des changements les plus intrigants depuis quelques années est l'attention accrue portée aux programmes de dépistage du cancer. Il est maintenant quasi impossible de lire une revue médicale sans tomber sur une étude scientifique, un éditorial, un texte d'opinion ou un article d'actualité portant sur les risques et les bienfaits de tels programmes. Alors que les médecins de laboratoire dirigent leur attention sur la surutilisation des épreuves de laboratoire, nos collègues cliniciens font face à la possibilité de surdiagnostic et de préjudices aux patients associés aux tests de dépistage. Étant donné que la majorité de ces programmes reposent sur des épreuves de laboratoire, il incombe aux pathologistes et aux médecins de laboratoire de suivre les données et les recommandations en évolution. La cytologie cervicale, réussite incontestée du dépistage du cancer, a récemment fait l'objet d'un examen attentif. Avec la réalisation que certaines anomalies cytologiques observées chez les jeunes femmes de moins de 25 ans peuvent disparaître spontanément et ne pas évoluer vers un cancer, on s'éloigne maintenant du dépistage dans ce groupe d'âge. Les lignes directrices publiées cette année par le Groupe d'étude canadien sur les soins de santé préventifs sont très claires sur ce point : il n'y a aucun bienfait qui l'emporte sur les préjudices potentiels¹. Bien que les résultats faussement positifs puissent occasionner de l'anxiété et mener au surtraitement, une telle modification des lignes directrices peut susciter la controverse, comme il a été le cas au Royaume Uni². Avec le remplacement possible de la cytologie cervicale par le test de dépistage du virus du papillome humain, de nouvelles lignes directrices de dépistage devront être formulées.

Il existe un nombre impressionnant d'articles portant sur les bienfaits et préjudices du dépistage mammographique dans le cancer du sein. Bien que la mammographie ne soit pas une épreuve de laboratoire, l'interprétation des clichés radiographiques influe sur la décision d'effectuer ou non une biopsie d'une lésion, avec le risque associé de surdiagnostic et de surtraitement. Mais qu'est ce qui constitue le surdiagnostic? Selon Welch³, le surdiagnostic est « la détection d'anomalies qui n'entraîneront jamais de symptômes ou de décès au cours de la vie de la patiente » et

cela est devenu une préoccupation majeure. Selon une étude norvégienne, pour chaque vie sauvée du cancer du sein invasif, six à dix femmes sont surdiagnostiquées par dépistage⁴. Jorgensen et ses collègues ont rapporté que bien que l'incidence du carcinome canalaire in situ (CCIS) se soit accrue par suite du dépistage, il n'y a eu aucune réduction dans l'incidence du carcinome invasif. De plus, les réductions du taux de mortalité par cancer du sein n'étaient pas dues au dépistage mais plutôt à l'introduction du traitement par tamoxifène et à une sensibilisation accrue de l'importance des masses dans le sein⁵. Esserman et ses collègues ont proposé que l'emploi du terme *cancer* soit limité aux lésions qui sont susceptibles d'être fatales en l'absence de traitement, et que les lésions précancéreuses, comme le CCIS, doivent être appelées « *lésion indolente d'origine épithéliale* »⁶. Ces auteurs recommandent la tenue de registres d'observation de ce type de lésions afin de déterminer le risque et le délai de développement d'un cancer invasif, ainsi que le pronostic des tumeurs invasives résultantes.

Il y a plusieurs décennies, Sammy Franks, pathologiste à Londres en Angleterre, a mis en évidence un taux élevé de modifications malignes dans les prostates examinées à l'autopsie et il a conclu que la plupart, voire la totalité des hommes développeraient ces modifications s'ils vivaient suffisamment longtemps. En bref, la question pour tous les hommes à mesure qu'ils vieillissent est s'ils mourront *avec* un cancer de la prostate ou *des suites du* cancer de la prostate. L'introduction du dépistage du cancer de la prostate par le dosage sérique de l'antigène prostatique spécifique (APS) a nettement augmenté l'incidence du cancer de la prostate mais n'a pas réduit le taux de mortalité⁷. De plus, le dépistage fondé sur le dosage de l'APS ne permet pas de répondre clairement à cette question. La maladie à faible risque est encore souvent traitée par prostatectomie radicale malgré le faible taux de mortalité (~3 %)⁸. Les résultats de l'étude PIVOT (Prostate cancer Intervention Versus Observation Trial) semblent indiquer que la chirurgie est pertinente dans les cas de maladie à risque élevé mais que le traitement standard pour la maladie à faible risque consiste à assurer une observation continue⁸. Une fois encore, il semble que la

facilité d'accès et la promotion du test de dépistage ont mené au surdiagnostic et au surtraitement. La plupart des hommes, quel que soit leur âge, ne considèrent pas les complications de la prostatectomie radicale comme étant insignifiantes, et la biopsie transrectale diagnostique comporte de graves risques, y compris le choc septique. En l'absence de marqueurs biologiques pour le dépistage d'une maladie grave, potentiellement fatale, le National Screening Committee du Royaume-Uni et le Preventive Services Task Force des États-Unis ne recommandent pas le dépistage par dosage de l'APS⁹.

Quel est alors le rôle des pathologistes et des médecins de laboratoire dans ces controverses en matière de dépistage? Nous devons d'abord nous rappeler, ainsi que nos collègues cliniciens et le public, que le dépistage vise les personnes asymptomatiques et que les tests de dépistage ne sont pas nécessairement des outils diagnostiques judicieux. Nous devons continuer à étudier l'évolution naturelle des lésions précancéreuses et les marqueurs biologiques qui y sont associés. En particulier, nous devons identifier des marqueurs biologiques génétiques qui prédiront le caractère agressif des tumeurs malignes. Enfin, nous devons être très précis dans notre emploi de la terminologie et nous assurer que les étudiants et les résidents en comprennent l'importance. Si les pathologistes ne protègent pas la nomenclature et la terminologie, qui le fera?

J. Godfrey Heathcote, M.A., M.B. B.Chir., Ph.D., FRCPC
Rédacteur en chef

[Note du rédacteur : Un numéro ultérieur du Journal inclura des articles sur le dosage de l'APS et le diagnostic morphologique du cancer de la prostate.]

Références

1. Canadian Task Force on Preventive Health Care. Recommendations on screening for cervical cancer. CMAJ 2013;185:35–45.
2. McCartney M. Why it is wrong to promote cervical screening in under 25s. BMJ 2011;343:673.
3. Welch HG. Overdiagnosis and mammography screening. BMJ 2009;339:182–3.
4. Kalager M, Adami H-O, Bretthauer M, Tamimi RM. Overdiagnosis of invasive breast cancer due to mammography screening: results from the Norwegian screening program. Ann Intern Med 2012;156:491–9.
5. Jorgensen KJ, Keen JD, Gotzsche PC. Is mammographic screening justifiable considering its substantial overdiagnosis rate and minor effect on mortality? Radiology 2011;260:621–7.
6. Esserman LJ, Thompson IM Jr, Reid B. Overdiagnosis and overtreatment in cancer. An opportunity for improvement. JAMA 2013;310:797–8.
7. Sandblom G, Varenhorst E, Rosell J, et al. Randomised prostate cancer screening trial: 20 year follow-up. BMJ 2011;342:908.
8. Parker C. Treating prostate cancer. BMJ 2012;345:9.
9. Wilt TJ, Ahmed HU. Prostate cancer screening and the management of clinically localized disease. BMJ 2013;346:28–33.

Pathologists' Assistants: Defining a Standard in a Uniquely Diverse Population of Professionals

The Pathologists' Assistant (PA) Section of the Canadian Association of Pathologists (CAP-ACP) has been working tirelessly toward defining a standard for Canadian pathologists' assistants since 2006. The PA Section's ultimate goal is to seek certification for Canadian PAs, and towards that end, the PA Section is pleased to announce that a Canadian standard for PAs has been defined and will be implemented July 2014. Although this standard is not certification, it will be a reference point for PAs, employers, pathologists, and other invested parties to define a Canadian pathologists' assistant.

In 2010, the PA Section and the CAP-ACP accepted a set of certification criteria that will be used for certification purposes in the future. These criteria will gradually phase out "grandparenting" and "on the job training (OJT) routes" to becoming a Canadian PA, such that eventually all new PAs must obtain a pathologists' assistant master's degree.

The future to becoming a Canadian PA is, undoubtedly, a pathologists' assistant master's degree, as it is for other North American PAs. However, there are currently not enough PA master's program graduates to meet the needs of Canadian employers. There are also many experienced Canadian PAs who do not have a pathologists' assistant master's degree. PAs became a profession in Canada prior to the mid-1970s, and the oldest Canadian master's degree program graduated its first class in 2005. These experienced Canadian PAs are the pioneers of the profession in Canada; they have trained and oriented countless pathology residents, have participated in innumerable committees and groups to improve quality assurance in the pathology laboratory, and have not only trained the modern PA but have also written and overseen Canada's first PA master's degree programs.

The issues facing Canadian employers were these: How do you define a pathologists' assistant's experience? How do you know that an individual can do the work of a PA? Specifically, how do you know an individual has appropriate experience that ensures that he or she can gross all levels of surgical

specimens and perform complete autopsies? There are employees with varied job titles in Canada who perform some level of gross dissection and/or autopsy work, but many of these individuals are not working at a PA level. They may perform some aspect of a PA's duties, but not all.

The answer is this: In July 2014, the certification criteria ratified by the Pathologists' Assistants Section and approved by the CAP-ACP will be implemented as a requirement to new members of the CAP-ACP Pathologists' Assistant Section, and will be applied to existing members in the near future. These criteria do require all non-grandparented PAs to write an examination, and all grandparented and OJT PAs to provide specific documentation regarding their experience with a specific list of specimen and autopsy types, to be approved by the head pathologist at that individual's worksite for whom they have performed these tasks. This experience is outlined in the application form, which will be posted on the PA Section website by March 2014. Further instructions regarding the application process for new members was also provided at that time. **The first examination will be written at the 2014 PA Section Conference in Toronto.**

The criteria, adapted from the CAP-ACP PA Section bylaws (posted at <http://www.cap-acp.org/pathologistsAssistants.cfm>), are these:

1. Applicants requesting to be grandparented to become certified Canadian PAs require 5 years (FTE) of experience (prior to the 2014 AGM) – proven by documentation provided in writing by their Human Resources Department. The deadline for these applicants to apply will be the end of the 2016 AGM (this to be revisited, revised or confirmed in 2014). Master's degree PA program graduates who graduate prior to the 2014 AGM will qualify for grandparenting, as will AAPA/ASCP members who become certified prior to the 2014 AGM.
2. As of the 2014 AGM, OJT applicants will be required to

successfully write the Canadian PA membership application (awaiting an examination name; hereafter referred to as *the examination*), have a minimum amount of education (as outlined below), and have 2 years of PA-specific experience, obtained in Canada, in order to qualify for membership in the PA Section of the CAP-ACP.

- Minimum education guidelines:
 - a. Post-2014 AGM: Grandparenting ends. A minimum educational requirement of a registered technologist diploma (CSMLS eligible) will be required for OJT applicants.
 - b. Post-2016 AGM: A minimum educational requirement of a BSc will be required for OJT applicants.
 - c. Post-2021 AGM: OJT individuals will no longer be accepted for membership.
- 3. International graduates: All international graduates who have the required 5 full-time years of experience prior to the 2014 AGM will qualify for grandparenting without writing the examination, as with all other grandparented individuals.
 - For other international graduates:
 - a. International Laboratory Technologist Program graduates who qualify for CSMLS membership and who have 2 years of PA-specific experience obtained within Canada will qualify to write the examination for as long as Canadian MLT graduates with at least the minimum amount of experience qualify to write the examination (2016).
 - b. International Medical School Graduates with 2 years of PA-specific experience, obtained within Canada, will qualify to write the examination for as long as Canadian BSc graduates with at least the minimum amount of experience qualify to write the examination (2021).
- 4. Canadian PA master's degree program graduates who graduate following the 2014 AGM: Master's PA Program graduates who graduate following the 2014 AGM will qualify to write the examination and will not need any

additional experience beyond that obtained within their master's degree program.

5. Following the 2014 AGM, American Society for Clinical Pathology (ASCP-BOC) certified PAs will qualify to write the examination.

Subject requirements: A grandparented or OJT applicant may apply for subject membership (to be phased out post-2021, at the close of the OJT route of membership). Subject members will meet the membership requirements as described above in one of the two following subjects, as described on the PA Section of the CAP-ACP application form:

- a. Complete Surgical Subject PAs – Perform only gross description and dissection of surgical specimens, including large complex cases (L4E level 6, MIS level 5, and equivalent as outlined in the application form)
- b. Complete Autopsy Subject PAs – Perform only complete autopsies (forensic and/or clinical [perinatal and/or pediatric and/or adult])

Subject members who write the examination will write only the portion of the examination applicable to their subject.

Certification is the PA Section's ultimate goal with which to define Canadian PAs. Until certification can be implemented, referring to a PA as being a PA Section of the CAP-ACP member will mean that that PA has appropriate Canadian PA experience with which to perform the full duties of a pathologists' assistant in Canada.

Implementation of the ratified certification criteria as membership criteria to the PA Section of the CAP-ACP is defining a standard for Canadian pathologists' assistants, and is a definitive step towards the PA Section's ultimate goal of ensuring a route of certification for Canadian PAs. This step will benefit PAs, employers, pathologists, and, most importantly, Canadian patients.

Danielle Lee, BSc (MLS)
Executive Chair, CAP-ACP Pathologists' Assistant Section
Misericordia Hospital, Edmonton, Alberta

Reporting on Histopathology Specimens from the Cervix and Vagina: Consensus Statements from the Pan-Canadian Cervical Screening Initiative

Submitted by Dr. C. Meg McLachlin on behalf of the Pan-Canadian Cervical Screening Initiative Working Group*

Introduction

Cervical and vaginal histopathology specimens, most often taken during the investigation of abnormal cervical cytology, are reported on using various terminology systems. Squamous abnormalities are generally reported on using terms including dysplasia, cervical intraepithelial neoplasia (CIN) and squamous intraepithelial lesions. These systems are well established but their usage varies and currently there is no Canadian standard for reporting of cervico-vaginal histopathology.

The lack of standardization raises the potential for miscommunication between the pathologist and the clinician. These data are also an important component of cervical screening program performance evaluation. The recent *Cervical Cancer Screening in Canada Monitoring Program Performance 2006–2008* results report,¹ developed under the Pan-Canadian Cervical Cancer Screening Initiative (PCCSI), identified significant gaps in collecting cervical histopathology data throughout most jurisdictions. The development of reporting standards and common data elements is necessary for recording and analyzing complex data sets, for developing quality assurance processes and for improving patient outcomes.

Recently, consensus recommendations on lower anogenital squamous intraepithelial terminology for lesions associated

with human papillomavirus (HPV) were released by the American Society for Colposcopy and Cervical Pathology and the College of American Pathologists (the LAST project).² The development of these recommendations included involvement from individual Canadian pathologists and colposcopists as well as representation from the Society of Canadian Colposcopists, the Society of Gynecologic Oncologists of Canada and the Society of Obstetricians and Gynaecologists of Canada. The recommendations outline a terminology system for squamous lesions of the cervix, vagina, vulva, penis, perianus and anus, as well as recommendations for superficially invasive squamous carcinomas and the use of biomarkers. The LAST project does not address report content, negative biopsies or glandular lesions.

The Cervical Screening Program of the National Health Service (NHS) in the U.K. recently released the second version of *Histopathology Reporting in Cervical Screening*.³ This updated document provides advice on terminology and diagnostic criteria, including squamous, glandular and benign mimics.

These two documents, as well as the demonstrated gap in data collection, led to the development of a Canadian consensus process for a comprehensive reporting system for histopathology specimens from the cervix and vagina. The

*Pan-Canadian Cervical Screening Initiative Working Group: Dr. Meg McLachlin, Chair (London, Ontario); Dr. Terry Colgan (Toronto, Ontario); Dr. Maire Duggan (Calgary, Alberta); Susan Fekete (Canadian Partnership Against Cancer); Dr. Verna Mai (Canadian Partnership Against Cancer); Dr. Joan Murphy (Toronto, Ontario).

This article has been reprinted in part from the Canadian Partnership Against Cancer. The full report, "Pan-Canadian Cervical Screening Initiative Reporting on Histopathology Specimens from the Cervix and Vagina – Consensus Statements: May 2013," is available in English and French at www.cccincanada.ca.

goal of the Canadian project was to standardize report content and terminology. The proposed system should facilitate patient care through consistent reporting formats and terminology; enable structured reporting; support national, provincial and territorial data collection; and support program monitoring and evaluation.

Process

With the goal of establishing reporting standards for cervico-vaginal histopathology, a working group, led by PCCSI, was formed in the fall of 2012 (see Appendix C [in the full report] for working group membership). The working group used the LAST terminology and the NHS's *Histopathology Reporting in Cervical Screening* as foundational references for the development of the first draft of the Canadian-adapted cervico-vaginal histopathology consensus statements. As well, a survey of reporting practices by Canadian pathologists provided a baseline for terminology systems currently in place.

The initial draft of the Canadian-adapted statements developed by the working group (in October 2012) was circulated to a group of key stakeholder pathologists. These pathologists were identified by representatives from provincial and territorial cancer programs and by national professional organizations such as the Canadian Association of Pathologists (CAP). The statements were circulated via an online consensus platform, which displayed the draft statements and relevant references (results of this review are presented in Appendix A). Pathologists were asked to indicate their level of agreement with each statement on a scale from one to six and were able to add comments. In a parallel process, colposcopists from across Canada reviewed a standard set of colposcopy data elements that support both clinical service needs and monitoring of colposcopy and cervical program quality indicators (publication pending). The feedback and level of consensus from this round of review was compiled and presented at a two-day workshop in November 2012, hosted by PCCSI. The workshop brought together the key stakeholder pathologists and colposcopists, cervical screening program staff and other key experts (the participant directory is presented in Appendix D). The goals of the workshop were to discuss and agree on standard terminology for pathology results on biopsy

specimens from the cervix and vagina, including cervical cancer, precancer, and benign categories. In addition, colposcopists were asked to help define a standard set of colposcopy data elements that support both clinical service needs and monitoring of colposcopy and cervical program quality indicators.

The workshop featured a focused breakout session to discuss the results of the first round of review of the histopathology statements. A joint discussion involving both pathologists and colposcopists was also held to facilitate further collaboration and input and to inform the next revision of the statements.

Using the feedback from the workshop, the working group revised the histopathology consensus statements. Pathologists were then invited to participate in a second review via the online consensus platform in December 2012 (results of this review are presented in Appendix B). At that point, colposcopists were also invited to indicate their level of consensus with each statement and provide comments. The working group incorporated the December 2012 feedback and comments to produce the final version of the statements presented in this report, titled *Standardized Approach to Reporting on Histopathology Specimens from the Cervix and Vagina*.

This final version of the statements was widely circulated among pathologists and colposcopists in March 2013 with a request for final comments; no further questions or revisions were submitted.

The Executive Committee of the CAP officially endorsed the consensus statements in April 2013.

Next Steps for Action

The consensus statements, *Standardized Approach to Reporting on Histopathology Specimens from the Cervix and Vagina*, presented in this report, are intended to stimulate discussion and inform practice.

Provinces and territories may wish to modify or enhance these recommendations to serve the needs in their jurisdictions. It is recognized that there are areas of contention that will require further discussion. Specifically, the inclusion of CIN terminology for high-grade lesions, especially in young women, should be influenced by clinical need. The forthcoming guidelines on colposcopic management from the

Canadian Society of Colposcopists will likely provide guidance. It is also recognized that the “Indeterminate” category attempts to standardize a category that is inherently variable. Unless stringent criteria for further sectioning, the use of biomarkers and second opinions are followed, this category could become a catch-all. Similar to the “Atypical Squamous Cell of Undetermined Significance” category in cytology reporting systems, the use of the “Indeterminate” category should be monitored.

Finally, a comprehensive reporting system requires that the histopathological criteria for the diagnostic categories be delineated. As well, the increasing use of biomarkers to support diagnosis needs to be addressed and appropriate use described. To this end, the CAP is bringing together a steering committee to provide advice in these areas.

Standardized Approach to Reporting on Histopathology Specimens from the Cervix and Vagina

General Statements

1. A standardized approach to report content and terminology for histopathology specimens from the cervix and vagina has the potential to improve communication and the quality of patient care.
2. This reporting system should contain, at a minimum, data elements including type of specimen and diagnosis. The use of a “synoptic” format with distinct data fields could aid in data collection but is optional.
3. If interpretation is limited by sampling, fixation and/or preparation this should be stated with a description of the limitation. If there is no limitation then the adequacy of the specimen for interpretation is understood.
4. A statement regarding the presence or absence of transformation zone as determined by the presence of metaplastic squamous epithelium or underlying endocervical glands is optional.

Reporting System

Negative Specimens

5. Specimens that are Negative for **Intraepithelial Lesion and Malignancy** should be reported using a clear and unambiguous statement. The term “Intraepithelial Lesion” is inclusive of both squamous and glandular lesions. The addition of comments regarding specific benign conditions is optional.

Squamous Lesions

6. Specimens that are positive for squamous intraepithelial lesions should be reported using a 2-tiered nomenclature. The recommended terminology is **Low Grade Squamous Intraepithelial Lesion (LSIL)** and **High Grade Squamous Intraepithelial Lesion (HSIL)**.
7. The SIL terminology may be further classified by the applicable **Intraepithelial Neoplasia** sub-categorization – for example, HSIL (CIN 2). The addition of sub-classification should be based on clinical decision/management pathways.
8. Specimens that contain an area of squamous intra-epithelial lesion which cannot be graded as either low or high due to limited sampling, substandard fixation and processing, and/or obscuring factors should be reported as **Squamous Intraepithelial Lesion, Ungraded**. There should be a comment regarding the nature of the uncertainty. This conclusion should only be reached after appropriate work up that may include further levels, consultation and biomarkers such as p16.

Glandular Lesions

9. Specimens that are positive for endocervical glandular preinvasive lesions should be reported using the term **Adenocarcinoma In Situ (AIS)**.
10. Specimens with lesser degrees of glandular atypia are not uniformly recognized and classified and reporting is not recommended (see also statement #11 Indeterminate for AIS).

Indeterminate Lesions

11. Specimens which contain some features of HSIL, AIS or malignancy but for which definitive conclusions cannot be reached due to limited sampling, substandard fixation and processing, and/or obscuring factors should be reported as **Indeterminate for – HSIL or AIS or Malignancy**. There should be a comment regarding the nature of the uncertainty. This conclusion should only be reached after appropriate work up that may include further levels, consultation and biomarkers such as p16.

Excisional Specimens

12. The reporting of single excisional biopsies (LEEP, Cone) with intraepithelial lesions should include a statement

regarding the involvement of margins including an indication of which margin is involved, if possible – for example, endocervical, ectocervical, radial (deep).

13. Single excisional biopsies (LEEP, Cone) that are positive for malignancy should contain, where possible:
 - a. Type of malignancy
 - b. Depth of invasion
 - c. Horizontal spread
 - d. Presence or absence of lymph-vascular space invasion
 - e. Involvement of margins

Superficially Invasive Squamous Cell Carcinoma

14. The term **Superficially Invasive Squamous Cell Carcinoma (SISCCA)** is recommended for minimally invasive SCC of the cervix that has been completely excised and is potentially amenable to conservative surgical therapy. Lymph-vascular invasion and pattern of invasion are not part of the definition of SISCCA.
15. SISCCA of the cervix (FIGO 1ai) is defined as an invasive squamous cell carcinoma that:
 - a. Is not a grossly visible lesion AND
 - b. Has an invasive depth of 3mm or less from the basement membrane of the point of origin AND
 - c. Has a horizontal spread of 7 mm or less in maximal extent AND
 - d. Has been completely excised
16. No recommendation is offered for early invasive squamous cell carcinoma of the vagina.
17. For cases of invasive squamous cell carcinoma with positive biopsy/resection margins, the pathology report should state whether:
 - a. The examined invasive tumor exceeds the dimensions for a SISCCA OR
 - b. The examined invasive tumor component is less than or equal to the dimensions for a SISCCA and conclude that the tumor is “At least a superficially invasive squamous cell carcinoma.”

18. In cases of SISCCA, the following parameters should be included in the pathology report:
 - a. The presence or absence of lymph-vascular space invasion
 - b. The presence, number, and size of independent multifocal carcinomas (after excluding the possibility of a single carcinoma)

Acknowledgement

Production of this report has been made possible through a financial contribution from Health Canada, through the Canadian Partnership Against Cancer.

The views expressed herein represent the views of Canadian Partnership Against Cancer.

References

1. Canadian Partnership Against Cancer. Cervical cancer screening in Canada monitoring program performance 2006–2008. Toronto: The Partnership; 2011; http://www.cancerview.ca/idc/groups/public/documents/webcontent/ccic_cervical_cs_report.pdf.
2. Darragh TM, Colgan TJ, Cox J, et al. The Lower Anogenital Squamous Terminology Standardization project for HPV-associated lesions: background and consensus recommendations from the College of American Pathologists and the American Society for Colposcopy and Cervical Pathology. *J Low Genit Tract Dis* 2012;16(3):205–42; http://journals.lww.com/jlgt/Fulltext/2012/07000/The_Lower_Anogenital_Squamous_Terminology.6.aspx#.
3. National Health Services Cancer Screening Programmes. Histopathological reporting in cervical screening – an integrated approach. 2nd ed. HSCSP Publication No. 10; 2012; <http://www.cancerscreening.nhs.uk/cervical/publications/cc-04.html>.

Orbital Osteitis in Clinically Unsuspected Syphilis

J. Godfrey Heathcote, MB, PhD, FRCPC, Ridas Juskevicius, MD, Alejandra A. Valenzuela, MD

ABSTRACT

A 60-year-old man presented with pain and swelling in the left temple overlying an osteolytic lesion in the lateral orbital wall. Biopsy revealed a fibro-inflammatory lesion in which spirochetes were demonstrated. The patient died shortly afterwards without other evidence of syphilis at autopsy. Although bony lesions are considered characteristic of tertiary syphilis, the combination of tender scalp swellings overlying lytic lesions in the skull bones has been described in secondary syphilis. The difficulty of assigning a stage to syphilitic infection in the absence of a clinical history and serological investigations is discussed.

RÉSUMÉ

Cas d'un homme de 60 ans présentant de la douleur et de l'enflure à la tempe gauche recouvrant une lésion ostéolytique au niveau de la paroi orbitaire latérale. La biopsie a mis en évidence une lésion fibro inflammatoire avec présence de spirochètes. Le patient est décédé peu de temps après et l'autopsie n'a révélé aucun autre signe de syphilis. Bien que les lésions osseuses soient considérées comme des caractéristiques de la syphilis tertiaire, la combinaison d'enflures du cuir chevelu sur les lésions lytiques dans les os du crâne a été décrite dans la syphilis secondaire. La difficulté à assigner un stade à l'infection syphilitique en l'absence d'antécédents cliniques et d'investigations sérologiques est abordée dans cet article.

According to the Public Health Agency of Canada, the reported rate of infectious syphilis in Canada has increased by 782.1% since 2000.¹ In 2009, the last year for which the agency has published figures, there were 1,683 new cases of infectious syphilis reported in Canada with a rate of 5.0 per 100,000 of population. Despite this, and the traditional importance of syphilis in the teaching of pathology, pathologists continue to be surprised and intrigued when the diagnosis is confirmed in a tissue sample. In this article we report a case of unexpected syphilis manifesting as a malignant tumour.

Clinical History

A 60-year-old man presented with a 2-week history of pain in the left temple associated with reduced vision in the left eye. On examination, visual acuity was 20/20 in the right eye and 20/200 in the left; the right fundus was normal but on the left there was disc edema, as well as nerve fibre layer infarcts and hemorrhages. An inferior visual field defect was noted. Although there were no complaints of scalp tenderness or jaw claudication, he was started on prednisone (50 mg/d) with a slight, subjective improvement in vision.

J. Godfrey Heathcote, MB, PhD, FRCPC, and Ridas Juskevicius, MD, are members of the Department of Pathology, and Dr. Heathcote is also a member of the Department of Ophthalmology and Visual Sciences, at Dalhousie University and QEII Health Sciences Centre, in Halifax, Nova Scotia. Alejandra A. Valenzuela, MD, is a member of the Department of Ophthalmology at Tulane University School of Medicine, in New Orleans, Louisiana. Correspondence may be directed to godfrey.heathcote@dal.ca.

This article has been peer reviewed.

Competing interests: Dr. Heathcote is editor-in-chief of the *Canadian Journal of Pathology* but played no part in editorial decisions about this article.

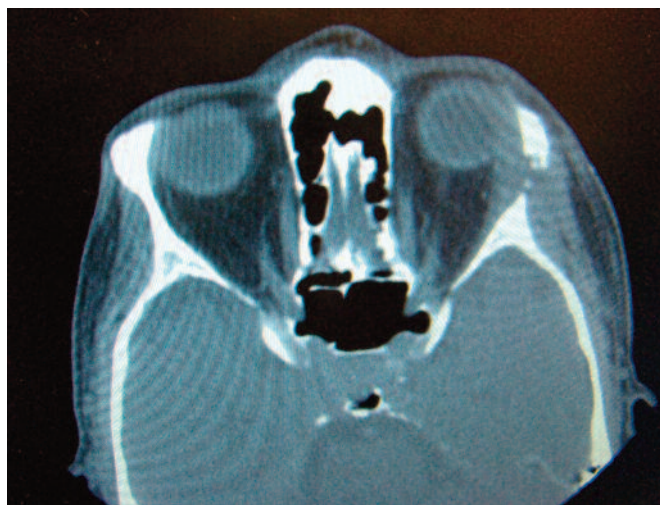

Figure 1. CT scan showing fullness of left temporal fossa with erosion of lateral orbital bone by soft tissue mass.

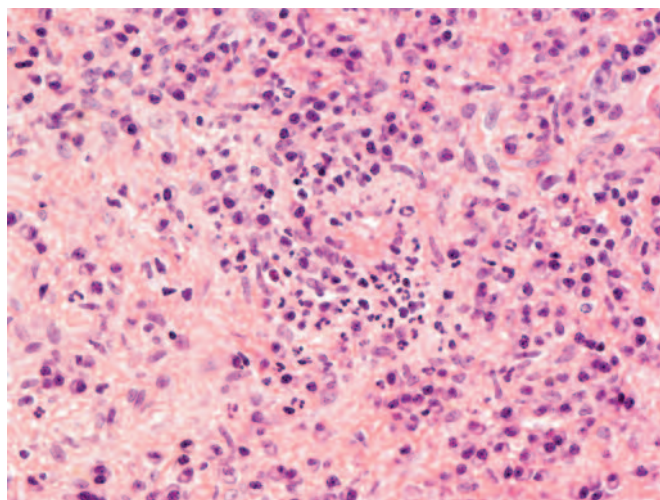


Figure 3. Numerous plasma cells, together with histiocytes, and neutrophils. (Hematoxylin and eosin)

However, the erythrocyte sedimentation rate was normal, and a temporal artery biopsy was reported as negative. He was referred to a general physician who could find no evidence of significant cardiovascular or other disease. Computed tomography (CT) scans of the thorax, abdomen, and pelvis were normal. However, a CT scan of the head revealed an osteolytic lesion (1.4 cm) in the left lateral orbital wall just postero-inferior to the frontozygomatic suture (Figure 1). In addition there was a soft tissue mass extending from the temporal fossa to the lateral rectus muscle and a presumptive diagnosis of a malignant tumour,

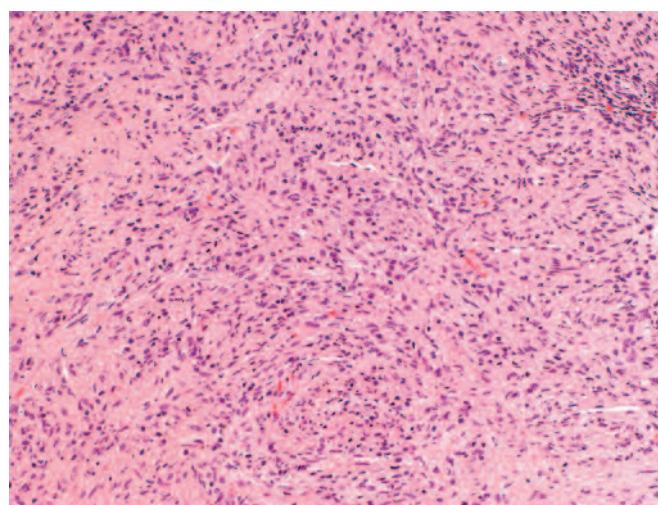


Figure 2. Fibro-inflammatory mass containing lymphocytes, plasma cells, histiocytes, and neutrophils. (Hematoxylin and eosin)

likely a metastasis, was made.

When seen by an orbital surgeon, his findings were essentially unchanged, apart from the presence of an afferent pupillary defect and a diminution in colour vision in the left eye. There was a slight fullness in the left temporal region but no proptosis or diplopia and ocular motility was full. The orbital surgeon could not explain the decrease in optic nerve function given that the lesion was not close to the nerve. A lateral orbitotomy was undertaken and the tumour debulked. It consisted of sclerotic tissue that was eroding the greater wing of the sphenoid and occupying the lateral orbit. Following the operation, visual acuity decreased to hand movements and the optic disc remained swollen. While the orbital lesion was still under evaluation, the patient returned to his home in a distant province, where he died unexpectedly. A history of homosexual activity was revealed and at autopsy there was pronounced pulmonary edema, an abscess in the right adrenal gland (but without organisms) and malakoplakia of the liver. There was no indication of syphilis; both the heart valves and aorta were unremarkable.

Histopathology

Several small pieces of yellow-tan and grey soft tissue ranging up to 10 mm in maximal dimension were submitted for histopathological examination. Sections revealed a fibro-inflammatory mass (Figure 2) with areas of healing fat necrosis, fragments of bone and involvement of skeletal

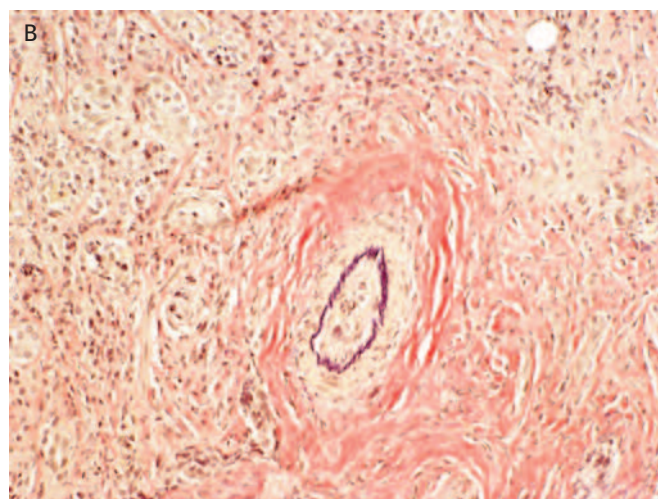
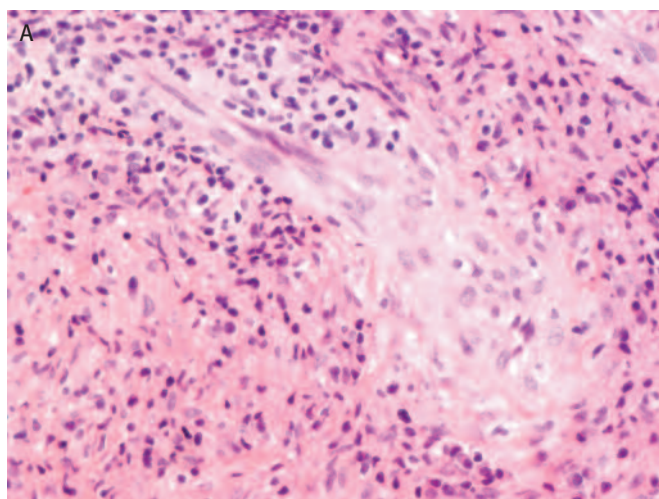


Figure 4. Vascular changes within the fibro-inflammatory mass: A, endothelial cell hypertrophy; B, occlusive endarteritis. (A, hematoxylin and eosin; B, elastic stain)

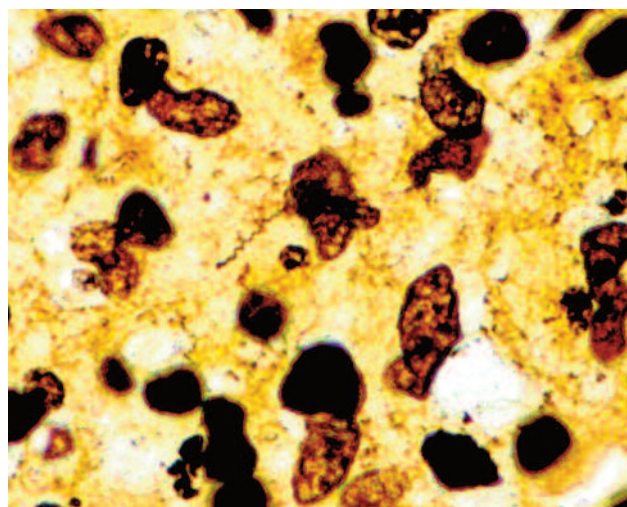


Figure 5. Spirochetes within the infiltrate. (Steiner stain)

muscle and lacrimal gland. The inflammatory infiltrate was of variable intensity and plasma cells formed a major component (Figure 3). Numerous histiocytes were present, some grouped around neutrophilic microabscesses, although discrete granulomata were not seen. Lymphocytes were neither atypical nor particularly numerous. Some large vessels were occluded and partially destroyed by the inflammation and smaller vessels had swollen endothelial cells (Figure 4). Immunoperoxidase studies confirmed that CD3+ T-cells outnumbered CD20+ B-cells. The spindle cells in the background showed minimal expression of α -actin but did not express CD34, ALK-1, S100 protein, CK7 or desmin.

Histochemical stains for bacteria, fungi and acid-fast bacilli were negative but a Steiner silver stain demonstrated numerous spirochetes consistent with *Treponema pallidum* (Figure 5).

Discussion

With no clinical history or laboratory data to suggest syphilis, the pathologist's first impression was of a mesenchymal neoplasm with an inflammatory component, such as inflammatory myofibroblastic tumour. However, the histopathological features of plasmacytic infiltration, obliterative endarteritis, and endothelial swelling in small vessels led to consideration of syphilis as a possible diagnosis. Given the many gaps in the clinical history and laboratory investigations, a definitive explanation of his illness is difficult. Nevertheless, our basic understanding of syphilis allows two possible explanations of his orbital osteitis.

Acquired syphilis evolves through three stages. In primary syphilis, a painless ulcer develops on the external genitalia after an incubation period of 3–6 weeks. With or without treatment, this heals but, if untreated, about 75% of cases will progress to secondary syphilis 1–2 months after the chancre has appeared. Secondary syphilis is characterized by a maculo-papular cutaneous rash, often involving the palms and soles, together with erosions on mucous membranes. There may also be systemic signs and symptoms, such as lymphadenopathy, alopecia, fever and arthralgia. Numerous organisms can be demonstrated in the lesions of primary and secondary (early)

syphilis. When the secondary lesions have resolved, the disease enters a latent phase. Approximately two-thirds of patients remain asymptomatic but the remaining one third develops the lesions of tertiary syphilis after an interval of months to years. Most tertiary stage disease involves the cardiovascular system but in benign tertiary syphilis lesions frequently appear in the bone, skin and testes. These lesions are the gummata, which are thought to represent a delayed hypersensitivity reaction to *T. pallidum*, and which are characterised by endarteritis with coagulative necrosis, surrounded by a fibrohistiocytic reaction and a plasma cell-rich infiltrate. Treponemes are difficult to demonstrate in gummata. Given the location of our patient's lesion in the frontozygomatic bone, it would seem reasonable to conclude that this is a gumma of tertiary syphilis. Nevertheless, the histopathology is somewhat different from a classic gumma, with minimal necrosis and numerous spirochetes present.

In contrast to tertiary syphilis, bony lesions are uncommon in early syphilis. However, it is recognized that when treponemes enter the bloodstream in early syphilis, they travel to the periosteum, the Haversian canals and the marrow space, where they may produce the characteristic manifestations of periostitis, osteitis and osteomyelitis. In a radiographic study from 1952 of 80 patients with secondary syphilis, Thompson and Preston identified seven with osteolytic lesions of the skull, four of whom had headache as a major symptom. Destructive osteitis was more common than periostitis or osteomyelitis.² A more recent clinical study has suggested that the prevalence of bone lesions in secondary syphilis is much less, with only two cases of periostitis in 854 patients and no cases of destructive osteitis.³ Women made up 75% of patients in the earlier series, whereas they constituted <10% of patients in the later clinical study.

Several reports over the past two decades have described patients with a clinical picture similar to that of our patient: recent onset of headache, with a tender fluctuant swelling in the scalp overlying lytic lesions in the underlying frontal and parietal bones.^{4,5} The bony and soft tissue lesions, as well as the headaches, resolved with appropriate penicillin or ceftriaxone therapy. Some of these patients had the maculo-papular eruption characteristic of secondary syphilis.^{6,7} Kang et al. described an unusual patient in which a skull lesion was the initial and sole manifestation of syphilis.⁸ The 20-year-old man presented with intermittent headaches and a small tender

swelling of the right parietal region 7 months after a sexual encounter with a prostitute. CT revealed a 1.7 cm full-thickness defect in the underlying bone, which biopsy showed to be a fibrous proliferation with a lymphoplasmacytic infiltrate; spirochetes were demonstrable with a silver stain. Samarkos et al. reported a similar case with periostitis of the skull but no osteolytic defect.⁹

Lack of clinical history and relevant laboratory data make it impossible to assign a definite stage to our patient's disease: the excised lesion has pathological features that resemble the gumma of tertiary syphilis but is also similar to bony lesions that have been described in well documented secondary syphilis.⁶⁻⁹ The apparently rapid onset of the lesion, and the lack of cardiovascular syphilitic lesions at autopsy, would tend to support secondary syphilis. There may also be an element of early neurosyphilis in our patient. Although there were no obvious structural changes of the optic nerve on CT, disc oedema and nerve fibre layer changes in the fundus, with an afferent pupillary defect and a visual field defect, could be the result of an early syphilitic optic perineuritis.¹⁰

Acknowledgement

This case was presented at the Annual Meeting of the Eastern Ophthalmic Pathology Society, in Miami, Florida, on October 26, 2012.

References

1. Public Health Agency of Canada. Home page. Ottawa: Author; www.phac-aspc.gc.ca/.
2. Thompson RG, Preston RH. Lesions of the skull in secondary syphilis. *Am J Syphil Gonorrhea Vener Dis* 1952;36:332-41.
3. Mindel A, Tovey SJ, Timmins DJ, Williams P. Primary and secondary syphilis, 20 years' experience. 2. Clinical features. *Genitourin Med* 1989;65:1-3.
4. Etienne M, Bencteux P, Gueit I, et al. Déjà vu in the catacombs: skull syphilitic osteitis. *Lancet Infect Dis* 2008;8:455.
5. Toby M, Larbalestier N, Kulasegaram R, et al. Calvarial syphilis in an HIV-positive man. *Int J STD AIDS* 2012;23:365-6.
6. Chung K-Y, Yoon J, Heo JH, et al. Osteitis of the skull in secondary syphilis. *J Am Acad Dermatol* 1994;30:793-4.
7. Egan KM, Walters MC. Osseous and meningeal involvement in secondary syphilis. *Dermatol Online J* 2012;18:1-2.
8. Kang SH, Park SW, Kwon KY, Hong WJ. A solitary skull lesion of syphilitic osteomyelitis. *J Korean Neurosurg Soc* 2010;48:85-7.
9. Samarkos M, Giannopoulou C, Karantoni E, et al. Syphilitic periostitis of the skull and ribs in a HIV positive patient. *Sex Transm Infect* 2011;87:44-5.
10. Parker SE, Pula JH. Neurosyphilis presenting as asymptomatic optic perineuritis. *Case Rep Ophthalmol Med* 2012;Article ID 621872.

Case Report: Cholesterol Granuloma in the Anterior Mediastinum

Abbas Akhdar, MD, Marco Sirois, MD, FRCSC, Eric Turcotte, MD, FRCPC, Sameh Geha, MD

ABSTRACT

Cholesterol granulomas represent a foreign body granulomatous reaction to cholesterol crystals and occur in a variety of locations, mainly the middle ear. They have also been described in the lung and in lymph nodes. Only a few cases have been reported in the mediastinum. We describe such a case where a radiologically suspicious nodule discovered in the anterior mediastinum turned out to be a cholesterol granuloma.

RÉSUMÉ

Les granulomes à cholestérol sont la manifestation d'une réaction granulomateuse à corps étranger aux cristaux de cholestérol et surviennent dans divers sièges, principalement dans l'oreille moyenne. Ils ont également été observés dans les poumons et les ganglions. Quelques cas seulement ont été rapportés dans le médiastin. Le présent article présente un tel cas où un nodule suspect à la radiologie qui a été découvert dans le médiastin antérieur s'est révélé être un granulome à cholestérol.

Cholesterol granuloma is a rare entity that represents a foreign body granulomatous response to the precipitation of cholesterol crystals thought to be derived from cell breakdown.^{1,2} Other etiological hypotheses include cholesterol emboli, hypercholesterolemia, inflammation, trauma, and impaired lymphatic drainage.^{1,3} However, the exact pathophysiological process underlying cholesterol granuloma formation is still unclear. They are benign but expansile lesions.¹⁻³ On histological examination, cholesterol crystals are surrounded by foreign body giant cells and by a chronic fibroinflammatory reaction. They occur in a wide variety of locations, most often in the temporal bone. Other sites include the mandible, orbital bones, liver, kidney, lung, peritoneum, lymph nodes, and breast.⁴ To date, only four

cases of mediastinal cholesterol granulomas have been published.^{2,5-7} Three of these cases occurred in the anterior mediastinum, of which two were associated with a multilocular thymic cyst and a thymic seminoma with prominent cystic changes, while the other was an incidental finding with no associated mediastinal lesion.⁵ The fourth case occurred in the superior mediastinum and was also an incidental finding during heart valve surgery.

Case Report

A 51-year-old man under investigation for progressive mural thickening of the second part of the duodenum underwent a positron emission tomography (PET) scan. The latter showed multiple hypermetabolic lymph nodes

Abbas Akhdar, MD, and Sameh Geha, MD, are members of the Pathology Department; Marco Sirois, MD, FRCSC, is a member of the Division of Thoracic Surgery; and Eric Turcotte, MD, FRCPC, is a member of the Nuclear Medicine and Radiobiology Department, at Centre hospitalier de l'université de Sherbrooke (CHUS), in Sherbrooke, Québec. Sameh Geha is also a member of the Clinical Research Centre Etienne-Lebel funded by the FRSQ (Fonds de la recherche en santé du Québec), in Sherbrooke, Québec. Correspondence may be directed to Sameh.geha@usherbrooke.ca.

This article was peer reviewed.

Competing interests: None declared

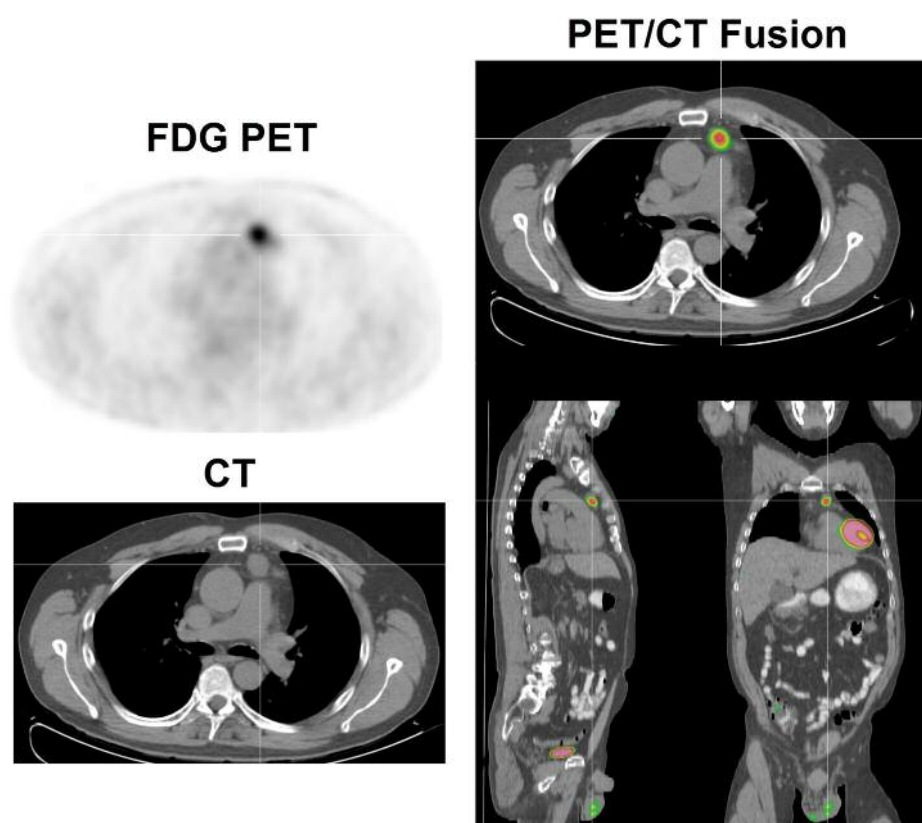


Figure 1. Positron emission and computed tomography images, with crosshair over the mediastinal cholesterol granuloma.

mainly in the anterior mediastinum. The largest one measured 2.2 cm and had a maximal standard uptake value (SUV) of 5.9 (Figure 1). The scan also showed a circumferential thickening of the duodenal wall, as well as a local heterogeneous hypermetabolism.

The patient had a history of recurrent acute pancreatitis and showed signs of early chronic pancreatitis. His medical history also included dyslipidemia, hepatic steatosis, alcohol abuse, and high blood pressure. Multiple duodenal biopsies carried out at different times showed an active duodenitis. A biopsy of the mediastinal lesions was performed through a left anterior mediastinotomy (Chamberlain procedure) to rule out a lymphoma or other neoplastic process. On gross examination, two fragments of tissue showed a gritty, glistening, and orange-red cut surface (Figure 2).

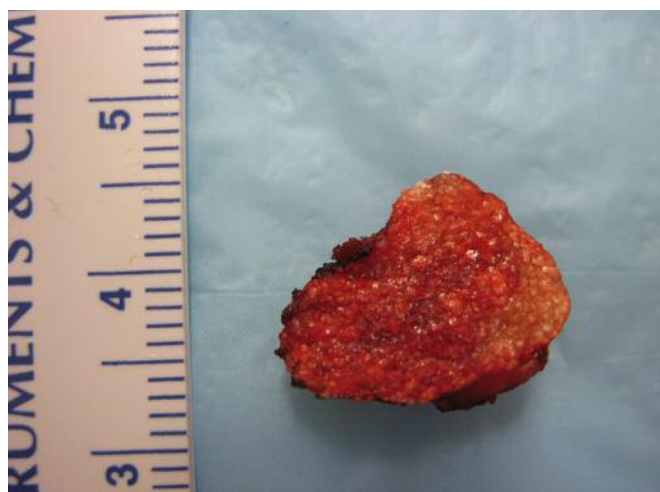

Figure 2. Gross appearance of the cholesterol granuloma with a glistening and gritty orange-red cut surface.

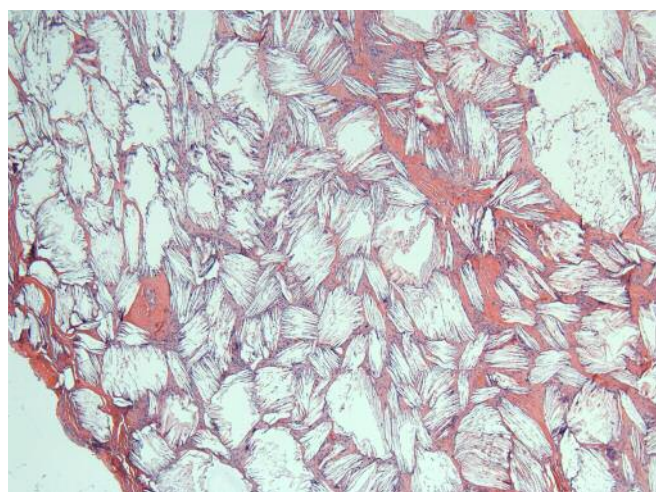


Figure 3. Microscopic appearance of the cholesterol granuloma. (Hematoxylin and eosin)

Histopathological examination revealed a cholesterol granuloma with cholesterol crystals surrounded by a foreign body inflammatory reaction with multinucleated giant cells and histiocytes (Figure 3). In addition, there was intervening fibrosis as well as a mild lymphocytic reaction. No lymph node tissue was identified.

Discussion

Described only in rare case reports,^{2,5-7} mediastinal cholesterol granulomas are benign expansile lesions of uncertain etiology. They can sometimes raise a clinical or radiological suspicion of neoplasia,^{2,5,8} as was the case in our patient. Of interest in our case is the finding that a cholesterol granuloma may also be hypermetabolic on PET scan, demonstrating the intense inflammatory response to foreign material. This was also described in one of the previous cases of mediastinal cholesterol granulomas where the isolated lesion was said to show a maximal SUV of 3.3.⁵

References

1. Tringali S, Linthicum FH. Temporal bone histopathology case of the month: cholesterol granuloma of the petrous Apex. *Otol Neurotol* 2010;31:1518-9.
2. Luckraz H, Coulston J, Anzu A. Cholesterol granuloma of the superior mediastinum. *Ann Thorac Surg* 2006;81:1509-10.
3. Lee S-J, Chen SC, Chu SJ, Tsai SH. Huge cholesterol granuloma. *J Trauma* 2009;66:1505.
4. Abu Karaky A, Sawair FA, Baqain ZH, et al. Cholesterol granuloma of the maxillary sinus encountered during floor augmentation procedure: a case report. *Clin Implant Dent Relat Res* 2010;12(3):249-53.
5. Fujimoto K, Takamori S, Yano H. Focal cholesterol granuloma in the anterior mediastinum: [18F]-fluoro-2-deoxy-d-glucose-positron emission tomography and magnetic resonance imaging findings. *J Thoracic Oncol* 2007;2(11):1054-5.
6. Kurosaki Y, Tanaka YO, Itai Y. Thymic seminoma with prominent cystic changes. *Am J Roentgenol* 1996;167:1345-6.
7. Kondo K, Miyoshi T, Sakiyama S. Multilocular thymic cyst associated with Sjogren's syndrome. *Ann Thorac Surg* 2004;72:1367-9.
8. Smith G, Hicks P, Wijesinghe DP, Holme TC. Cholesterol granuloma of the breast presenting as an intracystic papilloma. *Br J Radiol* 1997;70:1178-9.

DISPLAY CLASSIFIED



McGill

www.muhc-cme.mcgill.ca

McGill Cytopathology Review Course May 3 – 6, 2014 • Montréal, Québec, Canada

Course Director: Dr. Manon Auger

For further information contact:

Email: cme@muhc.mcgill.ca

McGill University Health Centre, Continuing Education Office

Tel: (514) 934-8253 • Fax: (514) 934-1779

Cancer Stem Cells: Clinical Relevance

Krysta M. Coyle, BSc, Paola Marcato, PhD

ABSTRACT

Cancer stem cells (CSCs) are among the most tumorigenic cells in cancers. While initially discovered in leukemia, CSCs have become increasingly relevant to solid tumours. Here, the importance of CSCs is discussed in the context of non–small cell lung cancer, breast cancer, colorectal cancers, and acute myeloid leukemia. Relevant literature on the prognostic value of CSCs is reviewed, and the ongoing implication of CSCs in treatment resistance and targeted therapies is emphasized.

RÉSUMÉ

Les cellules souches cancéreuses (CSC) sont parmi les cellules les plus tumorigènes. Bien que les CSC aient été initialement découvertes dans la leucémie, elles sont de plus en plus pertinentes dans les tumeurs solides. Dans le présent article, l'importance des CSC est abordée dans le contexte du cancer du poumon non à petites cellules, du cancer du sein, des cancers colorectaux et de la leucémie myéloïde aiguë. La documentation pertinente sur la valeur pronostique des CSC est passée en revue et l'implication continue des CSC dans la résistance au traitement et les thérapies ciblées est soulignée.

Although scientists had long suspected that a subset of cancer cells existed that was more tumorigenic than other cancer cells, the advent and ever-increasing accuracy of fluorescence-activated cell sorting (FACS) throughout the 1980s allowed researchers to test this hypothesis. In 1994, Lapidot et al. published their landmark paper identifying CD34⁺/CD38[−] cells from a patient with acute myeloid leukemia (AML) as the only cells that were able to regenerate AML in immunocompromised mice.¹ In 1997, after refinement of the non-obese diabetic/severely compromised immunodeficient (NOD/SCID) xenotransplant model, Bonnet et al. demonstrated that primary CD34⁺/CD38[−] cells engrafted in NOD/SCID mice differentiated to form a leukemia similar in phenotype to the primary leukemia.² While these cells were named SCID “leukemia-initiating cells,”

current research suggests that this highly tumorigenic population of cells exists in many cancers – solid tumours and leukemias alike – and this is neither an *in vitro* phenomenon nor restricted to a xenotransplant model.

Prior to this discovery, it was generally accepted that cancer cells were clonal populations with similar replicative potentials. As such, cancer therapies were designed to target the majority of cancer cells. Increasing evidence currently leads us to accept the hierarchical model of cell division, which suggests that a relatively small population of cells – cancer stem cells (CSCs) – exists within most cancers that can repopulate a heterogeneous tumour or leukemia. Recent basic science and clinical research proposes that many of these CSC populations may be resistant to conventional chemotherapy and radiation treatment. Further exploration of CSC biology is essential in

Krysta M. Coyle, BSc, and Paola Marcato, PhD, are members of the Department of Pathology, Dalhousie University, in Halifax, Nova Scotia. Correspondence may be directed to paola.marcato@dal.ca.

This article has been peer reviewed.

Competing interests: None declared

Table 1. Cell-Surface Markers Used in the Identification of Cancer Stem Cells in Non-small Cell Lung Cancer, Breast Cancer, Colorectal Cancers, and Acute Myeloid Leukemia

	Cell surface markers	Function	References
Non-small cell lung cancer	CD133 ⁺	Unknown	Mizugaki et al. ³⁸
	CD44 ⁺	Cell-cell and cell-ECM interactions	Leung et al. ¹⁰³
	ABCG2 ⁺	ATP-binding cassette transporter; may be involved in drug resistance	Li et al. ³⁷
Breast cancer	CD44 ⁺	Cell-cell and cell-ECM interactions	Ginestier et al. ⁷ Al-Hajj et al. ³
	CD24 ^{-/low}	Cell adhesion	
Colorectal cancers	CD133 ⁺	Unknown	Zhang et al. ⁴⁵
	ESA ^{high}	Epithelial-specific cell-cell adhesion	
	CD44 ⁺	Cell-cell and cell-ECM interactions	Dalerba et al. ¹⁰⁴
	CD166 ⁺	Unknown	
	CXCR4 ⁺	Chemokine receptor for stromal-derived factor 1 (SDF-1)	Zhang et al. ⁴⁵
Acute myeloid leukemia	CD34 ⁺	Hematopoietic adhesion molecule	Lapidot et al. ¹ Bonnet and Dick ²
	CD38 ⁻	Cell adhesion and signaling	
	CD47	Inhibits phagocytosis	Majeti et al. ⁴⁶

determining appropriate therapeutic interventions for cancers. Several key features of stem cells can be applied to CSC biology: capacities for self-renewal, proliferation, and multipotency. The hallmark studies in AML, breast cancer and brain tumours demonstrated that a homogeneous population of CSCs was able to differentiate into a heterogeneous cancer similar to the cancer from which it originated.^{1,3,4} Additionally, Al-Hajj et al. were able to generate new tumours in NOD/SCID mice with as few as 200 ESA⁺ (epithelial-specific antigen)/CD44⁺/CD24^{-/low}/Lineage⁻ human breast cancer cells passaged through mice or 1,000 unpassaged cells.³ Similarly, CD133⁺ putative brain CSCs showed increased ability in vitro to form spheres as well as increased proliferation; as few as 100 of these identified cells were able to produce brain tumours in NOD/SCID mice.⁴ Taken together, this research indicates that CSCs represent a stem-like subset of cancer cells which contribute to tumour progression.

While CSCs are stem-like in their phenotype, they rarely generate teratomas or pleomorphic tumours which are characteristic of true stem-cell-generated tumours. Instead, it is hypothesized by some that CSCs arise from less differentiated tissue stem cells. For further discussion on the cancer cell-of-origin, see Visvader and Nguyen et al.^{5,6}

Identifying and Confirming Cancer Stem Cells

CSCs are typically identified by a variety of cell surface markers

(Table 1). The roles of these markers in CSC tumorigenicity remains unclear as their functions are unknown or linked to very general cellular tasks.

Researchers have also used functional enzymatic assays to identify CSCs. One prominent example is the Aldefluor assay (Stem Cell Technologies, Inc.), which detects functional aldehyde dehydrogenase (ALDH) activity. The assay substrate is cleaved by intracellular ALDH enzymes to the fluorescent form. The Aldefluor assay has been used to detect the CSCs of many cancers, including breast, lung, liver, and colorectal cancers.⁷⁻¹⁰

The Aldefluor assay was originally thought to specifically detect ALDH-isoform ALDH1A1 activity; however, it has been demonstrated that ALDH1A3 is a primary contributor to ALDH activity in breast cancer cells and that ALDH1A1 and ALDH1A3 contribute to the activity of melanoma CSCs.¹¹⁻¹³ Isoforms ALDH1A1, ALDH1A2, and ALDH1A3 are retinaldehyde dehydrogenases which are responsible for oxidizing retinaldehyde to retinoic acid, an important molecule in cell growth and differentiation, key processes often dysregulated in cancers.

Once CSCs have been identified via various markers, the gold standard for confirming tumorigenicity is a limiting-dilution xenotransplantation assay in immunocompromised mice. In comparison to the less tumorigenic non-CSCs, many fewer CSCs are required for tumour generation in a new host.

Isolated CSCs and non-CSCs are serially diluted and transplanted into mice, and monitored for tumour growth. It is hypothesized that the lowest dilution at which a tumour is generated represents the relative frequency of CSCs in the isolated population. It is theorized that one CSC is sufficient to regenerate a tumour; however, in most cases, between 100 and 1,000 isolated cells are still required to generate a tumour in the xenotransplantation assay.^{3,14} This suggests that the current markers used to isolate CSCs enrich the CSC population, but are not sufficient to isolate a pure CSC population (briefly discussed by Trumpp et al.).¹⁵

Where xenotransplantation is a less feasible option, the tumorigenicity of the putative CSCs can also be determined by tumour sphere assays that measure the frequency with which the isolated cells form clusters or spheres of cells.

Challenges to the CSC Hypothesis

Stem cell features can be induced in adult fibroblasts by the introduction of several pluripotency factors and it has been suggested that the CSC subset of cancer cells is not a stable population but can be induced by factors present within the tumour.^{16–18} Similar to induced pluripotent stem cells, MCF-10A nontumorigenic mammary epithelial cells have been transformed into stem-like tumorigenic cells via the introduction of reprogramming factors OCT4, SOX2, Klf4, and c-Myc.¹⁹ Additionally, IL-6 is able to induce a CSC phenotype in breast and prostate cell lines, and in cancer cells isolated from primary human breast tumours.²⁰ Furthermore, hypoxia induced a CSC phenotype in glioblastoma xenograft D456MG cells.²¹

The tumour-initiating population of cells (as opposed to the sorted, putative CSCs) may exhibit variable “stem-ness” which could be determined by fluctuating spatial and temporal factors in the microenvironment. This implies that any method of identifying these cells is merely a snapshot of a very dynamic expression profile. The inducibility of CSCs has made their plasticity an emerging question. Rappa and Lorico found that both sorted CD24⁺ (putative CSCs) and CD24⁺ MA-11 breast cancer cells injected into mice gave rise to tumours and expanded into cell populations with heterogeneous CD24 expression. They concluded that CD24 expression is not stable in MA-11 cells and does not indicate tumorigenicity.²² Additional studies provide support to the argument that the

CSC status of tumour cells is dynamic.^{23–25}

Further uncertainty with the CSC hypothesis is due to the often very low number of cells sorted as positive for CSC markers in any particular cancer, which, because of the limitations of the sorting procedure, likely leaves a significant number of putative CSCs in the non-CSC population. Kern and Shibata elegantly explored this inefficiency to question the findings in CSC studies and suggested that decreased tumorigenicity of some sorted cell populations was due to a strong inhibition of grafting.²⁶ Adams and Strasser made a similar argument and suggested that tumour growth might be due to a dominant highly engraftable clone.²⁷ These suggestions are supported by the findings of Kelly et al. who demonstrated that as few as 10 Sca-1⁺/AA4.1^{hi} (putative CSCs) or Sca-1⁺/AA4.1^{lo} (non-CSCs) lymphoma cells from Eμ-*myc* mice injected into congenic, non-irradiated mice generated fatal lymphomas.²⁸ Their findings question the validity of the CSC theory, suggesting that instead of being tumour-initiating cells, CSCs may be a distinct population of human tumour cells with a greater ability to form tumours in a foreign microenvironment. Additionally, exposure to certain CSC isolation stains such as Hoechst 33342 decreased the ability of C6 glioma cells to proliferate, suggesting that Hoechst-positive (putative non-CSCs) lack tumorigenicity in comparison to their Hoechst-negative counterparts due to the presence or absence of the stain.¹⁸

The ability of a cancer to form from a xenotransplant is likely as varied as the primary cancers from which they originate.^{29–31} While perhaps murine xenotransplantation is not ideal for every cancer, *in vitro* determination of cell tumorigenicity also instills bias as it relies on overcoming inhibitors to *ex vivo* growth.^{18,32,33} Further improvement in FACS technologies as well as enhanced identification of tumorigenic cells by novel analytical methods may be expected to shed light on the often contradictory CSC literature.^{34,35}

CSCs as Prognostic Indicators

Non-small Cell Lung Cancer

Despite improvements in cancer detection and treatment, metastatic non-small cell lung cancer (NSCLC) is the leading cause of cancer death among Canadians.³⁶ The identification of a subset of highly tumorigenic cells has helped in the identification of better prognostic indicators in these patients,

which will hopefully lead the way to better treatment and therefore prolonged survival. Lung CSCs have been identified by a variety of different cell-surface markers and functional capabilities (see Table 1); however, the development of prognostic indices has focused on CD133 expression combined with other markers. Jiang et al. showed that ALDH1A1 expression in 303 clinical specimens correlated with stage and grade of lung tumours and that early-stage tumours with high ALDH1A1 expression were associated with poor prognoses.¹⁰ In 2011, Li et al. found that while CD133 expression was not sufficient to predict recurrence, expression of both CD133 and ABCG2 in NSCLC tumours predicted postoperative recurrence for early-stage NSCLC.³⁷ Recently, Mizugaki et al. found that CD133 expression correlated significantly with pathological stage II-IV NSCLC, independent of age, sex, and smoking history.³⁸ Pirozzi et al., using a 45-patient study, found that CD133 expression correlated significantly with disease-free survival.³⁹ Nevertheless, the value of CD133 expression as a prognostic indicator in NSCLC is somewhat limited as several groups have reported that CD133 is not associated with survival or clinicopathological features of NSCLC.^{40,41}

Breast Cancer

Breast cancer remains the second-leading cause of cancer-related mortality in Canadian women.³⁶ Breast CSCs have been typically identified by CD44⁺/CD24^{-low} cell surface expression; this can be coupled with ALDH activity detection. Ginestier et al. analyzed two independent sets of breast tumours (the University of Michigan set of 154 breast cancer cores [1984–1991] and the Institut Paoli-Calmettes set of 522 cores [1987–1999]) by tissue microarrays for ALDH1A1.⁷ ALDH1A1 status was found to be an independent prognostic factor and ALDH1A1-positive tumours conferred a higher risk of death due to cancer. Similarly, analysis of the Yale Breast Cancer Cohort of 642 surgical patients (1962–1983) revealed that ALDH1A1 and CD44 expression in the cytotokeratin compartment of breast cancer tissue were prognostic of survival, independently of hormone-receptor status, tumour size, nuclear grade, and involvement of lymph nodes.⁴² On the other hand, Abraham et al. found that the percentage of CD44⁺/CD24⁻ breast cancer cells did not correlate significantly with cancer progression, recurrence or disease-free survival;

they suggested that CD44⁺/CD24⁻ breast tumour cells might be important in metastatic disease as the proportion did correlate with distant and/or osseous metastases.⁴³ While the precise contribution of CSCs to breast cancer progression and metastasis remains to be determined, a more precisely defined population of CSCs will clarify the discrepancies in the clinical data. For example, Ginestier's 2007 study found ALDH1 activity in normal mammary stem cells as well as CSCs, which raises the question of whether the tumorigenicity of cells isolated in this manner is due to normal stem cell activity or CSC activity.⁷ Additionally, with the discovery that ALDH1A3 is a primary determinant of Aldefluor activity in breast CSCs, prognostic studies in breast cancer should be expanded to include ALDH1A3.

Colorectal Cancer

Colonic CSCs are primarily identified by CD133 expression. Horst et al. evaluated CD133 status on tumour sections from 77 surgical patients (1994–2004) at the Ludwig-Maximilians-Universität München and demonstrated CD133 expression as an independent prognostic indicator for poor survival.⁴⁴ This was confirmed by Zhang et al., who found that the percentage of CD133⁺/CXCR4⁺ colonic CSCs in human primary cancer predicted a poor prognosis over two years.⁴⁵

Acute Myeloid Leukemia

Leukemia CSCs were initially identified by CD34⁺/CD38⁻ cell surface markers; however, a variety of other markers, such as CD47, are also expressed at higher levels than on non-CSCs. Expression of CD47 was found to be a negative prognostic indicator for AML but, unlike the previously discussed prognostic markers, CD47 plays a functional role by inhibiting phagocytosis of the AML-CSCs.⁴⁶ A genome-wide expression analysis on CD34⁺ AML cells identified several genes (ANKRD28, ankyrin repeat domain 28; GNA15, guanine nucleotide binding protein alpha 15; and UGP2, UDP-glucose pyrophosphorylase 2) for which high levels of transcripts were associated with poorer survival.⁴⁷

Treatment Resistance

Conventional treatment for solid tumours typically consists of local or radical resection, followed by chemotherapy and/or local irradiation. Recent experimental evidence proposes that

CSCs are more resistant to chemotherapeutic drugs and radiation, and that conventional cancer therapies may be insufficient to reduce the CSC burden. Furthermore, if treatment does not eliminate CSCs, the likelihood of recurrence increases.¹⁴

CSCs have been shown to have higher level of ATP-binding-cassette (ABC) transporters, which function as drug efflux transporters.⁴⁸ The body of evidence describing resistance of CSCs to conventional chemotherapies is somewhat confounded by the identification of CSCs by ALDH activity. ALDH1A1 is involved in the detoxification of many toxins within cells, including cyclophosphamide, although evidence for the metabolic targets of ALDH1A3 is lacking.⁴⁹ Since experimental data suggest that not every Aldefluor⁺ cell is a CSC, this method of CSC identification may unintentionally enrich less tumorigenic cells that are more drug-resistant.

Clinically, radiation therapy is fractionated over several weeks or months. This allows non-cancerous cells to (1) repair sublethal levels of DNA damage and (2) repopulate the affected tissue; as well, (3) hypoxic areas of the tumour are reoxygenated, and (4) tumour cells can progress through the cell cycle to the radiosensitive G2/M phases. CSCs can exploit many of the following classical concepts of radiobiology:

1. CSCs have higher levels of DNA repair machinery than non-CSCs.^{50–52}
2. Stem-like cells are enriched during repopulation, although this remains difficult to confirm using current models and technologies.⁵⁰
3. It is not known where CSCs localize in solid tumours and identifying the response of CSCs to hypoxia or radiation-induced reoxygenation is difficult.
4. CSCs can have a long G0 phase or are quiescent.^{53,54}

Long-term clinical studies on the prevalence of CSCs will provide more insight on the contribution of treatment-resistant CSCs to cancer recurrence.

Non-small Cell Lung Cancer

Expression of CD133 on NSCLC cells indicates a chemotherapy-resistant phenotype.⁴⁰ The tumours from 88 patients were analyzed by immunohistochemistry for CD133 status and then for expression of proteins involved in pathways

of chemotherapeutic resistance (DNA repair, detoxification, and drug resistance transporters). Six of the seven proteins analyzed significantly correlated with CD133 expression. Exposure of adherent lung cancer A549 cells to cisplatin resulted in an 8-fold enrichment of CD133⁺ cells.¹⁴ Similar data were obtained in vivo, suggesting that, while chemotherapy may reduce tumour volume, highly tumorigenic CD133⁺ cells may be uninhibited. It was also found that CD133⁺ tumours (9 of 10) were more likely to recur than CD133[−] tumours (22 of 32) after treatment with carboplatin and gemcitabine.

Breast Cancer

Using six breast cancer cell lines, Fillmore and Kuperwasser found that CD44⁺/CD24[−] cells preferentially survived treatment with paclitaxel and 5-fluorouracil in vitro.⁵⁵ Clinical data from Li et al. showed that the percentage of CD44⁺/CD24[−] CSCs increased following treatment with docetaxel or doxorubicin and cyclophosphamide in HER2[−] patients.⁵⁶ In contrast, lapatinib treatment of HER2⁺ patients led to a non-significant decrease in CSC percentage, suggesting that certain treatments may target CSCs.⁵⁶ In a study of breast cancer patients enrolled in two phase II clinical trials, Creighton et al. identified a CD44⁺/CD24^{−/low} gene signature.⁵⁷ Thirty patients were evaluated before and after treatment with letrozole or docetaxel. An enrichment of the CD44⁺/CD24^{−/low} gene signature in breast tumours was observed following chemotherapy.

Colorectal Cancer

Two recent studies have identified CD133⁺ colonic CSCs as resistant to treatment with platinum derivatives. Todaro et al. treated primary colonic CSCs with oxaliplatin and/or 5-fluorouracil.⁵⁸ CD133⁺ cells were resistant to these drugs; however, when treated with an antibody against interleukin-4 (anti-IL-4), the CD133⁺ cells became sensitized to oxaliplatin and 5-FU. Similar sensitization was observed in a xenograft model in nude mice. When xenografted cells in nude mice were treated with oxaliplatin, the percentage of CD133⁺ cells increased in the tumour. Anti-IL-4 co-treatment diminished this selective advantage. This suggests a crucial role for IL-4 in the chemoresistance of colonic CSCs. Similarly, Gallmeier et al. identified CD133⁺ cells as resistant to cisplatin; however, they countered this resistance by pre-treatment with caffeine.⁵⁹

Among other effects, caffeine treatment inhibited the ATR/CHK1-dependent DNA damage response.

Acute Myeloid Leukemia

Jeong et al. identified stem-cell zinc finger transcription factor SALL4 expression as increased in AML patients who experienced drug resistance.⁶⁰ This was confirmed in drug-resistant AML cell lines as well as the Hoechst 33342-excluding side populations of various hematological cell lines. It was then determined that SALL4 regulates ABC transporters, confirming in principle the drug-resistant phenotype. Knocking down SALL4 decreased the relative number of side population cells, suggesting that SALL4 may be important for self-renewal of these putative CSCs.

Targeting CSCs in Treatment

CSCs have been identified as a highly tumorigenic subpopulation of cells within many cancers. As evidence continues to accumulate that suggests they may be more resistant to traditional cancer therapeutics than their non-CSC counterparts, it has become increasingly promising to target these cells on the front lines of cancer treatment.

Key Stem Cell Pathways

CSCs have been found to signal via key embryonic stem cell pathways such as Notch and Wnt. Notch signaling is implicated throughout vertebrate development; most strikingly, its absence causes lethal hyperplasia of the nervous system during embryogenesis.^{61,62} The role of Notch in cell-fate determination and pattern formation can be seen throughout the human body.^{63–65} Aberrant Notch signaling can be oncogenic in some contexts, including mouse mammary tumour virus and T-cell acute lymphoblastic leukemia/lymphoma (T-ALL). Notch can also play a tumour suppressive role in mouse skin and in a K-ras-induced pancreatic cancer.^{66,67}

There are four Notch receptors in mammals (NOTCH1–4) which are type I transmembrane proteins. Signal transduction begins when a ligand (jagged [JAG] 1, JAG2, delta-like ligand [DLL] 1, DLL3 or DLL4) binds to the extracellular domain of the Notch receptor. Following binding, the Notch receptor undergoes cleavage and the active Notch-intracellular domain (NICD) is released from the receptor complex and translocates

into the nucleus.^{68,69} NICD then interacts with other signaling molecules to potentiate Notch signaling.^{70–72} Stylianou et al. demonstrate activation of Notch signaling in breast cancer cell lines and primary tumours; the colony-forming ability of breast cancer MCF7 cells was significantly reduced upon overexpression of the Notch negative regulator NUMB.⁷³ Targeting DLL4, an initiator of Notch signaling, with an anti-DLL4 antibody allows targeted inhibition of angiogenesis as well as a reduction in CSCs.^{74–76} OncoMed Pharmaceuticals (Redwood City, CA) has taken anti-DLL4 demcizumab into clinical trials for pancreatic cancer after showing promising preclinical data.^{77,78}

A requirement in Notch signaling for cleavage by γ -secretase is another hopeful target. Treatment of DAOY medulloblastoma cell xenografts with the γ -secretase inhibitor (GSI)-18 decreased the likelihood of engraftment. Furthermore, the CSC population, identified by either CD133 expression or Hoechst 33342 exclusion, was depleted upon in vitro GSI-18 treatment.⁷⁹ Preclinical as well as clinical data from Schott et al. using a GSI in combination with docetaxel demonstrated a significant decrease in breast CSC population size, although the authors noted that a subpopulation of CSCs remained unaffected by Notch inhibition.⁸⁰ While initially promising, mice and T-ALL patients treated with non-specific GSIs developed significant dose-limiting gastrointestinal problems.^{81,82} The mice also demonstrated immunosuppression.⁸¹ The gastrointestinal effects seen with GSI treatment necessitate close attention to minimize the dose required.⁸³

The wingless/Wnt pathway is also involved in regulation of embryonic development, including cell fate determination, cell proliferation and cell migration. The Wnt signal is initiated by the binding of extracellular Wnt ligands to frizzled receptors (FZD1–10) within the cell membrane. This leads to recruitment of disheveled (DVL1, DVL2) which prevents glycogen synthase kinase 3β (GSK3 β) from interacting with and phosphorylating its substrates.⁸⁴ A primary target of GSK3 β is B-catenin, which when unphosphorylated can translocate to the nucleus and interact with other effector molecules.^{85–87}

Wnt/ β -catenin signaling has also been implicated in many human cancers, particularly in colon cancer where mutations in the adenomatous polyposis coli (APC) tumour suppressor

gene renders cells unable to sufficiently degrade β -catenin.^{88,89} Aberrant Wnt/b-catenin signaling has also been associated with other cancers, including breast, lung, prostate, and pancreatic cancers.^{90–93} Wnt activity has also been associated with colonic, lung, and gastric CSCs.^{94–96} The Wnt pathway is thus a hopeful target for CSC therapies.

OncoMed Pharmaceuticals has developed a Wnt inhibitor, anti-Frizzled (vantictumab), currently in clinical trials following promising preclinical data.⁹⁷ Vantictumab binds a conserved epitope on five of the human Frizzled receptors, blocking canonical Wnt signaling. This effect functioned synergistically with standard chemotherapies in treating several human tumour xenografts.⁹⁷ Additionally, PRISM Pharma Co. (Tokyo) has developed a Wnt inhibitor, PRI-724, which targets the interaction between B-catenin and CREB binding protein (CBP) and reduces B-catenin dependent transcriptional activation.⁹⁸ PRI-724 is currently undergoing a phase I clinical trial.

Targeting CSCs in combination with conventional chemotherapies appears to be a promising mode of treatment. These novel therapeutic regimens will ideally reduce the CSC burden in parallel with a reduction in overall tumour burden, leading to increased progression-free and overall survival.

Epigenetic Treatments

Recently, epigenetic modifications of cancer cells have become an attractive target for targeted CSC treatment. Reversing the tumour-suppressor gene-silencing associated with promoter hypermethylation can induce changes in signaling pathways and may be able to subvert the tumorigenic signaling enmeshed in tumour cells. Previous research with demethylating agents (200–600 mg/m²) was associated with high toxicity, which likely hid the true effect of DNA demethylation on the patient tumours.^{99,100} A recent clinical study using azacitidine (AZA) (30–40 mg/kg) reported significant numbers of adverse events, which was expected because of the toxicity of the drugs used.¹⁰¹ The 2011 paper by Tsai et al. indicated that the number of adverse events may be reduced with increased efficacy of the epigenetic drugs at lower dosages.¹⁰² Primary cancer cells as well as cancer cell lines were treated with low doses of DNA-demethylating agents AZA and decitabine (DAC).¹⁰² In vitro 3-day treatment with low doses of AZA and DAC reduced the number of CD44⁺/ALDH⁺ cells

with no changes in the CD44⁺/ALDH⁺ population in breast cancer cell lines MCF7 and T-47D. Similar dosages in NOD/SCID mice (0.5 mg/kg) resulted in decreased growth of cell line xenografts as well as primary breast tumour xenografts. Careful attention to these recent findings may allow a reconsideration of the toxicities associated with previous clinical trials, and epigenetic therapy for solid tumours may see a resurgence.

Conclusions

The majority of cancer-related deaths are caused by metastases rather than the primary tumour. The subset of highly tumorigenic CSCs within solid tumours likely contribute to disease progression and recurrence as these cells are not well targeted by current conventional chemotherapy and radiation treatment. CSCs represent a promising avenue of research as new CSC-targeted drugs and antibodies in combination with current treatment protocols may potentially decrease cancer-related morbidity and mortality. Further characterization of CSCs and precisely defined CSC phenotypes will serve to clarify discrepancies in the literature and improve targeted CSC therapeutics.

References

1. Lapidot T, Sirad C, Vormoor J, et al. A cell initiating human acute myeloid leukaemia after transplantation into SCID mice. *Nature* 1994;367:645–8.
2. Bonnet D, Dick J. Human acute myeloid leukemia is organized as a hierarchy that originates from a primitive hematopoietic cell. *Nat Med* 1997;3:730–7.
3. Al-Hajj M, Wicha MS, Benito-Hernandez A, et al. Prospective identification of tumorigenic breast cancer cells. *Proc Natl Acad Sci USA* 2003;100:3983–8.
4. Singh S, Clarke I, Terasaki M, et al. Identification of a cancer stem cell in human brain tumors. *Cancer Res* 2003;63:5821–8.
5. Visvader J. Cells of origin in cancer. *Nature* 2011;469:314–22.
6. Nguyen L, Vanner R, Dirks P, et al. Cancer stem cells: an evolving concept. *Nat Rev Cancer* 2012;12:133–43.
7. Ginestier C, Hur MH, Charafe-Jauffret E, et al. ALDH1 is a marker of normal and malignant human mammary Stem Cells and a predictor of poor clinical outcome. *Cell Stem Cell* 2007;1:555–67.
8. Ma S, Chan KW, Lee TK, et al. aldehyde dehydrogenase discriminates the CD133 Liver cancer stem cell populations. *Mol Cancer Res* 2008;6:1146–53.
9. Huang EH, Hynes MJ, Zhang T, et al. Aldehyde dehydrogenase 1 is a marker for normal and malignant human colonic stem cells (SC) and Tracks SC overpopulation during colon tumorigenesis. *Cancer Res* 2009;69:3382–9.
10. Jiang F, Qiu Q, Khanna A, et al. Aldehyde dehydrogenase 1 is a tumor stem cell-associated marker in lung cancer. *Mol Cancer Res* 2009;7:330–8.
11. Eirew P, Kannan N, Knapp DJ, et al. Aldehyde dehydrogenase activity is a biomarker of primitive normal human mammary luminal cells. *Stem Cells* 2012;30:344–8.
12. Marcato P, Dean C, Da Pan, et al. aldehyde dehydrogenase activity of breast cancer stem cells is primarily due to isoform ALDH1A3 and its expression is predictive of metastasis. *Stem Cells* 2011;29:32–45.
13. Luo Y, Dallaglio K, Chen Y, et al. ALDH1A Isozymes are markers of human

- melanoma stem cells and potential therapeutic targets. *Stem Cells* 2012;30:2100–13.
14. Bertolini G, Roz L, Perego P, et al. Highly tumorigenic lung cancer CD133+ cells display stem-like features and are spared by cisplatin treatment. *Proc Natl Acad Sci USA* 2009;106:16281–6.
15. Trumpp A, Wiestler O. Mechanisms of Disease: cancer stem cells—targeting the evil twin. *Nat Clin Pract Oncol* 2008;5:337–47.
16. Takahashi K, Yamanaka S. Induction of Pluripotent Stem cells from mouse embryonic and adult fibroblast cultures by defined factors. *Cell* 2006;126:663–76.
17. Rapp UR, Ceteci F, Schreck R. Oncogene-induced plasticity and cancer stem cells. *Cell Cycle* 2008;7:45–51.
18. Zheng X, Shen G, Yang X, et al. Most C6 cells are cancer stem cells: evidence from clonal and population analyses. *Cancer Res* 2007;67:3691–7.
19. Nishi M, Sakai Y, Akutsu H, et al. Induction of cells with cancer stem cell properties from nontumorigenic human mammary epithelial cells by defined reprogramming factors. *Oncogene* 2013 [Epub ahead of print].
20. Iliopoulos D, Hirsch H, Wang G, et al. Inducible formation of breast cancer stem cells and their dynamic equilibrium with non-stem cancer cells via IL6 secretion. *Proc Natl Acad Sci USA* 2011;108:1397–402.
21. McLendon A, Rich J, Heddleston J, et al. The hypoxic microenvironment maintains glioblastoma stem cells and promotes reprogramming towards a cancer stem cell phenotype. *Cell Cycle* 2009;8:3274–84.
22. Rappa G, Lorico A. Phenotypic characterization of mammosphere-forming cells from the human MA-11 breast carcinoma cell line. *Exp Cell Res* 2010;316:1576–86.
23. Sharma S, Lee D, Li B, et al. A chromatin-mediated reversible drug-tolerant state in cancer cell subpopulations. *Cell* 2010;141:69–80.
24. Chaffer C, Brueckmann I, Scheel C, et al. Normal and neoplastic nonstem cells can spontaneously convert to a stem-like state. *Proc Natl Acad Sci USA* 2011;108:7950–5.
25. Iliopoulos D, Hirsch H, Struhl K. An Epigenetic Switch Involving NF- κ B, Lin28, Let-7 MicroRNA, and IL6 Links Inflammation to Cell Transformation. *Cell* 2009;139:693–706.
26. Kern S, Shibata D. The fuzzy math of solid tumor stem cells: a perspective. *cancer res* 2007;67:8985–8.
27. Adams J, Strasser A. Is tumor growth sustained by rare cancer stem cells or dominant clones? *Cancer Res* 2008;68:4018–21.
28. Kelly P, Dakic A, Adams J, et al. Tumor growth need not be driven by rare cancer stem cells. *Science* 2007;317:337.
29. Kennedy J, Barabe F, Poepl A, et al. Comment on “tumor growth need not be driven by rare cancer stem cells.” *Science* 2007;318:1722c.
30. John T, Kohler D, Pintilie M, et al. The ability to form primary tumor xenografts is predictive of increased risk of disease recurrence in early-stage non-small cell lung cancer. *Clin Cancer Res* 2011;17:134–41.
31. Pearce DJ, Taussig D, Zibara K, et al. AML engraftment in the NOD/SCID assay reflects the outcome of AML: implications for our understanding of the heterogeneity of AML. *Blood* 2005;107:1166–73.
32. Stiles C, Desmond W, Chuman L, et al. Relationship of cell growth behavior in vitro to tumorigenicity in athymic nude mice. *Cancer Res* 1976;36:3300–5.
33. Lee J, Kotliarova S, Kotliarov Y, et al. Tumor stem cells derived from glioblastomas cultured in bFGF and EGF more closely mirror the phenotype and genotype of primary tumors than do serum-cultured cell lines. *Cancer Cell* 2006;9:391–403.
34. Wurdak H, Zhu S, Romero A, et al. An RNAi Screen Identifies TRRAP as a regulator of brain tumor-initiating cell differentiation. *Cell Stem Cell* 2010;6:37–47.
35. Ji J, Yamashita T, Reid L, et al. Identification of MicroRNAs specific to hepatic cancer stem cells but not to normal stem cells by small RNA deep sequencing [abstract]. In: NIH 2011 Research Festival; 2011 Oct 24–28; Bethesda, MD. Available at <http://researchfestival.nih.gov/2011/posters.cgi?id=CANCER-30>.
36. Canadian Cancer Statistics 2012. Canadian Cancer Society, Statistics Canada, Public Health Agency of Canada. 2012.
37. Li F, Zeng H, Ying K. The combination of stem cell markers CD133 and ABCG2 predicts relapse in stage I non-small cell lung carcinomas. *Med Oncol* 2011;28:1458–62.
38. Mizugaki H, Skakibara-Konishi J, Kikuchi J, et al. CD133 expression: a potential prognostic marker for non-small cell lung cancers. *Int J of Clin Oncol* 2013; [Epub ahead of print].
39. Pirozzi G, Tirino V, Camerlingo R, et al. Prognostic value of cancer stem cells, epithelial-mesenchymal transition and circulating tumor cells in lung cancer. *Oncol Reports* 2013;29:1763–8.
40. Salnikov AV, Gladkikh J, Moldenhauer G, et al. CD133 is indicative for a resistance phenotype but does not represent a prognostic marker for survival of non-small cell lung cancer patients. *Int J Cancer* 2009;126:950–8.
41. Herpel E, Jensen K, Muley T, et al. The cancer stem cell antigens CD133, BCRP1/ABCG2 and CD117/c-KIT are not associated with prognosis in resected early-stage non-small cell lung cancer. *AntiCancer Res* 2011;31:4491–500.
42. Neumeister V, Agarwal S, Bordeaux J, et al. In situ identification of putative cancer stem cells by multiplexing ALDH1, CD44, and cytokeratin identifies breast cancer patients with poor prognosis. *Am J Pathol* 2010;176:2131–8.
43. Abraham BK, Fritz P, McClellan M, et al. Prevalence of CD44+/CD24-/low cells in breast cancer may not be associated with clinical outcome but may favor distant metastasis. *Clin Cancer Res* 2005;11:1154–9.
44. Horst D, Kriegl L, Engel J, et al. CD133 expression is an independent prognostic marker for low survival in colorectal cancer. *Brit J Cancer* 2008;99:1285–9.
45. Zhang S, Hospital E, Han Z, et al. CD133+CXCR4+ colon cancer cells exhibit metastatic potential and predict poor prognosis of patients. *BMC Med* 2012;10:85.
46. Majeti R, Chao M, Alizadeh A, et al. CD47 is an adverse prognostic factor and therapeutic antibody target on human acute myeloid leukemia stem cells. *Cell* 2009;138:286–99.
47. Jonge H, Woolthuis C, Vos A, et al. Gene expression profiling in the leukemic stem cell-enriched CD34+ fraction identifies target genes that predict prognosis in normal karyotype AML. *Leukemia* 2011;25:1825–33.
48. Hirschmann-Jax C. A distinct “side population” of cells with high drug efflux capacity in human tumor cells. *Proc Natl Acad Sci USA* 2004;101:14228–33.
49. Magni M, Shammah S, Schiro R, et al. Induction of cyclophosphamide-resistance by aldehyde-dehydrogenase gene transfer. *Blood* 1996;87:1097–103.
50. Phillips T, McBride W, Pajonk F. The response of CD24-/low/CD44+ breast cancer-initiating cells to radiation. *J Nat Cancer Inst* 2006;98:1777–85.
51. Zhang M, Behbod F, Atkinson R, et al. Identification of tumor-initiating cells in a p53-null mouse model of breast cancer. *Cancer Res* 2008;68:74–82.
52. Diehn M, Cho R, Lobo N, et al. Association of reactive oxygen species levels and radioresistance in cancer stem cells. *Nature* 2009;458:780–3.
53. Dembinski JL, Krauss S. Characterization and functional analysis of a slow cycling stem cell-like subpopulation in pancreas adenocarcinoma. *Clin Exp Metastasis* 2009;26:611–23.
54. Saito Y, Uchida N, Tanaka S, et al. Induction of cell cycle entry eliminates human leukemia stem cells in a mouse model of AML. *Nat Biotechnol* 2010;28:275–80.
55. Fillmore C, School S, Kuperwasser C, et al. Human breast cancer cell lines contain stem-like cells that self-renew, give rise to phenotypically diverse progeny and survive chemotherapy. *Breast Cancer Res* 2008;10:R25.
56. Li X, Lewis MT, Huang J, et al. Intrinsic resistance of tumorigenic breast cancer cells to chemotherapy. *J Natl Cancer Inst* 2008;100:672–9.
57. Creighton C, Li X, Landis M, et al. Residual breast cancers after conventional therapy display mesenchymal as well as tumor-initiating features. *Proc Natl Acad Sci USA* 2009;106:13820–5.
58. Todaro M, Alea M, Stefano A, et al. colon cancer stem cells dictate tumor growth and resist cell death by production of interleukin-4. *Stem Cell* 2007;1:389–402.
59. Gallmeier E, Hermann PC, Mueller M, et al. Inhibition of ataxia telangiectasia- and Rad3 -related function abrogates the in vitro and in vivo tumorigenicity of human colon cancer cells through depletion of the CD133+ tumor-

- initiating cell fraction. *Stem Cells* 2011;29:418–29.
60. Jeong H, Cui W, Yang Y, et al. SALL4, a Stem cell factor, affects the side population by regulation of the ATP-binding cassette drug transport genes. *PLOS one* 2011;6:e18372.
 61. Fexova K, Djiane A, Krejci A, et al. Dissecting the mechanisms of Notch induced hyperplasia. *EMBO J* 2013;32:60–71.
 62. Le Borgne R, Bardin A, Schweisguth F. The roles of receptor and ligand endocytosis in regulating notch signaling. *Development* 2005;132:1751–62.
 63. Conboy I, Rando T. The regulation of notch signaling controls satellite cell activation and cell fate determination in postnatal myogenesis. *Dev Cell* 2002;3:397–409.
 64. Murtaugh LC, Ben Stanger Z, Kwan KM, et al. Notch signaling controls multiple steps of pancreatic differentiation. *Proc Natl Acad Sci USA* 2003;100:14920–5.
 65. Yoon K, Gaiano N. Notch signaling in the mammalian central nervous system: insights from mouse mutants. *Nat Neurosci*. 2005;8:709–5.
 66. Hanlon L, Avila J, Demarest R, et al. Notch1 Functions as a Tumor Suppressor in a Model of K-ras-Induced Pancreatic Ductal Adenocarcinoma. *Cancer Res* 2010;70:4280–6.
 67. Nicolas M, Wolfer A, Raj K, et al. Notch1 functions as a tumor suppressor in mouse skin. *Nat Genet* 2003;33:416–21.
 68. Strooper B, Annaert W, Cupers P, et al. A presenilin-1-dependent γ -secretase-like protease mediates release of notch intracellular domain. *Nature* 1999;398:518–22.
 69. Schroeter E, Kisslinger J, Kopan R. Notch-1 signalling requires ligand-induced proteolytic release of intracellular domain. *Nature* 1998;393:382–6.
 70. Ross DA, Kadesch T. The notch intracellular domain can function as a coactivator for LEF-1. *Mol Cell Biol* 2001;21:7537–44.
 71. Blokzijl A, Dahlqvist C, Reissman E, et al. Cross-talk between the Notch and TGF- signaling pathways mediated by interaction of the Notch intracellular domain with Smad3. *J Cell Biol* 2003;163:723–8.
 72. Zhou S, Fujimuro M, Hsieh J, et al. SKIP, a CBF1-associated protein, interacts with the ankyrin repeat domain of notchIC to facilitate notchIC function. *Mol Cell Biol* 2000;20:2400–10.
 73. Stylianou S, Clarke RB, Brennan K. Aberrant activation of notch signaling in human breast cancer. *Cancer Res* 2006;66:1517–25.
 74. Noguera-Troise I, Daly C, Papadopoulos N, et al. Blockade of DLL4 inhibits tumour growth by promoting non-productive angiogenesis. *Nature* 2006;444:1032–7.
 75. Hoey T, Yen W, Axelrod F, et al. DLL4 Blockade inhibits tumor growth and reduces tumor-initiating cell frequency. *Cell Stem Cell* 2009;5:168–77.
 76. Ridgway J, Zhang G, Wu Y, et al. Inhibition of DLL4 signalling inhibits tumour growth by deregulating angiogenesis. *Nature* 2006;444:1083–7.
 77. Yen W, Fischer M, Hynes M, et al. Anti-DLL4 has broad spectrum activity in pancreatic cancer dependent on targeting dll4-notch signaling in both tumor and vasculature cells. *Clin Cancer Res* 2012;18:5374–86.
 78. Fischer M, Yen W, Kapoun A, et al. Anti-DLL4 inhibits growth and reduces tumor-initiating cell frequency in colorectal tumors with oncogenic KRAS mutations. *Cancer Res* 2011;71:1520–5.
 79. Fan X, Matsui W, Khaki L, et al. Notch pathway inhibition depletes stem-like cells and blocks engraftment in embryonal brain tumors. *Cancer Res* 2006;66:7445–52.
 80. Schott A, Landis M, Dontu G, et al. Preclinical and clinical studies of gamma secretase inhibitors with docetaxel on human breast tumors. *Clin Cancer Res* 2013;19:1512–24.
 81. Wong G. Chronic treatment with the γ -secretase inhibitor LY-411,575 inhibits β -amyloid peptide production and alters lymphopoiesis and intestinal cell differentiation. *J Biol Chem* 2003;279:12876–82.
 82. Deangelo DJ, Stone RM, Silverman LB, et al. A phase I clinical trial of the notch inhibitor MK-0752 in patients with T-cell acute lymphoblastic leukemia/lymphoma (T-ALL) and other leukemias. *J Clin Oncol*. 2006;24:6585.
 83. Osipo C, Zlobin, Olsauskas-Kuprys. Gamma secretase inhibitors of Notch signaling. *OncoTargets Ther* 2013;6:943–55.
 84. Wagner U, Brownlees J, Irving NG, et al. Overexpression of the mouse dishevelled-1 protein inhibits GSK-3 β -mediated phosphorylation of tau in transfected mammalian cells. *FEBS Lett* 1997;411:369–72.
 85. Orford K, Crockett C, Jensen JP, et al. Serine Phosphorylation-regulated Ubiquitination and Degradation of beta -Catenin. *J Biol Chem* 1997;272:24735–8.
 86. Aberle H, Bauer A, Stappert J, et al. β -catenin is a target for the ubiquitin-proteasome pathway. *EMBO J* 1997;16:3797–804.
 87. Behrens J, Kries von JP, Kühl M, et al. Functional interaction of β -catenin with the transcription factor LEF-1. *Nature* 1996;382:638–42.
 88. Munemitsu S, Albert I, Souza B, et al. Regulation of intracellular β -catenin levels by the adenomatous polyposis coli (APC) tumor-suppressor protein. *Proc Natl Acad Sci USA* 1995;92:3046–50.
 89. Rubinfeld B, Albert I, Porfiri E, et al. Binding of GSK3beta to the APC-beta-catenin complex and regulation of complex assembly. *Science* 1996;272:1023–6.
 90. Yoshida R, Kimura N, Harada Y, et al. The loss of E-cadherin, α - and β -catenin expression is associated with metastasis and poor prognosis in invasive breast cancer. *Int J Oncol*;18:513–20.
 91. Yang L, Shenyang C, Xu H, et al. Axin downregulates TCF-4 transcription via β -catenin, but not p53, and inhibits the proliferation and invasion of lung cancer cells. *Mol Cancer* 2010;9:25.
 92. Farina AK, Bong Y, Feltes CM, et al. Post-transcriptional regulation of cadherin-11 expression by GSK-3 and β -Catenin in prostate and breast cancer cells. *PLOS one* 2009;4:e4797.
 93. Li Y, Wei Z, Meng Y, et al. β -catenin up-regulates the expression of cyclinD1, c-myc and MMP-7 in human pancreatic cancer: Relationships with carcinogenesis and metastasis. *World J Gastroenterol* 2005;11:2117–23.
 94. Vermeulen L, Melo F, Heijden M, et al. Wnt activity defines colon cancer Stem Cells and is regulated by the microenvironment. *Nat Cell Biol* 2010;12:468–76.
 95. Teng Y, Wang X, Wang Y, et al. Wnt/ β -catenin signaling regulates cancer Stem Cells in lung cancer A549 cells. *Biochem Biophys Res Comm* 2010;392:373–9.
 96. Cai C, Zhu X. The Wnt/ β -catenin pathway regulates self-renewal of cancer stem-like cells in human gastric cancer. *Mol Med Rep* 2012;5:1191–6.
 97. Gurney A, Axelrod F, Bond C, et al. Wnt pathway inhibition via the targeting of Frizzled receptors results in decreased growth and tumorigenicity of human tumors. *Proc Natl Acad Sci USA* 2012;109:11717–22.
 98. El-Khoueiry AB, Ning Y, Yang D, et al. A phase I first-in-human study of PRI-724 in patients (pts) with advanced solid tumors [abstract]. In: *J Clin Oncol ASCO Annual Meeting Proceedings*; 2013 May 31–Jun 4; Chicago, IL. 31:Abstr no. 2501.
 99. Momparler RL, Bouffard DY, Momparler LF, et al. Pilot phase I-II study on 5-aza-2'-deoxycytidine (Decitabine) in patients with metastatic lung cancer. *Anticancer Drugs* 1997;8:358–68.
 100. Abele R, Clavel M, Dodion P, et al. The EORTC early clinical trials cooperative group experience with 5-aza-2'-deoxycytidine (NSC 127716) in patients with colo-rectal, head and neck, renal carcinomas and malignant melanomas. *Eur J Cancer Clin Oncol* 1987;23:1921–4.
 101. Juergens RA, Wrangle J, Vendetti FP, et al. A combined epigenetic therapy equals the efficacy of conventional chemotherapy in refractory advanced non-small cell lung cancer. *Cancer Discovery* 2011;1:557–9.
 102. Tsai H, Li H, van Neste L, et al. Transient low doses of DNA-demethylating agents exert durable antitumor effects on hematological and epithelial tumor cells. *Cancer Cell* 2012;21:430–46.
 103. Leung E, Fiscus R, Tung J, et al. Non-small cell lung cancer cells expressing CD44 are enriched for stem cell-like properties. *PLOS ONE* 2010;5:e14062.
 104. Dalerba P, Dylla SJ, Park I-K, et al. Phenotypic characterization of human colorectal cancer stem cells. *Proc Natl Acad Sci USA* 2007;104:10158–63.

Pathology Review



Zu-hua Gao, Editor
Brush Education Inc, 2013
ISBN: 9781550594393
560 pages, hardcover

Pathology Review, a multi-authored book with a single editor, has been written to provide a learning resource for those candidates preparing for their Canadian or US fellowship or board examinations.

I received the book at 11:12 on a Tuesday morning. At 11:28 I gave it to one of our final-year residents as I thought she might find it useful. At 11:47, two of the final-year residents came rushing to my office asking if I knew whether they could get a discount on multiple copies and, more importantly, how quickly they could get their own copy. I took all of this to represent fairly positive first impressions of this book, and when I eventually managed to wrest my copy from them, I took a look myself. The book is divided into chapters based on systems, with one chapter on basic science and quality management. Some chapters are written by senior experts in their field, while others are co-authored by junior faculty members and residents; one chapter is written by a fellow and a resident. The chapters are uniformly organized, beginning with a series of multiple-choice questions, followed by short-answer questions (including “case scenarios” in some chapters), and ending with a selection of gross and microscopic images. At the end of each chapter, there is a short list of the most relevant references, including, for the most part, books, book chapters, and review articles. The chapters are all well written, appropriately up to date and, despite the many authors, uniform in style. There are many tables and lists, including lists of syndrome components (one of the many banes of the life of a final-year resident) as well as classic electron microscopic features of various entities.


The introductory chapter provides an overview of the format of the Canadian and US fellowship/board examinations and provides useful tips and information on how candidates can perform at their best at the examinations. I note that some of these tips are rather similar to those in the presentation that is given to candidates at the Canadian Association of Pathologists’ Examination Review Course.

Overall, this book is an excellent resource for candidates preparing for the Canadian fellowship examination. While the book should be useful to candidates preparing for the US boards (particularly with the inclusion of MCQs), I believe that those preparing for the Canadian examination will benefit most. I would recommend that, in a future edition, the section on laboratory management and quality assurance be expanded significantly to include more scenarios, as these are so common in the oral component of the examination. The use of case scenarios in some chapters appears a little contrived and could be omitted. Overall, the quality of images is excellent, especially, for example, in the cardiovascular and forensic chapters. Some of the microscopic images suffer from white balance issues, especially those in the skin, lymph node, genitourinary, and renal chapters.

In conclusion, I am certain that this book will become popular among residents preparing for their examinations, and that my own residents’ first impressions were correct. I commend the editor and the authors for putting this book together.

David Driman, MBChB, FRCPC
Department of Pathology
London Health Sciences Centre and Western University
London, Ontario

In Situ Molecular Pathology and Co-Expression Analyses



Gerard J. Nuovo
Elsevier/Academic Press, 2013
ISBN: 978-0-12-415944-0
298 pages, hardcover

In Situ Molecular Pathology and Co-Expression Analyses is clearly a labour of love. The foreword to the book is an autobiographical snapshot, and parts of the introduction read much the same. The writing style is almost conversational, or certainly reflects the type of conversation a mentor would have with his or her trainee. The chapters are painstakingly laid out in a very logical manner that is endearingly pedantic.

In the first six chapters, the “basics” of molecular pathology, in situ hybridization, immunohistochemistry, and histological interpretation are covered in detail. Both the biochemical basis of the techniques (covered in Chapter 3) and the detailed rationale and process of these techniques are covered. The style and layout of the book will make it useful as a companion reference to more comprehensive texts on pathology, which often give no details on procedures but focus on anatomical characteristics of tissues. The later chapters of the book, Chapters 7–10, focus more specifically on troubleshooting and interpretation of the data, as well as the particular vagaries of co-expression analyses and in situ DNA and RNA amplification and detection, a topic on which the author is most expert. As such, this book will no doubt be an excellent teaching text for novices, as well as serving as a refresher for those more experienced in molecular pathology approaches.

G. Dellaire, PhD
Director of Research, Department of Pathology
Dalhousie University
Halifax, Nova Scotia

**PARTNERING WITH
GAMMA-DYNACARE
ALLOWS YOU TO FOCUS
ON WHAT YOU DO BEST**



- Cytology
- Histology
- Immunohistochemistry
- Allergy Testing
- Flow Cytometry
- Esoteric Testing

As your partner, we bring you:

- Leadership
- Confidence
- Convenience
- Value

**Make our laboratories an extension of *your* hospital;
our pathologists a part of *your* team.**

www.gamma-dynacare.com

For more information:

Phone: 800.668.2714

Email: hospital_services@gamma-dynacare.com