CJRDP | JCDRP

Canadian Journal of
Restorative Dentistry & Prosthodontics

Journal canadien de
dentisterie restauratrice et de prosthodontie

The official publication of the Canadian Academy of Restorative Dentistry and Prosthodontics

www.cardp.ca

Publication officielle de l'Académie canadienne de dentisterie restauratrice et de prosthodontie

Restorative Dentistry

On-Line Exclusives

Dentisterie restauratrice

Exclusif en ligne

VOLUME 4 - 2
SUMMER/ÉTÉ 2011

PEER-REVIEWED -
JOURNAL - REVUE DES PAIRS

PUBLICATIONS AGREEMENT # 40025049 • ISSN 1916-7520

ANDREW JOHN PUBLISHING INC.
www.andrewjohnpublishing.com

Une invitation du Président de l'ACDRP

Je suis honoré de démarrer cette année en tant que Président de l'Académie canadienne de dentisterie restauratrice et de prosthodontie.

Au tout début de ma carrière, j'ai eu la chance d'assister, comme invité, à des rencontres de l'APC/ACDR. Dès lors j'ai eu l'impression que ces deux académies offraient quelque chose d'unique: une formation dentaire et un mentorat sans pareils, et surtout, des liens amicaux durables d'un océan à l'autre. Je souhaite sincèrement renchérir sur cet héritage durant mon mandat.

Une quantité considérable de travail est nécessaire dans la préparation des congrès annuels ainsi que le Journal de l'ACDRP, en plus de l'administration quotidienne de notre Académie. Je tiens à reconnaître tout spécialement Dr. Cary Letkemann, Président de notre Congrès cette année, tous les Comités, le Dr Hubert Gaucher, Rédacteur-en-chef de notre Journal pour son dévouement intarissable, et en dernier lieu, Alexander/Richardson qui rendent mémorable chacune de nos rencontres.

Comme partout ailleurs dans le domaine dentaire, notre organisme subit certaines transformations tandis que nous nous efforçons de produire les meilleures expériences dans un marché extêmement concurrentiel. C'est pourquoi nous devons nous entraider. Notre seul obstacle, à vrai dire, c'est l'apathie. Je fais donc appel à chacun parmi vous d'assister au Congrès de cette année à Toronto, du 22 au 24 septembre, et de surcroît, d'inviter un membre potentiel. Ne tardez pas. Notez la date à votre agenda et appelez un collègue dès aujourd'hui.

Plusieurs autres façons existent aussi pour venir en aide à votre Académie, par exemple: oeuvrer sur un comité, contribuer un article pour le Journal, présenter une démonstration clinique. Votre participation n'aura jamais eu autant de portée car, sans vous, nous cesserons de progresser. Alors "Assistez et Invitez".

On se voit à Toronto!

Cordialement,
Dr Kim Parlett

Un message du Président du congrès

En tant que Président du congrès, il me fait plaisir de vous convier à notre 19ième congrès annuel de l'Académie canadienne de dentisterie restauratrice et de prosthodontie qui aura lieu à Toronto du 22 au 24 septembre 2011. Cette année, l'événement se tiendra au prestigieux Fairmont Royal York Hotel. Étant donné que notre organisme est le seul au niveau national qui soit dédié à tous les aspects de la dentisterie restauratrice et de la prosthodontie, notre Académie présentera un illustre assemblage de conférenciers et de thèmes de fine pointe. Nous offrirons de plus in grande variété d'activités sociales pour plaire à tous les goûts.

Jeudi le 22 septembre sera une journée scientifique optionnelle et contingentée, animée par le célèbre Dr. Terry Tanaka, qui offrira un programme pratique intitulé "L'esthétique et l'occlusion". Pour ceux qui préfèrent la détente, 2 passe-temps sportifs seront à l'ordre du jour: Un tournoi de golf au Eagle's Nest ou à Copper Creek, ou bien de la voile dans le port du Lac Ontario. La journée se terminera à l'hôtel, pour une réception de bienvenue. La bonne chère, des appéros, de la musique et l'opportunité de rencontrer amis, collègues et exposants agrémenteront cette rencontre conviviale.

Le vendredi sera le coeur du programme scientifique. On y introduira 6 présentations d'une heure chacune, proposées par Dr. Terry Tanaka, Dr. Jay Gibson, Dr. Terry Donovan, Dr. John Davies, Dr. Winston Chee et Dr. Daniel Melker. Un assortiment de sujets seront discutés: les mini implants pour ancrage orthodontique, la recherche sur les cellules souches, l'usure et l'érosion, les facteurs occlusaux relatifs aux restorations implantaires, les dangers à éviter en dentisterie implantaire et la science de la sauvegarde des dents.

Ceux et celles qui n'assisteront pas au congrès pourront profiter d'un programme agréable conçu pour vous enchanter. La soirée sera ensuite libre pour découvrir l'innombrable sélection de restaurants et de divertissements qu'offre Toronto. Samedi matin, 8 présentations cliniques brèves de 18 minutes se succèderont durant lesquelles les conférenciers n'auront le temps que de vous fournir uniquement les faits. L'après-midi sera consacré aux démonstrations cliniques qui vous soumettront des techniques concrètes et pratiques. Le congrès sera couronné par le Bal du Président comportant la réception au champagne, une cuisine raffinée et de la danse au son du 905 Band, l'une des plus réputées au Canada. Soyez-y puisque vous ne voudriez pas regretter tous les plaisirs que vos amis auront goûtés! Au plaisir de vous voir,

Dr Cary Letkemann
Président du congrès

CJRDP JCDRP

VOLUME 4 • ISSUE 2

CJRDP Editorial Board/ Le comité de rédaction JCDRP

Editor-in-Chief/ Rédacteur en chef
HUBERT GAUCHER
Québec City, Québec

Associate Editors/Rédacteurs associés

EMMANUEL J. RAJCZAK
Hamilton, Ontario

MAUREEN ANDREA
Chester, Nova Scotia

DENNIS NIMCHUK
Vancouver, British Columbia

Section Editors/Section éditeurs

Occlusion and Temporo-Mandibular Dysfunctions/ Occlusion et Dysfonctions temporo-mandibulaire
KIM PARLETT
Bracebridge, Ontario

Occlusion and Temporo-Mandibular Dysfunctions/ Occlusion et Dysfonctions temporo-mandibulaire
IAN TESTER
St. Catharines, Ontario

Implant Dentistry/ Dentisterie implantaire
RON ZOKOL
Vancouver, British Columbia

Implant Dentistry/ Dentisterie implantaire
YVAN FORTIN
Québec City, Québec

Esthetic Dentistry / Dentisterie esthétique
PARESH SHAH
Winnipeg, Manitoba

Dental Technology / Technologie dentaire
PAUL ROTSAERT
Hamilton, Ontario

Content/Sommaire

4 Message from the Guest Editor
The Road Not Taken

5 Message de la rédactrice invité
Le chemin non empruntée

FEATURES/ARTICLES

6 19th Annual Scientific Meeting "The Pursuit of Excellence"

2 19ième Congrès scientifique annuelle ("La poursuite de l'excellence")

Restorative Dentistry / Dentisterie restauratrice

18 The Restorative Cycle in Dentistry
Le cycle restaurateur en dentisterie
By Dr. Dan B. Henry, DDS, FACD, FICD

25 Contemporary Restorative Indications for the Use of Cast Gold: An Evidence-Based Perspective
Indications contemporaines pour l'utilisation des restaurations en or: une perspective fondée sur les preuves
By Dr. Mark A. Cruz, DDS

33 Esthetic 7/8 Gold Crown – The Tucker Technique
Couronne esthétique 7/8 en or
By Dr. Randall J. Allan BSc, DMD

41 Utilisation des incrustations en or avec recouvrement des cuspides dans un cas de réhabilitation extensive. Un rapport de cas
Gold Inlays with Cuspal Coverage for an Extensive Rehabilitation Case. A Case Report
Par Dr Hugo Ciaburro

45 Conservative and Esthetic Cast Gold Fixed Partial Dentures – Inlay, Onlay, and Partial Veneer Retainers, Custom Composite Pontics, and Stress Breakers: Part II: Utilization of Additional Retentive Features and Fabrication of Custom Pontic Facings
Prothèses partielles fixes conservatrices - incrustations et attaches partiels, pontics individualisés en composite et connecteurs semi-rigides: Partie II Utilisation d'éléments rétentifs additionnels et fabrication de pontics individualisés
By Richard G. Stevenson III, DDS, and Jane A. Refela, DDS

51 Method to Establish Lost Occlusion Plane Using Broadrick Flag: A Review
Méthode pour le rétablissement de la courbe d'occlusion utilisant le drapeau Broadrick
By Dr. Sandeep Garg, MDS, Dr. Sandeep Kumar, and Dr. Aparna Bansal

56 Obstructive Sleep Apnea: Guidelines For Evaluation, Management, and Long-Term Care
Apnée obstructive du sommeil: Directives pour l'évaluation, la gestion et les soins à long terme
By Dr. Savithri Dattatreya – BDS, MDS; Dr. Ravindra C. Savadi, MDS; Dr Malathi Dayalan, MDS; and Dr. Shweta Pradeep Poovani, MDS

Product Profile

61 JRVT Casting Alloy
Alliage pour coulées JRVT
By The Jensen Dental Research and Development Team

63 EXA'lence in Impression Taking
Prise d'empreinte EXA'lence
By Dr. Todd Snyder

Cover image: Toronto, ON

Photo couverture: Toronto, ON

INDICATES PEER REVIEWED/
INDIQUE REVUE DES PAIRS

Canadian Journal of
Restorative Dentistry & Prosthodontics
Journal canadien de
dentisterie restauratrice et de prosthodontie

VOL 4, NO.2 • SUMMER/ÉTÉ , 2011

Official Publication of the Canadian Academy of Restorative Dentistry and Prosthodontics

Publication officielle de L'Académie canadienne de dentisterie restauratrice et de prosthodontie

EDITOR-IN-CHIEF/RÉDACTEUR EN CHEF
Hubert Gaucher
Québec City, Québec | hgaucher@sympatico.ca

ASSOCIATE EDITORS/RÉDACTEURS ASSOCIÉS
Emmanuel J. Rajczak
Hamilton, Ontario | ejrajczak@cogeco.ca
Maureen Andrea
Chester, Nova Scotia | chesterclinicdental@ns.aliantzinc.ca
Dennis Nimchuk
Vancouver, British Columbia | drn@dentalreconstructions.com

SECTION EDITORS/RÉDACTEURS DE SECTION
Occlusion and Temporo-Mandibular Dysfunctions/
Occlusion et dysfonctions temporo-mandibulaires
Kim Parlett
Bracebridge, Ontario | kptooth@muskoka.com
Ian Tester
St. Catharines, Ontario | iantester.cardp@cogeco.ca
Implant Dentistry/Dentisterie implantaire
Ron Zokol
Vancouver, British Columbia | zokol@interchange.ubc.ca
Yvan Fortin
Québec City, Québec | yvan.fortin@gmail.com
Esthetic Dentistry / Dentisterie esthétique
Paresh Shah
Winnipeg, Manitoba | shahp@mymts.net
Dental Technology / Technologie dentaire
Paul Rotsaert
Hamilton, Ontario | paul@rotsaertdental.com

MANAGING EDITOR/
DIRECTEUR DE LA RÉDACTION
Scott Bryant
scottbryant@andrewjohnpublishing.com

CONTRIBUTORS/CONTRIBUTEURS
Randall Allan, Maureen Andrea,
Hugo Ciaburro, Mark Cruz, Hubert Gaucher,
Dan Henry, Todd Snyder

ART DIRECTOR/DESIGN /
DIRECTEUR ARTISTIQUE/DESIGN
Andrea Brierley
abrierley@allegrahamilton.com

SALES AND CIRCULATION COORDINATOR/
COORDONATRICE DES VENTES ET DE LA DIFFUSION
Brenda Robinson
brobinson@andrewjohnpublishing.com

ACCOUNTING / COMPTABILITÉ
Susan McClung

GROUP PUBLISHER / CHEF DE LA DIRECTION
John D. Birkby
jbirkby@andrewjohnpublishing.com

CJRDP/JCDRP is published four times annually by Andrew John Publishing Inc. with offices at 115 King Street West, Dundas, On, Canada L9H 1V1. We welcome editorial submissions but cannot assume responsibility or commitment for unsolicited material. Any editorial material, including photographs that are accepted from an unsolicited contributor, will become the property of Andrew John Publishing Inc.

Feedback
We welcome your views and comments. Please send them to Andrew John Publishing Inc., 115 King Street West, Dundas, On, Canada L9H 1V1.
Copyright 2011 by Andrew John Publishing Inc. All rights reserved. Reprinting in part or in whole is forbidden without express written consent from the publisher.
Individual Copies
Individual copies may be purchased for a price of $19.95 Canadian. Bulk orders may be purchased at a discounted price with a minimum order of 25 copies. Please contact Ms. Brenda Robinson at (905) 628-4309 or brobinson@ andrewjohnpublishing.com for more information and specific pricing.

PUBLICATIONS AGREEMENT NUMBER 40025049
ISSN 1916-7520

Return Undeliverable Canadian Addresses to:



AJPI 115 King Street West, Suite 220
Dundas Ontario L9H 1V1

MESSAGE FROM THE GUEST EDITOR / MESSAGE DE LA RÉDACTRICE INVITÉE

The Road Not Taken / Le chemin non emprunté

In Robert Frost's poem the title is often mistaken for "The Road Less Travelled" and I thought it was an appropriate analogy to the practice of gold. As a member of this ever-changing profession of dentistry, technology is moving us faster than we ever thought possible, but one material remains a constant standard – GOLD. The use of gold in medicine and dentistry dates back 3,000 years ago and was associated with gods, immortality, and health. To examine a healthy dentition restored with gold 45 years ago is an inspiring experience. I have been fortunate to have worked beside some extraordinary restorative clinicians who have made me understand the importance of preservation of tooth structure.

My textbook from dental school *The Art and Science of Operative Dentistry* 2nd Edition, has a chapter introduction written by Dr. Theodore M. Roberson and states "Operative dentistry is the art and science that relates to the diagnosis, treatment and prognosis of those defects of teeth which do not require full coverage for correction; to the restoration of proper tooth form, function and esthetics; and to the maintenance of the physiological integrity of the teeth in harmonious relationship with the adjacent hard and soft tissue; all to enhance the general health and welfare of the patient."[1] In the hands of trained operators, gold restorations fulfill every aspect of this definition.

Dr. Richard V. Tucker, a superstar in our profession, is the consummate mentor. He has passionately changed dentists from all over the world by teaching his techniques for conservative cast gold. I am happy to say I am one of those students! Learning from nurturing and empowering mentors is a common thread of CARDP and many of us have become members of this academy because of the guidance of these mentors. The study club experience is a unique opportunity to develop skill in an interactive setting. All of our authors are either mentors or students of the Academy of Richard V. Tucker Study Clubs and practice the "Tucker Technique."

Dr. Dan Henry focuses on the longevity of gold restorations by discussing the restorative cycle and offers a unique direct restorative alternative to class I and class II lesions. EZ Gold, developed by Dr. Lloyd Baum, is a gold foil wrapped around a mixture of powdered gold and molten wax which enables it to be hand condensed into the cavity preparation.

Dr. Mark Cruz, a past presenter to CARDP, reviews the shift from gold as the standard in restoring the posterior segment from an evidence-based perspective. He offers many scenarios to ensure success in restoring the dentition with gold and impresses the reader of the importance of longevity, comfort, biocompatibility, and consent.

Dr. Randy Allan reviews the aesthetic 7/8 gold crown using the Tucker Technique. Treating a heavily restored upper first molar with an intact MB cusp takes skill and knowledge. Dr. Allan clearly discusses the indications and contraindications for such a case. Treatment planning remains the most important aspect of success.

Dr. Hugo Ciaburro, a past CARDP table clinician, demonstrates an extensive rehabilitation case using gold onlays and partial crowns on a young patient with erosive occlusal loss of tooth structure. This case study exemplifies the properties of gold. The castings do not abrade opposing dentition, the gold allows for great tissue health due to the non-reactive nature, imperceptible margins and high polishability which in turn reduces the accumulation of plaque.

Dr. Richard G. Stevenson III, chair of restorative dentistry at UCLA, considers gold castings as an alternative in restoring a single missing tooth. This reprint is the first part of a 2 part paper

originally published in JERD. Dr. Stevenson comprehensively takes us through rigid and non-rigid connectors in 3 unit bridge cases and demonstrates that minimal thickness of gold maintains occlusal function and esthetics.

As Dr. Tucker tells us, gold castings require considerable care, skill, and technique. Unfortunately many of our dental schools are not teaching castings as part of the restorative curriculum, yet the number of graduated dentists joining Tucker study clubs grow. As a restorative dentist is it our responsibility to ensure that our choices for the patient reflect their expectations. Perhaps there will be a resurgence of the use of gold and this skill is passed to the next generation of practitioners.

"Two roads diverged in a wood, and I – I took the one less travelled by, and that has made all the difference."

References

1. Roberson TM, Heyman H, Swift E. The Art and Science of Operative Dentistry 2nd Edition. Philadelphia: Moseby, 2006.

Le chemin non emprunté / The Road Not Taken

Le titre du poème de Robert Frost ci-haut, traduit de The Road Not Taken, est souvent confondu avec The Road Less Travelled (Le chemin moins emprunté) et je crois que cette erreur s'applique à notre rapport avec l'or. En tant que praticiens de la profession dentaire, la technologie nous pousse plus vite que nous ne l'aurions jamais imaginé. Cependant, un matériau demeure constant – L'OR. L'utilisation de l'or en médecine et en dentisterie remonte à 3 000 ans et était associée aux dieux, à l'immortalité et à la santé. L'expérience d'examiner une dentition saine, restaurée avec de l'or il y a 45 ans, est une source d'inspiration. J'ai eu l'heureux plaisir de côtoyer des cliniciens en restauration extraordinaires qui ont su me transmettre l'importance de la sauvegarde de la structure dentaire.

Le manuel scolaire en Médecine dentaire intitulé The Art and Science of Operative Dentistry (L'art et la science de la dentisterie opératoire, 2ième édition) a un chapitre d'introduction écrit par Dr Theodore M. Robertson dans lequel ce dernier dit: « La dentisterie opératoire est l'art et la science qui se rapporte au diagnostic, au traitement et au pronostic des imperfections dentaires qui, dans le but de les corriger, ne font pas appel au recouvrement complet; à la restauration de la morphologie, la fonction et l'apparence de la dent; et au maintien de l'intégrité harmonieuse des dents dans leur relation avec les tissus durs et mous; le tout en vue de mettre en valeur la santé générale et le bien-être du patient.» Entre les mains d'intervenants aguerris, les restaurations en or rencontrent toutes ces normes.

Le docteur Richard V. Tucker, super vedette de notre profession, est le mentor par excellence. C'est avec passion qu'il a transformé des dentistes de par le monde en leur enseignant ses techniques de coulée en or conservatrice. J'ai le bonheur d'avouer que je suis l'une de ses disciples. L'ACDRP encourage ces apprentissages et plusieurs parmi nous sommes devenus membres de notre Académie grâce aux conseils de telles personnes. L'expérience d'un groupe d'étude offre une occasion unique de développer des aptitudes dans un contexte interactif. Tous nos auteurs sont soit des mentors eux-mêmes ou bien des élèves de groupes d'étude de l'Académie Richard V. Tucker qui pratiquent la «Technique Tucker».

Le docteur Dan Henry se concentre sur la longévité des restaurations en or en discutant du cycle restaurateur et en offrant une alternative directe unique aux lésions du type classe I et II. EZ Gold, développé par Dr Lloyd Baum, est une orification qui enrobe un mélange de poussière d'or et de cire fondue ce qui permet à ce dernier d'être manipulé et condensé dans une préparation de cavité.

Dr Mark Cruz, qui a déjà fait une présentation à l'ACDRP, aborde le déplacement de l'or comme standard dans la restauration de segments postérieurs du point de vue de la dentisterie fondée sur les preuves. Il offre plusieurs conditions afin d'atteindre le succès dans la restauration de la dentition avec l'or et insiste sur la portée de facteurs tels la longévité, le confort, la biocompatibilité et le consentement.

Docteur Randy Allan revoit la couronne 7/8 esthétique en or utilisant la Technique Tucker. Le traitement d'une première molaire du haut hypothéquée avec une cuspide mésio-buccale intacte exige adresse et connaissance. Il discute de façon éclairée des indications et contrindications dans un tel cas, le plan de traitement étant l'aspect essentiel du succès.

Docteur Hugo Ciaburro, présentateur de table pour l'ACDRP, fait la démonstration d'un cas clinique de réhabilitation à l'aide d'incrustations en or et de couronnes partielles sur un jeune patient en perte de structure dentaire due à l'érosion occlusale. Cette étude de cas témoigne des propriétés de l'or. Les restaurations ne causent pas d'abrasion aux dents antagonistes, l'or favorisant la santé des tissus du à sa nature non-réactive, à la margination imperceptible et son haut niveau de polissage qui, en revanche, réduisent l'accumulation de plaque.

Docteur Richard G. Stevenson III, chef de la dentisterie restauratrice à UCLA, fait valoir les coulées en or pour restaurer une seule dent manquante. Cette ré-impression constitue la première partie d'un document en deux parties publié à l'origine dans JERD. Dr Stevenson détaille des cas de ponts de trois unités aux connecteurs rigides et semi-rigides et démontre qu'une épaisseur minimale d'or maintient les fonctions occlusale et esthétique. Comme dit le Dr Tucker, les coulées en or exigent beaucoup de soin, d'adresse et de technique. Malheureusement, plusieurs de nos écoles dentaires n'enseignent plus les restaurations coulées dans leur curriculum; pourtant le nombre de dentistes qui se joignent aux groupes d'étude Tucker augmente. En tant que dentistes de la restauration c'est notre obligation d'assurer au patient que nos choix reflètent leurs attentes. Peut-être y aura-t-il un renouveau d'intérêt pour l'or si nous transmettons nos connaissances à la prochaine génération de praticiens.

The Canadian Academy of Restorative Dentistry and Prosthodontics
l'Académie canadienne de dentisterie restauratrice et de prosthodontie

19TH ANNUAL SCIENTIFIC MEETING
SEPTEMBER 22-24, TORONTO, ONTARIO
19IÈME CONGRÈS ANNUEL
22-24 SEPTEMBRE, TORONTO, ONTARIO

"The Pursuit of Excellence"

2011
Conference Program

Programme du congrès

« La poursuite de l'excellence »

ADA C·E·R·P®
Continuing Education Recognition Program

Academy of General Dentistry
PACE
Program Approval for Continuing Education

Thanks for the Generous Support of All Our Sponsors!
Merci à tous nos généreux commanditaires!

Silver Sponsors

HeartFriendly Dentist

Dental Professionals against
Heart Disease and Diabetes

Bronze Sponsors

Contributing Sponsors

Trade Show Floor Plan Page 16

Table of Contents
Table des matières

Meeting Sponsors	**Page 7**
Welcome Message from CARDP President	**Page 8**
Conference Chair Welcome	**Page 8**
Convention & Social Activities	**Page 9**
Hands On Course	**Page 9**
Scientific Program Schedule	**Page 10**
Convention Program	**Page 11**
Toronto Royal York Hotel Floor Plan	**Page 12**
Friday Speakers	**Page 13**
Saturday Speakers	**Page 14**
Table Clinic Program & Floor Plan	**Page 15**
CARDP Executive & Committees	**Page 15**
Sponsor Trade Show Floor Plan & Past Presidents	**Page 16**
2012 CARDP Scientific Meeting Announcement	**Page 17**

Welcome Message from the CARDP President

As President of CARDP it is a great honour for me to be able to host our annual meeting in the great city of Toronto! Special thanks are due to Dr Cary Letkemann our Convention Ch air and Dr Emo Rajczak, Scientific program chair for putting together what I'm sure will be one of our best events yet.

The Royal York Hotel provides a great backdrop for our meeting. Family and friends can enjoy the great atmosphere of this truly grand old hotel. The hands on course with Dr Tanaka has been oversubscribed. The excursions for partners whether sailing on Lake Ontario or touring the McMichael Gallery always prove to be great fun. I urge you to sign up early to avoid disappointment and get out to meet old friends and make new ones. The Scientific Program this year will not disappoint. There is something for everyone and lots of take home material for Monday morning back at the office. Be sure to take the time to visit the table clinics on Saturday afternoon. It is your chance to get up close to leading clinicians for one on one presentations. These presentations are unique to CARDP meetings and are not to be missed.

Plan to stay over Saturday evening and attend our annual Presidents Party. This year we have changed the format slightly by deciding to go a little less formal." black tie" is no longer required as we hope to attract a greater number of members and guests. The 905 Dance band is first rate, the food is always superb, The Imperial Room is a fabulous venue for a gala event such as this. Come out and join us. I can promise you a great evening! Looking forward to seeing you in TO!

Sincerely
Dr. Kim G. Parlett

Welcome Message from the Conference Chair

As Convention Chair, it is my great pleasure to welcome you to our 19th Annual Scientific Meeting of the Canadian Academy of Restorative Dentistry and Prosthodontics being held in the beautiful city of Toronto. This years meeting, held at the prestigious Fairmont Royal York Hotel, will offer a superb setting for our Scientific Sessions and Social Activities. Being the only national dental organization dedicated to all aspects of restorative dentistry and prosthodontics, our Academy will showcase over the coming days an illustrious gathering of presenters and leading edge topics in the *"The Pursuit of Excellence"*.

We are very pleased that our hands-on course, which will feature the eminent Dr. Terry Tanaka presenting "Ethics and Occlusion, sold out in days. This forced us to add an additional Wednesday course which also sold out. On Friday, the heart of the Scientific Program will showcase 6 one-hour essayist presentations by such speakers as Dr. Terry Tanaka, Dr. Jay Gibson, Dr. Terry Donovan, Dr. John Davies, Dr. Winston Chee and Dr. Daniel Melker, covering a variety of topics. Saturday is the 'meat and potatoes' of the meeting. The morning will headline 8 eighteen-minute clinical presentations and the afternoon is dedicated to table clinics with a wide range of hands-on presentations showing techniques that you can take back to the office and start using Monday morning.

I look forward to meeting everyone at the Welcome Reception hosted at the Royal York. Great food, cocktails, light entertainment and the opportunity to mingle with friends, colleagues and exhibitors make this a convivial occasion. For the partner's joining us we hope you'll enjoy the Explore Toronto Program designed to entertain and delight. Then the evening will be free for us to explore the incredible selection of restaurants and entertainment that Toronto offers. We hope you'll join us for our finale, the President's Party, including a champagne reception, fine dining and dancing to the 905 Band, one of Canada's foremost party bands. Plan on attending because you wouldn't want your friends to tell you what a great time you missed. I look forward to seeing and meeting everyone over the next few days.

Dr. Cary Letkemann
Convention Chair

Convention & Social Activities
Convention & Social Activities / Congrès et activités sociales

Sailing on Lake Ontario
Thursday, September 22, 11:00 am – 4:00 pm
Meet in Royal York Lobby @ 10:45 am (Dress Warm, Casual)
Visit: www.toronto.ca

Conference Registration - Toronto, Royal York Hotel
Thursday, September 22, 11:00 am – 8:00 pm
Friday, September 23, 7:00 am—5:00 pm
Saturday, September 24, 7:00 am—Noon
Ballroom Foyer – Conference Level

Hands on Course - Toronto, Fairmont Royal York Hotel
Wednesday, September 21, 9:00 am - 5:00 pm
Thursday, September 22, 9:00 am - 5:00 pm
"Esthetic and Occlusion Guidelines" Presented by Dr. Terry T. Tanaka, D.D.S.
Salon A - Conference Level

Opening Reception - Welcome Buffet - Toronto, Fairmont Royal York Hotel
Thursday, September 22, 6:00 pm – 10:00 pm
Ballroom, Conference Level

Partner's Program - A Toronto Adventure!
Friday, September 23, 9:00 am – 4:00 pm
Mc Michael Canadian Art Collection – Luncheon & Yorkville Shopping
Meet in Royal York Lobby @ 8:45 am (Dress Warm with Comfortable Shoes)
For more info, please visit: www.toronto.ca/
And www.mcmichael.com

Free Night!
Friday, September 23
Time to experience Toronto's Dining and Entertainment Scene
Visit: www.toronto.ca/

President's Party, Toronto , Fairmont Royal York Hotel
Saturday, September 24, 6:30 pm – 12:00 am
Reception, Imperial Room - Lobby Level
Dinner Dance Party - Imperial Room

Average Temperature for Toronto, ON - September = High 20.6°C Low 9°C

Hands on Course - *"Esthetic and Occlusion Guidelines"*

Presented by Dr. Terry T. Tanaka, D.D.S.

Wednesday, September 21, 9:00 am - 5:00 pm & Thursday, September 22, 9:00 am - 5:00 pm
"Salon A - Conference Level, Fairmont Royal York Hotel

Synopsis: Dr Tanaka has published numerous articles and is widely recognized as a research anatomist and for his teaching of advanced restorative procedures. He is highly sought after as a speaker throughout the world, and is known for his exciting presentations and outstanding clinical skills. His educational videotapes on TM Dysfunction, Anatomy and Implants are used in over 80 medical and dental schools and surgery programs throughout the world.

YOU WILL LEARN:

- **How to perform a "Comprehensive Examination" and the "Functional Analysis".**
- **Why a clear understanding of "masticatory function" is vital when treatment planning esthetic restorations.**
- **Guidelines for the "management of occlusal forces". "Who clenches with the greatest forces and when".**
- **How the above information determines your choice of restorative materials?**
- **What is your role in interacting with specialists. What should you know as the referring dentist?**
- **When is it possible to treat "one tooth at a time" and when mounted cases are necessary?**
- **Guidelines for determining anterior tooth length in patients with worn incisors.**
- **How anterior tooth wear and the Curve of Spee are related in esthetic procedures.**
- **Guidelines for altering the Occlusal Vertical Dimension: when and how?**

****Bring your Cameras & Light and you will learn to make Digital "Case Presentations"***

Academy of General Dentistry PACE Program Approval for Continuing Education

ADA C·E·R·P® Continuing Education Recognition Program

CARDP Scientific Program
Programme scientifique de l'ACDRP – Fairmont Royal York Hotel

	Wednesday, September 21st & Thursday, September 22nd
9:00 am - 5:00 pm	Hands on Course - "Esthetics and Occlusion " Terry T. Tanaka, D.D.S.
	Friday, September 23rd
8:15 am	Dr. Kim Parlett – CARDP President
8:19 am	Dr. Cary Letkemann – Conference Chair
8:23 am	Dr. Emanuel Rajczak – Scientific Program Chair
8:26 am	Dr. Ian Tester – Clinic Chair
8:30 am	Anatomical and Restrative Complications in Implant Dentistry Terry Tanaka D.D.S.
9:30 am	The Use of Mini-Implants for Orthodontic Anchorage in Pre- Prosthetic Movement Jay Gibson B.Sc., D.D.S.
10:30 am - 11:00 am	Refreshment Break with Sponsors – Exhibit Hall
11:00 am	The Therapeutic Promise of Mesenchymal Stem Cells John E. Davies BDS, PhD, DSc
12:00 Noon - 1:30 pm	Luncheon with Sponsors – Exhibit Hall
1:30 pm	Recognition, Management and Prevention of Dental Erosion Terry E. Donovan D.D.S.
2:30 pm	Occlusion as it relates to Implant Supported Structures Winston W.L. Chee D.D.S.
3:30 pm - 4:00 pm	Refreshment Break with Sponsors – Exhibit Hall
4:00 pm - 5:00 pm	The TEAM Approach to Comprehensive Periodontal and Restorative Treatment Daniel Melker D.D.S.
	Saturday, September 24th
8:30 am - 8:50 am	Treatment of Atypical Dental Development using Contemporary Fixed Telescopic Dental Prostheses Oliver C. Pin Harry D.D.S.
8:50 am - 9:10 am	Restoring Incisal Attrition with Composite Resin Peter Walford D.D.S.
9:10 am - 9:30 am	Periodontal Radiography Peter Fritz B.Sc, D.D.S., PhD (Perio)
9:30 am - 9:50 am	Periodontal Disease Classification and Accepted Treatment Daniel Zeiter D.D.S.
9:50 am - 10:30 am	Refreshment Break with Sponsors – Exhibit Hall
10:30 am - 10:50 am	Ridge Preservation: A key step for Implant Rehabilitation Alexandre Taché D.D.S.
10:50 am - 11:10 am	Parafunctional Analysis-A Diagnostic & Therapeutic Metric in Orthotic Therapy Michael Melkers D.D.S., FAGD
11:10 am - 11:30 am	Immediate Extraction, Implant Placement and Provisionalization in the Anterior Maxilla Using the Patient's Natural Tooth Robert Margeas D.D.S.
11:30 am - 11:50 am	Prevention & Management of Root Caries Terry E. Donovan D.D.S.
11:50 am - Noon	Meeting Conclusion, Dr. Kim Parlett & Dr. Maureen Andrea
12:00 Noon - 2:00 pm	CARDP Members Luncheon
2:00 pm -5:00 pm	Table Clinics

CARDP Conference Program - Fairmont Royal York Hotel
Programme scientifique de l'ACDRP – Fairmont Royal York Hotel

TIME		DATE & EVENT	LOCATION
		Wednesday, September 21, 2011	
9:00 AM	5:00 PM	Hands On Course	Salon A
6:30 PM	11:00 PM	CARDP Executive Dinner Meeting	Salon III
		Thursday, September 22, 2011	
11:00 AM	4:00 PM	Sailing on Lake Ontario	Meet in Lobby of Hotel 10:45 am
9:00 AM	5:00 PM	Hand's on Course	Salon A
12:00 AM	11:59 PM	Scientific Set-up	Concert Hall
8:00 AM	6:00 PM	Trade Show Set-up	Ballroom
11:00 AM	8:00 PM	Registration	Ballroom Foyer
6:00 PM	10:00 PM	Opening Reception with Sponsors	Ballroom
		Friday, September 23, 2011	
7:00 AM	5:00 PM	Registration	Ballroom Foyer
7:00 AM	8:30 AM	Breakfast with Sponsors	Ballroom
8:30 AM	5:00 PM	Scientific Session	Concert Hall
9:00 AM	4:00 PM	Partner's Program	Meet in Lobby of Hotel 8:45 am
10:30 AM	11:00 AM	Break with Sponsors	Ballroom
12:00 PM	1:30 PM	Lunch with Sponsors	Ballroom
3:30 PM	4:00 PM	Break with Sponsors	Ballroom
5:00 PM	10:00 PM	APC Board Meeting	Algonquin
		Free Night	On Own
		Saturday, September 24, 2011	
7:00 AM	12:00 PM	Registration	Ballroom Foyer
7:00 AM	8:30 AM	Breakfast with Sponsors	Ballroom
7:00 AM	8:30 AM	CARDP Member Breakfast	Tudor 7 & 8
7:00 AM	8:00 AM	APC Member Breakfast	Salon A
8:30 AM	12:00 PM	Scientific Sessions	Concert Hall
9:50 AM	10:30 AM	Break with Sponsors	Ballroom
12:00 PM	2:00 PM	CARDP Lunch	Tudor 7 & 8
2:00 PM	5:00 PM	Table Clinics	Upper Canada Room 18th Floor
6:30 PM	7:30 PM	President's Reception	Imperial Room Foyer
7:30 PM	12:00 PM	President's Party - Dinner Dance	Imperial Room
		Sunday, September 25, 2011	
9:00 AM	12:00 PM	Clinic and Essay Meeting	British Columbia Room

Fairmont Royal York Hotel Layout

MAIN MEZZANINE FLOOR

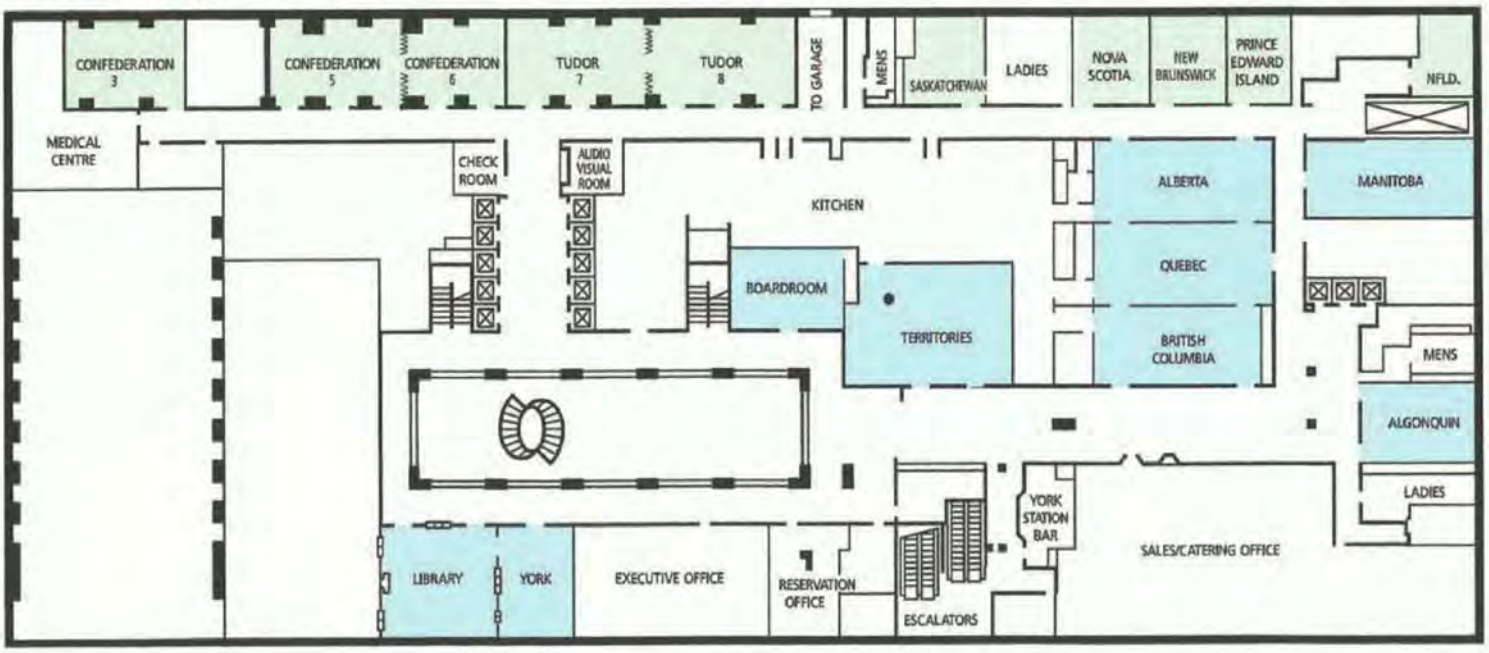

CONVENTION FLOOR

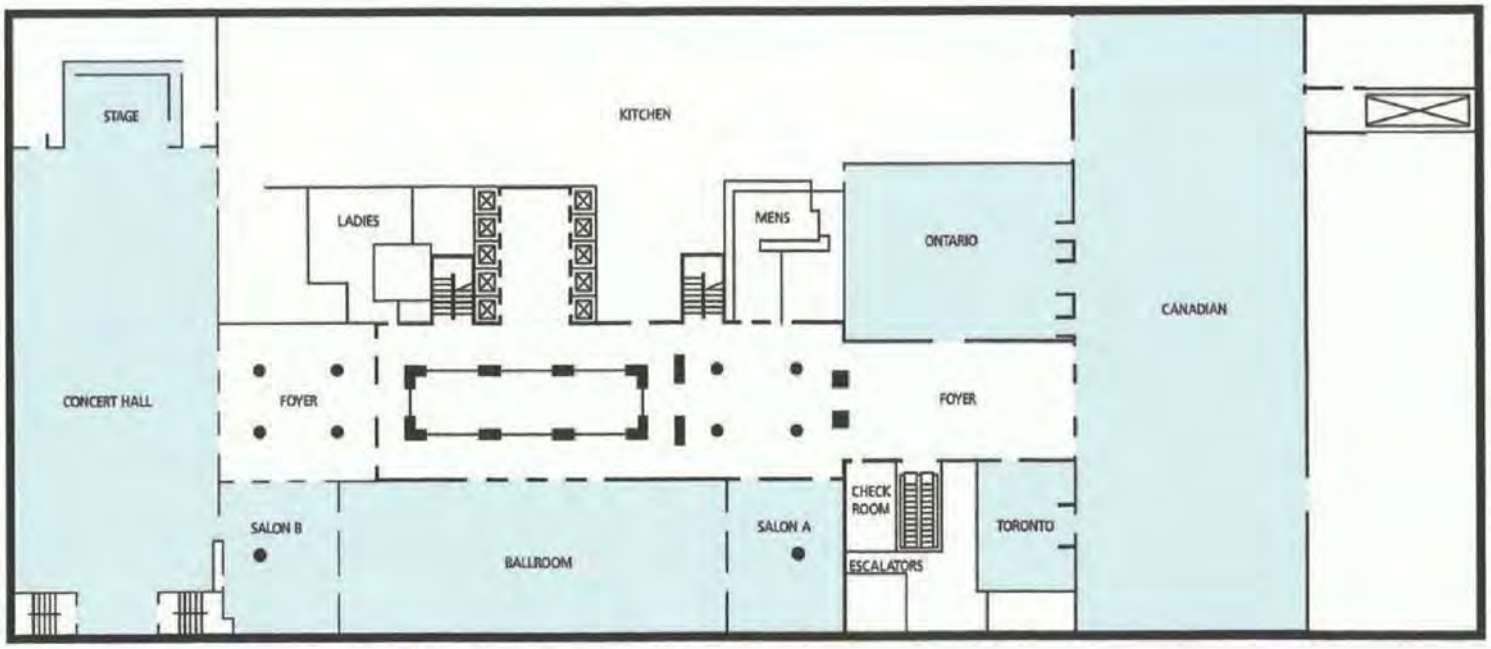

David Alexander & Glenn Richardson
Canadian Academy of Restorative Dentistry & Prosthodontics
Administration
P.O. Box 665
Dartmouth, NS
B2Y 3Y9

Ph: 902-435-1723
Fax: 902-484-6926
E-Mail: info@cardp.ca
Web: www.cardp.ca

ADA C·E·R·P
Continuing Education Recognition Program

Academy of General Dentistry
PACE Program Approval for Continuing Education

Scientific Program Credits

Wednesday or Thursday Hands On Course - 7 CE Credits
Friday Scientific Sessions - 8.5 CE Credits
Saturday, Scientific Sessions - 3.5 CE Credits
Saturday Table Clinics - 3 CE Credits

The Academy of General Dentistry designates Ontario AGD as an Approved PACE Program Provider. The formal continuing dental education programs of this program provider are accepted by AGD for Fellowship/Mastership and membership maintenance credit. Approval does not imply acceptance by a state or provincial board of dentistry or AGD endorsement. The current term of approval extends from 06/01/2007 - 12/31/2014.

Speakers, Friday, September 23rd
Conférenciers, vendredi le 23 septembre

Terry T. Tanaka, D.D.S

Anatomical and Restorative Complications in Implant Dentistry

Learning Objectives:

1. A critical review of the intra-oral anatomy involved in implant surgery
2. How to recognize and manage arterial and venous bleeding. (or Dial 911)
3. How accurate cone beam ct (iCat), is at different resolutions in reproducing hard tissue.

Jay Gibson B.Sc., D.D.S.

The Use of Mini-Implants for Orthodontic Anchorage in Pre- Prosthetic Movement

Learning Objectives:

1. Which types of orthodontic tooth movement are greatly facilitated by intraoral skeletal anchorage systems.
2. How intraoral skeletal anchorage and orthodontic treatment can simplify complex restorative problems.
3. Treatment planning guidelines for tooth movement ranges when utilizing intraoral skeletal anchorage systems

---

John E. Davies Bds, PhD, Dsc

The Therapeutic Promise of Mesenchymal Stem Cells

Learning Objectives:

1. The essential facts about stem cells and how they are vital to our everyday lives.
2. The role of mesenchymal stem cells (MSC) in wound healing tissue regeneration.
3. The promise of using MSC as drugs to treat disease.

Terry E. Donovan D.D.S.

Recognition, Management and Prevention of Dental Erosion

Learning Objectives:

1. Recognize the clinical signs of chemical erosion at an early stage and implement the appropriate preventive strategies.
2. Understand that the location and pattern of erosive tooth wear provides important clues regarding the specific etiology.
3. Implement specific prevention and treatment protocols for patients with bulimia and GERD.

Winston W.L. Chee D.D.S.

Occlusion as it relates to Implant Supported Structures

Learning Objectives:

1. Understand the difference between implants and teeth with respect to occlusion
2. Be able to make a choice as far as restorative materials for implant supported restorations on a patient driven basis
3. Decide on form of restorations with an evidence base

Daniel Melker D.D.S.

The TEAM Approach to Comprehensive Periodontal and Restorative Treatment

Learning Objectives:

1. Restorative Dentists will learn what is necessary to give the Periodontist an ideal foundation to do definitive surgical procedures for an ideal outcome periodontally.
2. Periodontists will learn what is needed of them to create an definitive foundation for ideal Restorative treatment.
3. The TEAM approach will be stressed to create long term stability of compromised Periodontal and Restorative cases.
4. Surgical techniques will be discussed as an alternative to conventional crown lengthening where by preservation of tooth support can occur.

PACE

ADA C·E·R·P Continuing Education Recognition Program

Speakers, Saturday, September 24th
Conférenciers, samedi le 24 septembre

Oliver C. Pin Harry D.D.S.

Anatomical and Restorative Complications in Implant Dentistry Treatment of Atypical Dental Development using Contemporary Fixed Telescopic Dental Prostheses

Learning Objectives:

1. Recognizing dental anomalies associated with AI
2. Steps involved in diagnosis and treatment planning of a complex AI case.
3. Concept of a telescopic fixed prosthesis on natural teeth
4. Merging conventional diagnostic wax-up and Provisionalization with copy-milling of a definitive zirconia prosthesis.

Peter Walford D.D.S.

Restoring Incisal Attrition with Composite Resin

Learning Objectives:

1. Preparation designs and instrumentation
2. Criteria for successful resins
3. Precautions and common errors
4. Integration into regular practice

Peter Fritz D.D.S., PhD

Periodontal Radiography

Learning Objectives:

1. To diagnose periodontal prognoses of individual teeth through radiographic interpretation.
2. Review the different classifications of osseous defects.
3. Review criteria which help determine the long term outcome of teeth with furcation involvement.

Daniel Zeiter D.D.S.

Periodontal Disease Classification and Accepted Treatment

Learning Objectives:

1. Understand the diagnosis of periodontal diseases.
2. Understand the available treatments for each disease category.
3. Be able to determine the long term results for each treatment

---

Alexandre Taché D.D.S.

Ridge Preservation: A key step for Implant Rehabilitation

Learning Objectives:

1. Understand the remodeling of the alveolar process following dental extraction
2. Understand the goals and the advantages of bone grafting at the time of extraction
3. Techniques of bone grafting for intact and damage alveolar sites after extraction

---

Michael Melkers D.D.S.

Parafunctional Analysis-A Diagnostic & Therapeutic Metric in Orthotic Therapy

Learning Objectives:

1. Be exposed to a cost effective method for measuring parafunctional activity
2. Become aware of the potential differences between parafunction and voluntary ROM
3. Appreciate the consequences of prematurely proceeding with diagnostic and/or restorative care

---

Robert Margeas D.D.S.

Immediate Extraction, Implant Placement and Provisionalization in the Anterior Maxilla Using the Patient's Natural Tooth

Learning Objectives:

1. How to use the patients tooth as a provisional following implant placement
2. When to provisionalize immediately following extraction
3. How to easily reline the natural tooth for maximum fit 4.the benefits of immediate Provisionalization

---

Terry E. Donovan D.D.S.

Prevention & Management of Root Caries

Learning Objectives:

1. Understand the etiology of root caries and identify patients who are at high risk for root caries.
2. Have 2 different preventive protocols to use with patients at high risk for root caries.
3. Be able to choose the appropriate materials for restoration of root caries lesions.

ADA C·E·R·P
Continuing Education Recognition Program

TABLE CLINICS / PRÉSENTATIONS CLINIQUES
UPPER CANADA ROOM (18TH FLOOR)

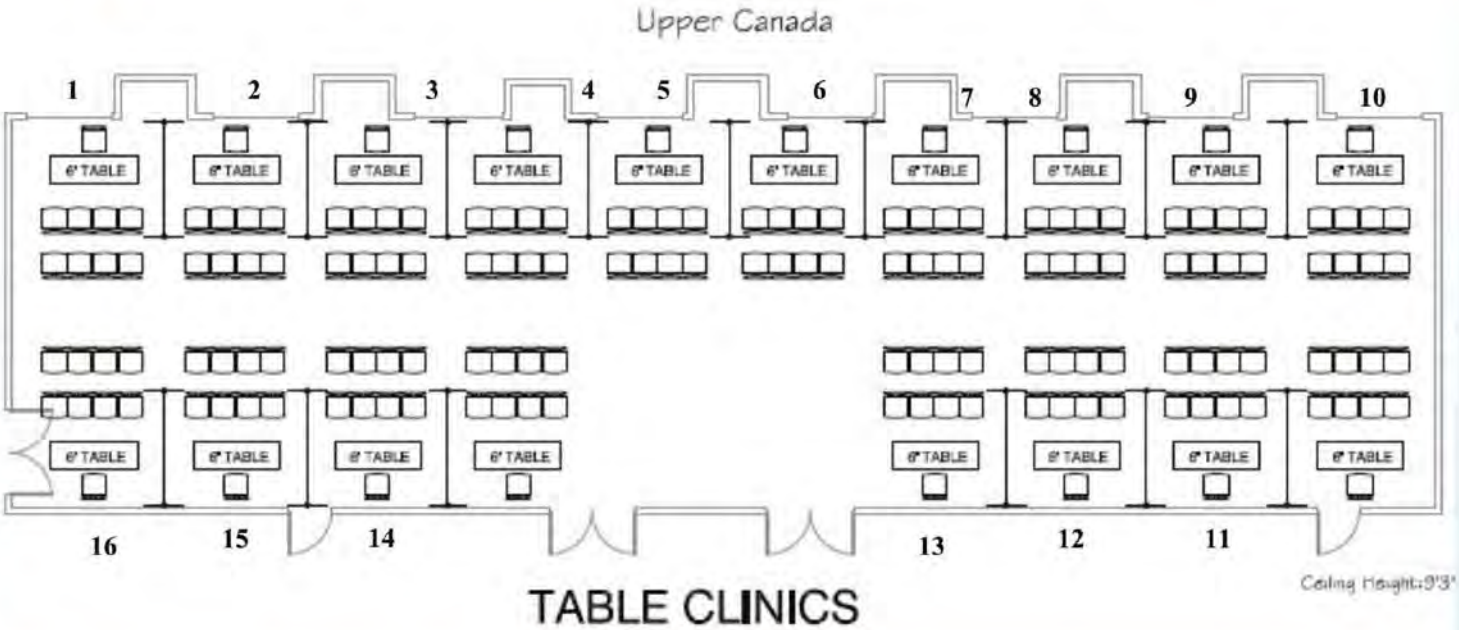

1. Dr. Peter Fritz — Regeneration Using Microsurgery
2. Dr. Peter Walford — An Effective New Cast Periodontal Splint
3. Dr. Tony Mancuso — Predictable and Efficient Provisionalization of the Anterior Aesthetic Case
4. Dr. Terry Koltek — In Office Splints
5. Mr. Paul Rotsaert — Coordinating Attachment Cases
6. Dr. John Pepper — Articulated Custom Impression Tray
7. Mrs. Kim Misener Hilson — The Business Of Dentistry - Thinking Outside The Box
8. Dr. Adrian Palencar — Intrusion And Up Righting Teeth With Temporary Anchorage Device
9. Dr. Daniel Zeiter — A Traumatic Extraction
10. Dr. Alex Koranyi — Pre And Post Operative Pain Management
11. Dr. Robert Margeas — Immediate Extraction, Implant Placement And Provisionalization In The Anterior Maxilla Using The Patients Natural Tooth
12. Dr. Michael Melkers — Parafunctional Analysis In Diagnostic & Restorative Dentistry
13. Dr. Christian Von Rosenbach — Vital Signs Measurement: A Paradigm Shift In Patient Screening And Monitoring Using Newly Developed Canadian Technology And Software
14. Nobel Biocare — CAD/CAM
15. University of Toronto — TBA
16. University of Western Ontario — TBA

CARDP Executive & Committees / ACDRP Exécutif et comités

CARDP Conference Committee

Conference Chair
Dr. Cary Letkemann

Essay Committee Chair
Dr. Emmanuel Rajczak

Clinic Committee Chair
Dr. Ian Tester

Local Arrangements Chair
Dr. David Cowan

Corporate Liaison
Dr. Larry Pedlar

CARDP Officers

President
Dr. Kim Parlett

President-Elect
Dr. Maureen Andrea

Vice President
Dr. Ashok Varma

Secretary-Treasurer
Dr. Les Kallos

Past-President
Dr. Vernon Shaffner

CARDP Council

Atlantic Provinces - Dr. Scott Maclean

Quebec/Nunavut - Dr. David Blair

Ontario - Dr. Izchak Barzilay

Manitoba/Saskatchewan
Dr. Terry Koltek

Alberta/NWT
Dr.Richard Beauchamp

BC/Yukon - Dr. Myrna Pearce

ADA C·E·R·P
Continuing Education Recognition Program

Sponsor Trade Show
Exhibits Commandités

CARDP SPONSOR TRADE SHOW - ROYAL YORK HOTEL
SEPTEMBER 22-24, 2011
BALLROOM



BOOTH #	COMPANY
# 1	Southern Implants
# 2	Bisco Dental Products Canada Inc.
# 3	Vident, a VITA Company
# 4	3M Espe
# 5	PRO-ART Dental Labs
# 6	Straumann
# 7	Rotsaert Dental Labs
# 8	Biomet 3i Canada
# 9	Aurum Ceramic/Classic
# 10	Henry Schein
# 11	Nobel Biocare
# 12	Dentsply
# 13	BIOANALYTICS INC.
# 14	Discus Dental
# 15	Astra Technologies Inc.
# 16	Thommen Medical Canada Inc
# 17	Patterson Dental

PAST PRESIDENTS / PRÉSIDENTS SORTANTS

Canadian Academy of Restorative Dentistry and Prosthodontics

Vernon Shaffner	2010
Stanley Blum	2009
Mike Racich	2008
Dennis Nimchuk	2007
Gorman Doyle	2006
Alan Osborn	2005
William H. Sehl	2004
Cary D.L. Letkemann	2003
Brian Friesen	2002
Hubert Gaucher	2001
Bernard Linke	2000
Robert J. David	1999
Michael R. Roda	1998
Edward McIntyre	1997
Allan R. Mills	1996
Graham G. Matheson	1995
Anthony H. Sneazwell	1994
George K. Scott	1993

Canadian Academy of Prosthodontics

Dennis P.A. Nimchuk	1992
Carl J. Osadetz	1991
David H. Charles	1990
Nasser Diabi	1989
Bruce M. Jackson	1988
Harry L. Gelfant	1987
Emmanuel J Rajczak	1986
Robert Hoar	1985
Andrew Tynio	1984
Michael W. Balanko	1983
Paul S. Sills	1982
Paul Jean	1981
Leon A. Richardson	1980
Arthur H. Irvine*	1979
Richard C. McLelland	1978
Francoise Michaud*	1977
Herbert Ptack	1976
Douglas V. Chaytor	1975
Georges A. Zarb	1974
W. Brock Love	1973
Jacques Fiset*	1972
A. Harris Crowson	1971
Donald Kepron	1970
Jean Nadeau	1969
Alan D. Fee	1968
William G. Woods	1967
Kenneth M. Kerr*	1966
James E. McCutheon*	1965
Wilfred D. Clark* (Charter Mtg)	1964
Charles H. Moses*	1963
R. Lawrence Twible*	1962

Canadian Academy of Restorative Dentistry

Craig Naylor	1992
Ernest R. Ambrose	1991
Leonard L. Kahane	1990
Andrew Tynio	1989
Stanley S. Kucey	1988
Vernon B. Shaffner	1987
Daniel C.T. MacIntosh	1986
Edward J. Abrahams	1985
Berl L. Mendelson	1984
J. Ivan Johnson	1983
B. Larry Pedlar	1982
Norman C. Ferguson	1981
E.S. Morrison	1980
Earl V. Gowda	1979
George K. Scott	1978
Owen J. Yule*	1977
Robert B. Telford	1976
Robert A. Clappison	1975
Emmanuel J. Rajczak	1974
Walter V. Grenkow*	1973
Douglas H. MacDougall	1972
D. Blake McAdam	1971
Sidney R. Katz*	1970
Jacques Fiset	1969
William R. Scott	1968
James D. Purves*	1967
J. Rod Fraser	1966
Harry Rosen	1965

CARDP
ACDRP

See You Next Year!

CARDP
ACDRP

2012 Annual Scientific Meeting

September 6TH – 8th, Halifax, Nova Scotia

CARDP
ACDRP

Congrès annuel 2012

ADA C·E·R·P
Continuing Education Recognition Program

6 au 8 Septembre, Halifax, Nouvelle-Écosse

12

The Restorative Cycle in Dentistry
Le cycle restaurateur en dentisterie

By Dr. Dan B. Henry, DDS, FACD, FICD

About the Author

Dr. Dan Henry practices in Pensacola Florida, graduated from Dental School at the University of Maryland in 1975. He was past president of the Florida Dental Association and is an active member of the AAGFO, AOD, and a fellow of the ACD and ICD.

ABSTRACT

The replacement of failed restorative dentistry continues to be a major part of operative dental procedures performed in the US and Canada. In addition, dental continuing education tends to concentrate on technical procedures with little emphasis on the long term outcomes for restorative choices. The choice of restorative materials combined with the operator's skill level has a profound influence on the life expectancy of a restoration. How long a restoration will last has direct consequences on oral health.

This paper will discuss the importance of selecting restorative materials that are most survivable within the environment into which they are placed. The clinical relevance for the use of direct gold, especially in younger patients or in virgin caries will be presented. In addition, the article is intended to present the advantages for oral health of placing restorative materials with the highest probability of long-term success in various environments.

Restorative dentistry is an invasive and irreversible procedure that has a finite life. Therefore, possibly the most significant consequence for the repair of dental defects and indeed for all operative interventions is the need to replace restorations when they fail.[1-4] The unintended consequence for all operative procedures is to place the patient's tooth and/or the tooth site into a "restorative cycle" that will continue throughout the life of the patient. The fundamental concept of a restorative cycle brings into focus the loss of tissue around existing restorations on a recurring basis.

The restorative cycle consist of three major events; first the loss of tooth structure due to trauma or the initial disease process. Next is the loss of tooth structure due to the necessary process of preparing a tooth to receive a restoration. The final event occurs when the restoration fails and must be replaced. With the replacement restoration the restorative cycle is repeated. All restorative options are subject to restorative cycles. Add to this the human tendency to settle into routines, where the average dentist gives little thought, other than colour, to the material chosen, and even less thought to the "environment" into which that material is to be placed and the restorative cycle is accelerated.

There are a number of factors that determine the length of the restorative cycle for any given restorative material. These include the environment into which the restorative material is to be placed. For example, the age and health of the patient, diet, the occlusal loads

Figure 1

Figure 2

Figure 3

Figure 4

brought by the patient, oral hygiene, plaque levels, and the type and levels of bacteria within the oral environment of the patient. Physical properties of the restorative material and the skill level of the operator, at the time of placement, also contribute to the how long a restoration will last until it ultimately fails.

This fundamental understanding of the finite life for all restorative procedures as they relate to the environment the patient presents should be one of the determining factors for which restorative material will be best to use in any particular restorative situation. Therefore any attempt to quantify the predicted life of a restoration should help dentists and patients make informed decisions about restorative options.

Review of the literature.[2,6] and through personal observations from 30+ years of restorative practice, it is the understanding of the author that posterior composite restorations, in general, have a life expectancy of 6–10 years. Therefore the restorative cycle assigned to posterior composites would be 6–10. Similarly a restorative cycle of 12–18 would be assigned to alloy restorations. Cast gold would have a restorative cycle of 30–40, and gold foil/direct gold would have a RC of 45–55. In addition, this refers to first generation restorations. Second generation restorations, on average, would have restorative cycles shorter than first generation restorations due to an increase in the size of the restoration and greater loss of tooth structure leading to a weaker tooth less able to stand up to stresses within the mouth. In addition, changes in the "environment," ageing of the patient, changes in eating habits, systemic disease processes, un-noticed iatrogenic flaws, to name a few, will have direct influences on the life of restorations. clinical cases:

The restorative cycle and its effects clinically can be better understood by the following cases. The first case (Figures 1–10) is virgin caries in a patient in his mid 50s. The patient is in good health and demonstrates good home care with a low caries rate. The patient will need the restoration to possibly last 45+ years, thus a restorative material with an RC of 6–10 or even 12–18 will be insufficient. Restorations with longer restorative cycles will better serve the needs of the patient.

Because this is a first-time restoration where the occlusal load will not be directed on the restoration and cosmetic concerns are low

Figure 5

Figure 6

Figure 7

Figure 8

Figure 9

Figure 10

Figure 11

Figure 12

Figure 13

Figure 14

either a gold casting or direct gold would work well. Direct gold/gold foil was chosen to allow for a conservative preparation without having to flair the prep in order to place an indirect casting. In addition, due to the depth of caries a base of Fuji IX was placed.

The use of EZ gold, developed by Lloyd Baum from Loma Linda, allows for placement of a direct gold restoration of this size in a reasonable amount of time within a busy restorative practice. Another advantage of direct gold is that the restoration can be placed in one appointment without a lab fee. The prep design can be kept conservative without having to extend the proximal cavo-surface margins to accommodated for casting placement and finishing. Finally the restoration has a very good chance of lasting 50 years in the environment in which it is placed.

The next case (Figures 11–14) is interesting on several levels. First due to the age of the patient, the decision for what restorative material to use will have a profound influence on the future health of the tooth and tooth site. Another issue concerns who is doing what and when. The environment is as follows; the patient is 10 years old with caries into the dentin of the mesial pit of his 6 year molar. The patient has good oral hygiene with a low caries rate. The patient is a bright energetic young man with a good understanding of oral health and has the ability to undergo a procedure that will take approximately 45 minutes under a rubber dam. The author wishes to interject here that this is a situation that should be addressed further by everyone. Even though it might sound counter intuitive, in the author's opinion, pediatric dentists should be doing direct gold restorations. It has been a personal observation that when patients leave the pediatric dental practice and come into a general restorative practice, a lot of the 6 and 12 year molars have composite restorations. A significant number of these restorations are failing with others not long behind. The problem with this situation is this; a real opportunity to treat the patient with optimal care has been lost. Therefore, in the opinion of the author direct foil should be taught in pediatric residencies. If the receiving restorative dentist acquires the patient with a direct gold restoration in the posterior teeth, there is a good chance that future

Figure 15

Figure 16

Figure 17

Figure 18

Figure 19

Figure 20

Figure 21

Figure 22

replacement restorative work would be more manageable for long term health of the patient and retention of the tooth.

This case is a good example of this situation. Because this 10 year old has a restoration with a restorative cycle of 50+ placed, there is a good chance that the molar will remain intact, without need for full coverage and/or root canal therapy, for the remainder of the patient's life. Another point that should be made at this point is this. Predictions for future success and/or failure for restorative materials can only be made on current conditions and past known history of the environment. Assuming conditions will remain the same, good hygiene and health, predictability of restorative materials should remain consistent.

The next case (Figures 15–20) is that of virgin caries on a patient in their late 30s. Again, the environment is that of a younger patient with good oral hygiene and low caries rate with a good understanding of excellence in dentistry and a desire for health and longevity. In this case, pit and fissure caries was deep into the dentin thus a foundation of Fuji IX was placed after simple caries removal had been completed. The final prep was completed to ideal depth using the Fuji IX as the floor of the prep. EZ gold was used to complete a class one gold foil restoration that should give the patient years of service beyond other materials. Also notice in the final photo the posterior composite on the first molar that will need replacing shortly. Again an opportunity lost but at least salvageable with a gold casting.

The final case (Figures 21 and 22} presents with the following environment. The patient is in their middle 30s with moderate to poor oral hygiene. The patient is a tobacco user, smoking at least a pack of cigarettes a day. His diet consist of high carbohydrate and high sugar intake including several sodas a day. He is interested in the least expensive treatment possible and really does not place oral health or dental care as a high priority. This patient is in the author's opinion "below the line" for optimal dental care. However, the patient should be treated with respect and restorative choices should be selected that bring cost and reasonable longevity into play. This patient can be converted to an "above the line" patient who values oral health and long term dental restorative care. He simply needs to be educated and shown the value of good dental care in a respectful and caring dental environment.

In a case where there is poor oral hygiene with moderate to high dental carries, a restorative material should be selected that can stand up to the environment into which it is placed. Something needs to be done, just waiting for the patient to realize the error in their thinking or putting in the latest material just because everyone else is using it is inappropriate. In this environment posterior composites would be a poor choice. Studies show there is significantly less recurrent caries around amalgam then resin composites.[5] Therefore, alloy is best to consider in an environment such as this. Corrosion will seal the restorations allowing for longer life in a marginal environment. In addition, the cost will be less than other materials allowing, in many cases, a patient with limited means and/or poor priority selection, to save their teeth. The author prefers a high copper alloy such as Tytin by Kerr.

The restorations should be polished. This will not only create a surface that is easier to clean, it is less likely to have food and plaque stick. By polishing alloy restorations or properly finishing all restorative materials, the dentist is establishing a trust relationship with the patient. In addition, longer life of the restoration is more likely. Also, by polishing and finishing all restorative treatment the dentist is giving the patient the opportunity to see and feel the difference between restorative work that is not finished. It has been the experience of the author that this will help influence the patient to understand the value of good oral health and quality restorative work. Through this experience the patient will be more likely to place high-quality restorative work on a higher priority than it might have been. The operator will find that cost is not the problem with

accepting quality restorative work, it is all about priorities and trust.

When patients are educated about physical properties of materials and given the opportunity to experience quality restorative work, health and longevity become more important than cosmetics. Cosmetics, while still important, is simply placed in a more realistic position with relation to wants verses needs.

Finally, if dentists would do routine outcome assessments for restorative work they complete, documenting the time of placement and time before replacement is needed, accurate restorative cycles could be assigned to all restorative procedures within a given practice. Restorative cycles could be classified by material, restoration size and configuration, generation of placement and patient risk factors.

It is the opinion of the author that having accurate information about how long various restorative options last before replacement is necessary will give the dentist, that completed the procedure, a better understanding about the long term effects of the various restorative choices within his/her practice. In addition, in the opinion of the author, it is the responsibility of all restorative dentists to be competent in the placement of all available restorative materials. There is no one restorative material or technique that is appropriate for all situations.

Conflicts

None declared.

References

1. Moore DL and Stewart JL. Prevalence of defective dental restorations, J Prosthet Dent 1967;17(4):373–8.
2. Fontana M. and Gonzalez-Cabezas C. Secondary caries and restoration replacement: an unresolved problem. Compendium 2000;21(1):15–24.
3. Henry DB. A philosophy for restoring virgin caries. J Oper Dent 2008;33(5):475–83.
4. Henry DB. The consequences of restorative cycles J Oper Dent 2009;34(6):759–60.
5. Hilton TJ, Broome J. Direct posterior esthetic restorations. In: JB Summitt et al., eds.-Fundamentals of Operative Dentistry. Chicago: Quintessence Inc; 2006.
6. Roulet JF. Review of the clinical survival of direct and indirect restorations in posterior teeth of permanent dentition. J Dent 1997;25(6):459–73.
7. Manhart J, Chen H, Hamm G, Hickel R., Benefits and disadvantages of tooth-colored alternatives to amalgam. J Oper Dent 2004;29(5):481–508.

Contemporary Restorative Indications for the Use of Cast Gold: An Evidence-Based Perspective

Indications contemporaines pour l'utilisation des restaurations en or: une perspective fondée sur les preuves

By Dr. Mark A. Cruz, DDS

About the Author

Mark A Cruz graduated from the UCLA School of Dentistry in 1986 and started a dental practice in Monarch Beach, CA upon graduation. He has lectured nationally and internationally and is a member of various dental organizations including the Pierre Fauchard Academy, Pacific Coast Society for Prosthodontics and the American Academy of Restorative Dentistry. Until recently, he taught part-time at UCLA and was a member of the faculty group practice and was past assistant director of the UCLA Center for Esthetic Dentistry. He is currently on the editorial board as section editor for the Journal of Evidence Based Dental Practice (Elsevier). Please visit www.markacruzdds.com for a more detailed CV..

ABSTRACT

For decades, cast gold has been the standard, conservative indirect material of choice for restoring the posterior segment of the mouth when large direct restorations failed either due to recurrent caries, fractured cusps, patient reported symptoms of thermal sensitivity, or function. This reality was manifest by dental school curriculum, post-graduate education and licensure criteria. More recently in the past 1–2 decades, there has been an obvious shift away from the use of cast gold as reflected by changes in dental school curriculum and a progressive demand for "tooth-coloured" materials driving continuing-education courses and self-touted dental institutes as well as contemporary dental materials research. No doubt the public at large has had its awareness and demand increase for "cosmetic" restorations via "reality make-over" shows and magazine advertisement. The dentist's role in treatment planning the use of these materials as the perceived latest and greatest technologies has no doubt played a significant role with the public's awareness and demands. The purpose of this review is to discuss the major factors that may have resulted in the significant shift away from what the profession's standard had once been in restoring the posterior segment of the stomatognathic system. In addition, a proposal will be submitted in re-evaluating contemporary indications and contra-indications for the use of cast gold in the context of this review as well as current "best evidence".

Flawed dental dogma, a misunderstanding of how teeth, tooth structure and dental materials behave in function development of cosmetic" tooth-colored materials and market pressures are some of the major factors that have contributed to the decline of cast gold restorations in dentistry today.[1] The perception by the public at large regarding developing technology as well as the profession's will to constantly improve on established standards has also contributed to the oft-mistaken notion that novel technology is synonymous with better outcomes. No area in dentistry can demonstrate these notions better than in the development of tooth-colored materials. The profession's collective emotional and at times irrational mindset regarding novel ideas and developments has historically been demonstrated beginning with Michael Buonocore's introduction of the acid-etch technique in his paper published in 1967 with his seminal effort beginning in 1955 at the Eastman Dental Center.[2] The controversy this development stimulated within the profession at large is well known and not dissimilar to the controversy created within the medical profession

Figure 1

Figure 2

Figure 3

Figure 4

by Florence Nightingale's statistical tracking of post-operative infection. Both represented paradigm shifts that were difficult for their respective professions to accept as necessary changes in clinical practice. Since the advent of Buonocore's scientific contribution, the evolution of tooth-colored materials both bonded and un-bonded has continued unabated with some controversy. The posed controversy has existed mostly due to the conflict in values between "cosmetics" and predictable longevity statistically measured in decades versus mere months (Figures 1 and 2). Today the question regarding the use of tooth-colored restorative materials is not so much a matter of "if" these treatment alternatives are viable as much as "when" they serve the patient's best interest. The profession and the public at large would be better served if a more balanced approach would be considered when deciding which technique would best fulfill the patient's expectations, values and preferences. Both mindsets of "metal-free" dentistry and the inflexible use of indirect gold technique represent two sides of the same coin. Although cast gold technique represents a standard for longevity, function and comfort it does not represent a panacea for contemporary clinical practice. Tooth-colored options clearly fulfill the requirements of many clinical scenarios yet the experimental nature of many of these novel materials requires the conscientious clinician to divulge this reality to the patient as part of informed consent in comparison to the established "gold' standard.[3]

The following discussion will review some of the known factors that have contributed to the significant decrease in the use of indirect gold in the profession including flawed dental dogma, a lack of appreciation for the true nature of tooth tissue/structure behaviour in function and cosmetic driven influence in restorative choice. Rational suggestions for contemporary indications and contraindications for the use of indirect gold in contemporary modern practice will be made.

Flawed Dogma: Gold Inlays Fracture Teeth

The idea that cast gold inlays fracture teeth has been propagated as truth over the course of at least the last 30–40 years as stated in dental school textbooks and low level scientific evidence via in vitro lab bench studies.[4–6] Recent higher level evidence which will be discussed, strongly suggests otherwise.

Much of the flawed dogma regarding inlay mediated tooth fractures was based on

anecdotal clinical observation at a time where casting protocols were in a continuous evolution of development as well as a rudimentary understanding of dental tooth composition and structure. Although William H. Taggart first introduced the lost wax technique in 1907 and went on to develop a simple yet effective casting apparatus, others such as J.G. Lane and later C.S. VanHorn improved the accuracy of dental gold castings.[7] With more formalized dental school/university-based materials science, greater appreciation of the many intricacies in developing properly expanded, passive yet precise fitting castings continued. However, latent adoption and lack of universal appreciation of precise casting control is evident in much of the published literature[8] as described in the materials and methods sections where for example similar investment water: liquid ratios are utilized regardless of the casting design studied e.g., 2-surface, 3-surface, full coverage, etc.[9] As it turns out, these factors result in significant variability of casting fit and potential consequent stresses in the tooth/casting complexes as well as flawed study conclusions. Also, photoelastic studies used to support the notion that inlays behave as wedges are fundamentally flawed due to the inaccurate representation of tooth structure and resultant photo elastic stress/strain relationships. These "classic" studies have resulted in the erroneous concepts perpetuated in restorative dental text books used at least in part to inculcate the profession. For decades, restorative textbooks have commonly stated that cast inlays are retained by a "wedging" effect.[4] In actuality, when properly fabricated, dental castings are retained by an intimate adaption to the cavity preparation via a frictional fit from reciprocating axial surfaces with the luting agent further binding the complex together through cohesive energy. This outcome results in support of the remaining tooth structure and a favourable stress distribution within the tooth/casting complex. These outcomes are supported by clinical evidence that poses as significantly higher level evidence then the aforementioned in vitro bench studies.[10]

Finite-Element Analysis

More recently, finite-element analysis (FEA) studies have also resulted in a flawed representation of the behaviour of natural tooth structure.[11] The Young's modulus constants as well as Poisson's ratios of natural tooth tissues used to generate these studies have proven to be significantly inconsistent with the true modulus constants known today. Moreover, a lack of appreciation of the role of the dentino-enamel junction (DEJ) in providing the natural tooth with its resistance to flexure has been missed.[12,13] By virtue of the absence of the Young's modulus constant for the DEJ in recent FEA studies, the resultant conclusions regarding tooth tissue behaviour in function must be called into question in consideration for what we know currently. As an example, in Magne et al.'s study which evaluated tooth compliance/flexure after the removal of ⅓, ⅔ and complete removal of facial enamel, there was a dramatic increase in tooth flexure once the DEJ was compromised by complete removal of the facial enamel.[13] The experimental bench study used strain gauges on natural teeth to measure tooth flexure with an applied incisal load after the removal of ⅓, ⅔ and complete removal of the facial enamel. Although the increase in flexure was linear after the removal of the first and second thirds of facial enamel a significant non-linear inflection point was noted in the graphic representation of the experimental teeth once the remaining enamel was removed. This dramatic increase in tooth compliance/flexure after complete removal of the facial enamel was dismissed as an experimental artifact attributed to enamel crack propagation under the strain gauge affecting its signal. The FEA study that was run in parallel to collaborate the bench study as is commonly performed, resulted in a relatively linear increase in tooth compliance/flexure as well after the removal of the first 2 third increments and a smaller inflection once the enamel was completely removed. This result is attributed to the constants used and the omission of the DEJ's modulus, now known to confer significant resistance to flexure. The observations on the importance of the DEJ in resisting flexure and consequent fracture is collaborated by the most recent studies evaluating the mechanical properties of the human enamel and dentin.[11–15] The aforementioned comments are intended to emphasize the historical mischaracterization and flawed experimental observations on which didactic dogma has been perpetuated. As stated by Donald Maxwell Brunette, based on a positivist view of the world, empirical statements that describe the real world can be either true or false as a matter fact.[16] Decisions made based on false empirical statements are consequently likely to be erroneous. When involved in patient care, a re-evaluation of the evidence ought to be considered as prudent and rational.

The therapeutic replacement of lost tooth structure with a functional replacement that affords predictable long-term function can only be accomplished via a current and rigorous appreciation of its behaviour in function. In other words, a "bio-mimetic" replacement must be discussed in terms of functional biomechanics (resistance to fracture), physiologic wear of the opposing dentition and esthetic considerations. The exclusion of any of these 'bio-mimetic" factors may bias the optimal clinical outcome at the expense of the patient's preferences and values.

Hard tooth structure has been characterized as a composite material composed of enamel, mantle dentin and the DEJ. The surface hardness of enamel serves to function physiologically against the antagonist tooth structure and to protect the softer underlying DEJ and dentin complex. As it turns out, recent evidence suggests that, enamel is not the inherently brittle material it was once believed to be.

Enamel

The microstructure of enamel includes a configuration of apatite crystals and protein, enabling enamel to retain its structural integrity under cyclic loading for the life of the individual. Moreover, due to the shearing ability of the protein layers in enamel, it appears to behave more like a metal where the planes of atoms can slip over another under applied stresses enabling enamel to absorb a significant amount of energy prior to mechanical failure.[15] Thus, as a surrogate replacing enamel, it appears that this specific physical property of gold mimics nature (bio-mimetic) in regards to wear and fatigue more so than a brittle material such as ceramic or tooth-colored materials such as composite.[17] Due to the strong inter-atomic bonds present in ceramics, catastrophic failure characterizes brittle materials due to the limited ability to deform when absorbing energy in function.[15]

Additionally, it has been known to the point of

Figure 5

being self evident that dental ceramics causes more wear on the antagonist dentition than does gold alloy.[17] As suggested by Xie et al., dental materials with stress-strain responses similar to those of enamel may show less abrasiveness and better protective effects on the opposing dentition at least in part due to a reduction of stress concentration at functional contact points.[15] To date, gold alloys possess these biomechanic characteristics and ability to maintain form long term more so than any other material currently used in dentistry and therefore functionally harmonized best with the natural dentition.

Dentin/DEJ

Due to dentin being the most abundant tissue present in the human dentition, knowledge of its physical properties is important in understanding what material best serves as its substitute when it is lost due to caries, fracture or iatrogenic removal. Various restorative materials possess varied physical properties that dictate preparation design and indication.

The dentin that is protected by the harder enamel structure is what affords the dentition its resilience and toughness to function over a lifetime of cyclic mechanical challenge. Many of the concepts of the biomechanical properties of dentin have changed in the past 30 years.[11] For one, the magnitudes of the elastic constants are known to be significantly higher. The elastic constants (Young's) are measures of stiffness. Also, pre-existing flaws in dentin can cause teeth to fail at stresses far less than their theoretical strength. Therefore, dental restorative materials that confer stiffness become more predicable over time in restoring the replaced tooth structure (dentin, DEJ) and preserving long-term function. With all this in mind, we must set aside outdated dogmatic concepts that has influenced preparation design and indications for the use of cast gold.

As such it is important to understand that the all important junction between enamel and dentin, the DEJ acts to transfer functional loads from the enamel to the dentin and inhibits cracks in enamel from propagating and resulting in catastrophic fracture of the tooth. Imberni et al. have shown that cracks that are initiated in enamel are arrested after penetrating the DEJ within the mantle dentin (dentin adjacent to the optical DEJ).[13]

The greatest significance regarding strain values and stress distribution on the tooth in function is directly influenced by the quantity of tooth structure remaining and restorative material placed.[18–20]Therefore, conservation of tooth structure is of paramount importance in restoring long-term function. The lower the elastic modules of the restorative material used the less stiffness is imparted to the tooth resulting in greater flexure and consequent increased distribution of stresses to the tooth.[21]

Cosmetics

Over 40 years ago, Goldstein conducted a survey of 60 females ages 15–17 who were beauty pageant finalists and published his paper with the title "Study of Need for Esthetics in Dentistry." The author stated in his conclusions that when most of these young women asked their dentists for treatment advice related to cosmetics, the response was "it is not important" or "you look good enough."[22] Today, these responses would be considered inappropriate and insensitive. With that said, has the pendulum swung too far toward cosmetically driven dental treatment at the expense of function and longevity? Are these two values necessarily mutually exclusive? How much has the dental manufacturer influenced both patient and dentist in providing cosmetically driven dental care? How much of cosmetically-driven dental treatment has resulted in unnecessary health care cost? Running parallel to these questions are how much has the profession's previous lack of sensitivity toward the patients cosmetic preferences played a role in current market trends? Has the aforementioned discussion regarding didactic dogma as it pertains to iatrogenic tooth fractures played a contributory role in the decreased use of conservative gold castings? Has the prophylactic shoeing or onlaying of cusps to guard against cusp fracture as dictated by previous operative and prosthodontic principles narrowed the indication for cast gold to make it virtually irrelevant due to the cosmetic ramifications?

These are just a few questions that the conscientious dentist who is focused on the patient's overall well-being might consider, going forward. Also, in an era of evidence-based decision making, not only are we required to consider the best current evidence regarding our treatment recommendations but we are also to integrate the patient's preferences and values with the recommended treatment born out of accurate diagnosis and prognosis related issues.[23,24] In short, it is today's dental professional that has the responsibility of providing the patient with an informed consent due to the plethora of choices available many of which are still considered experimental. The "latest and greatest" is not synonymous with what is "best" for the patient but rather is more consistent with marketing influence. As defined by Beauchamp and Childress, an informed consent occurs if a patient, with substantial understanding intentionally authorized a professional to do something.[25] "Substantial understanding" requires that the patient be advised of the risks and benefits of each of the treatment alternatives. Although this process may take time beyond the mere execution of the procedure it does represent an important investment in the patient/doctor relationship and fosters trust that eclipses the necessary fiduciary event.

Few restorative situations are clear black and white decisions but rather more commonly reside in the grey. It may be well within the patient's values and rights to prefer a cosmetic outcome at the expense of duration of service if they are fully informed and intelligently accept the risks of their chosen alternative provided that the clinician is comfortable with the patient's decision. It does the profession,

Figure 6

Figure 7

Figure 8

Figure 9

Figure 10

Figure 11

Figure 12

Figure 13

Figure 14

Figure 15

Figure 16

Figure 17

Figure 18

Figure 19

Figure 20

Figure 21

Figure 22

Figure 23

Figure 24

Figure 25

Figure 26

Figure 27

Figure 28

Figure 29

Figure 30

Figure 31

Figure 32

Figure 33

Figure 34

Figure 35

Figure 36

Figure 37

Figure 38

Figure 39

Figure 40

Figure 41

Figure 42

the patient, the clinician, and the utility of cast gold a disservice if the application of the cast gold technique is performed in the absence of the patient's informed acceptance. The argument can be equally made for the execution of any cosmetic restoration without the patient fully understanding and accepting the incurred risks and costs for both the short-term and long-term.[3,26] With the aim of perpetuating the value and relevance for advantages of cast gold in modern dental practice one may consider the following below as indications for the use of cast gold in this era of cosmetically driven treatment.

1. Whenever possible, eliminate the use of reverse bevels when shoeing non-functional cusps in the maxillary arch as they unnecessarily result in unesthetic outcomes (Figures 3-8).
2. Consider the use of cast gold as a long-term restorative alternative when replacing initial failure of direct filling restorations in lieu of waiting until the direct restoration is so large that it requires either extracoronal protection or full coverage restoration (Figures 9-13).
3. Consider the use of cast gold for restorations that are extensive enough to justify a conservative indirect restoration and that will remain esthetic with minimal to no display of gold from a conversational distance (Figures 14 and 15).
4. Consider using gold exclusively in maxillary and mandibular second molars,especially when full coverage is required, while educating the patient of the well-known benefits and minimal to irrelevant cosmetic considerations (Figures 16-20).
5. Avoid the use of cast gold in areas where display will be obvious unless the fully informed patient insists. Think about the cosmetic ramifications for the future use of indirect gold in a population that misunderstands or is unaware of the benefits of biocompatibility, comfort, longevity and physiologic wear at the expense of cosmetically driven values (Figures 21-26).
6. Consider using indirect gold with the young patient where restorations need to provide reliable service for decades, or where bacterial reservoirs under failing composites are being removed and where caries are managed by risk assessment

(Figures 27-30).

7. Consider using indirect gold when managing dental erosion after addressing the underlying etiology. Cast gold is best suited with the erosion patient due to favourable wear characteristics versus ceramic or composite. Centric stops are maintained long-term while eliminating the lack of predictability that comes from bonding to compromised tooth substrate (Figures 31–42).

Summary

With an evidence-based mindset where the use of current "best" evidence and clinical expertise can be integrated with the patient's values and preferences, today's clinicians have the significant responsibility of discerning what is best for the patient beyond mere dogma or market influence. This includes the fulfillment of not only cosmetic desires but also the well-established values of functional longevity, comfort and biocompatibility. By fulfilling one of these criteria at the expense of the other without the patient's true, informed consent clearly poses as an ethical breach in the doctor, patient relationship. Therefore, in the context of this review, an updated and current appreciation for and an understanding of the behaviour of the tooth/restoration complex is essential. Although the aforementioned statements are not novel concepts, a re-evaluation of our collective mindset when it comes to practice philosophy can only help the patient-centered clinician. What makes this action difficult to state and accept is the tendency to become entrenched and convinced that what we are doing in daily practice is beyond reproach. Taking the responsibility to "pass the torch" to the next generation of clinicians that have yet to develop "clinical expertise" and witness long-term clinical outcomes in the context of market influence, self-touted "gurus" and financial pressures is not a small order to accept. The spirit of the Hippocratic Oath makes it a given.

Conflicts

None declared.

References

1. Efrati A. new business for dentists: fixing botched cosmetic work. Wall Street Journal June 29, 2004; page B1.
2. Buonocore MG. Simple method of increasing the adhesive of acrylic filling materials to enamel surfaces, J Dent Res 34:849–53
3. Chambers DW. The ethics of experimenting in dental practice. Den Clin NA 2002;46:29–44
4. Pameijer JH. Tooth preparation, periodontal and occlusal factors in crown and bridge procedures. Dental Center for ostgraduate Courses, Holland 1985:204.
5. Shillingburg HT, Hobo S, Whitsett L Principles of preparation, fundamentals of fixed prosthodontics. Chicago: Quintessence Publishing Co. Chicago;1981:79.
6. Fisher DW, Caputo AA, Shillingburg HT, et al. Photo elastic analysis of inlay and onlay preparations. Oper Dent 175;33(1):47–53
7. Donaldson JA. The Use of Gold in Dentistry: An Historical Overview Part I. Gold Bulletin 117–24
8. Cruz MA, Sorenson JA, Johnson KA. Effect of venting and seating techniques on cementation of full gold castings. Oper Dent 2008;33(6):690–95.
9. Hembree JH, Cooper EW. Effect of die relief on retention of cast crowns and inlays. Oper Dent 1979;4:104–107
10. Donovan T, Simonsen RJ, Guertin, etal. Retrospective clinical evaluation of 1314 cast gold restorations in service from 1-52 years. J Esthet Restor Dent 2004;16(3):194–204
11. Kinney JH, Marshall SJ, Marshall GW. The mechanical properties of human dentin: A critical review and re-evaluation of the dental literature. Crit Rev Oral Bio Med 2003;14(1):13–29
12. Whit SN, Paine ML, Luow, etal. The dentino-enamel junction is a broad transitional zone uniting dissimilar bioceramic composites. J Am Ceram SOC 2000;83(1):238–40.
13. Imbeni V, Kruzic J, Marshall GW, et al. The dentin-enamel junction and the fracture of human teeth. Nature Materials 2005;5. Available at: www.nature.com/naturematerials.
14. Magne P, Versluis A, Douglas WH. Rationalization of incisor shape: Experimental-numerical analysis. J Prosthet Dent 1999 81(3):345–55
15. Xiez, Swain MV, Hoffman MJ. Structural Modeling. Sage journals online 2009. z.xie@ecu.edu.av.
16. Brunette DM. Critical thinking: Understanding and evaluating dental research. Carol Stream, IL: Quintessence Publishing Co, Inc; 60188:48.
17. Koczorowski R, Wlochs. Evaluation of wear of selected prosthetic materials in contact with enamel and dentin. J Prosthet Dent 1999;81:453–9
18. Soars PV, Santos-Filho P, Gomide HA, et al. Influence of restorative technique on the Biomechanical behavior of endodontically treated maxillary premolars. Part II: Strain measurement and stress distribution. J Prosthet Dent 2008;99:114–22
19. Soares PV, Santos-Filho, Martins L, et al. Influence of restorative technique on the biomechanical behavior of endodontically treated maxillary premolars. Part I: fracture resistance and fracture mode. J Prosthet Dent 2008;99:30–37.
20. Edelhoff D, Sorensen JA. Tooth structure removal associated with various preparation designs for anterior teeth. J Prosthet Dent 2002;87:503–9
21. Dejak B, Mlotkowski A. Three-dimensional finite element analysis of strength and adhesive of composite resin versus ceramic inlays in molars J Prosthet Dent 2008;99-131–40.
22. Goldstein RE. Study of need for esthetics in dentistry. J Prosth Dent 1969;21(6):589–98
23. Sackett, Straus, Richardson et al. Evidence-based medicine second edition; Philadelphia: Churchill Livingstone; 2000.
24. Cruz MA. Real-world implementation of evidence-based dental practice. J Evid Dent Pract 2006;6:121–24
25. Beauchamp TL, Childress JF. Respect for Autonomy In: Beauchamp TL, Childress JF. Principles of biomedical ethics, fourth edition New York: Oxford University Press; 1994.
26. Cruz MA, Evidence-based versus experienced-based decision making in clinical dentistry. J Amer Coll Dent 2000;67(1):11–14.

Esthetic 7/8 Gold Crown – The Tucker Technique
Couronne esthétique 7/8 en or

By Dr. Randall J. Allan BSc, DMD

About the Author

Dr. Randy Allan graduated from the University of British Columbia in 1979 and has been in private practice in Vancouver as a member of the Camgara Dental Group since 1980. In 1984 Dr. Allan became a member of The Richard V. Tucker Cast Gold Study Club of Vancouver under the mentorship of Dr. Richard V. Tucker. He continues as an active member of that club as well as the Walter K. Sproule Gold Foil Study Club and is also himself a mentor of the Victoria R. V. Tucker and Nova Scotia R. V. Tucker Study Clubs. Dr. Allan has mentored and lectured on the Tucker technique of conservative cast gold restorations in Italy and the United States at various times over the years. He is a member of The Academy of Operative Dentistry and Past President of the Academy of R. V. Tucker Study Clubs.

As restorative dentists, one of the largest challenges we face is to restore proper form and function to teeth while considering the impact on the esthetic outcome. One must consider the clinical strengths and weaknesses of various materials as well as their applicability in different situations. For each clinical situation there is always a most favourable choice coordinating material and design for optimum physiological, functional and aesthetic results, as well as satisfying patient desires and expectations. The cast gold 7/8 crown with esthetic-buccal margin as designed and advocated by Dr. Richard V. Tucker is an extremely valuable procedure providing a very long-lasting and aesthetically pleasing restoration for extensive involvement of maxillary bicuspid or first molar teeth. This is particularly so in cases where there has been some degree of recession of the buccal or mesial-buccal cusp yet that cusp remains strong and of good stock in the gingival third of the tooth. Under the right circumstances, these teeth can be extensively restored without showing the gold, while leaving the natural colour and contours of the buccal cusp and avoiding insult to the pulp and gingival tissues from the restoration margin. All of these benefits contribute to aesthetics that are superior to porcelain-fused-to-metal or all-ceramic restorations, with less loss of tooth structure and trauma to the pulp from preparation. Advantages of gold as a restorative material include the following:

1. Less tooth reduction than all-ceramic or porcelain-fused-to-metal restorations. The tooth reduction is dictated only by the extent of the lesion – not by technical demands of the restoration.
2. Greater control of tooth anatomy – occlusally and axially.
3. Can be more easily adjusted at chairside:
   - Occlusion
   - Contours
   - Contacts
   - Polish
4. Better bio-compatibility:
   - Wear characteristics closest to enamel.
   - Co-efficient of expansion closest to tooth structure.
5. Will not fracture.
6. Supports enamel at the cavo-fracturing reducing the risk of marginal leakage.
7. Precise fitting margins are not dependant on bonding to seal.
8. Is much more easily removed, if necessary, especially when compared to many all-ceramic materials.

If the clinician is in agreement that gold represents the best restorative material from a strictly technical standpoint then it should follow that he or she would strive to use that material whenever possible for the extensive restoration of posterior teeth, provided there would be no deleterious esthetic impact of doing so. It is the intention of this article to demonstrate, through innovative design modifications, how gold can be used in situations traditionally

Figure 1



Figure 2

Figure 3

thought to require full coverage ceramic crowns while at the same time offering equivalent, and often superior, esthetic results.

The esthetic 7/8 gold crown is indicated for use in the following circumstances: (1) Maxillary molar or premolar teeth; (2) Extensive breakdown or caries necessitating an extra-coronally retained restoration; (3) Recession of the buccal or mesio-buccal root which presents severe esthetic challenges with PFM or all-ceramic crowns and risk to the pulp from deep preparation of exposed roots; (4) Lack of contraindications.

As with any restorative material or procedure there are some particular contraindications which preclude their use. In the case of the esthetic 7/8 gold crown these include:

1. Discernable fracture under the buccal / mesio-buccal cusp – either externally or internally.
2. Lack of stock to the buccal / mesio-buccal cusp. There must be good breadth of support at the pulpal wall level and no significant undermining of the cusp.
3. The need to shoe the cusp such as cross bite or end-to-end function.
4. Overextension of the existing restoration or caries at the mesio-buccal line angle.
5. Unfavourable tooth position (rotation to buccal or lingual. Short cusp which requires lengthening for esthetics).
6. Patient resistance. Even after patient education of the benefits of this restoration, and demonstration of the ability to hide the gold, some patients will not be convinced. They must be compliant to proceed favourably.

It should be noted that this article is not intended to fully prepare the reader to perform this preparation with expertise. Although not difficult, there are some subtleties that should be learned under clinical guidance to ensure optimum esthetic results when performing this procedure in ones office.

To demonstrate the principles of this procedure this article will deal with the maxillary left first molar as the tooth to be operated using an Ivoreen tooth (Candent Ltd., Mississauga, Ont.) in a mock set-up with adjacent second premolar and second molar teeth (Figure 1). However, the same design principles with minor modifications can be used on maxillary premolars. Note that the view perspective of the photographs is similar to the view the operator would have clinically as the preparation is being performed. The armamentarium needed is not extensive but is purposeful (Figures 2 and 3).

Provided the clinician has determined the buccal cusp to have adequate stock and be free from fracture, the first step is to build up the crown of the tooth with the material of choice to provide a platform for optimum preparation design. Note that if the build-up is to be left in at cementation it should have colour harmony with the tooth. Amalgam or dyed composite build-ups will compromise the aesthetic outcome as they will show through the buccal cusp with a dark tinge.

The initial occlusal reduction can be done with any bur of the clinicians choosing, however, a straight diamond works well for expediency and control. The occlusal aspect can be smoothed with a straight fissure bur or fine sand or cuttle disk (Moyco Union Broach, York, PA.) in the final stages. Note must be made of where the opposing functioning cusp will fall on the occlusal table and then the central groove of the occlusal reduction placed accordingly. The *inner incline of the mesial-buccal cusp is not reduced at this time* (Figures 4 and 5). Using a Brassler 860-012 (or similar) bur (Brassler Canada, Montreal, QC.) the next reduction is on the mesial wall, taking particular care to have the mesio-buccal cavo-surface margin parallel with the buccal surfaces of the teeth anterior in the arch while extending past the point of contact as little as possible. The buccal aspect of the mesial reduction should form a roughly 90° angle at the cavo-surface when completed. This is accomplished while establishing a concave or "hollow grind" contour to the mesial wall (Figures 6 and 7). Establishing the axial inclination of the mesial-buccal margin without over-extension is key to the aesthetic success of this restoration and dictates the draw of the rest of the preparation which is canted slightly to the lingual (Figure 7). The distal wall is then defined to draw with the mesial. At this time, care is taken not to wrap the distal reduction around to the buccal but rather carry it straight out from the embrasure (Figures 8 and 9). Mesial and distal reductions are now joined by reduction of the lingual wall. The larger diameter Brassler 860-014 bur can now be used and, if space allows, can be carried onto the mesial and distal surfaces to provide a more prominent chamfer and deeper hollow grind (Figures 10 and 11). The buccal wall reduction is only done on the distal half of the tooth and need not extend any more

Figure 4. Occlusal view of occlusal reduction.

Figure 5. Buccal view of occlusal reduction. Note that MB cusp is unreduced at this time. Cusp height remains the same as adjacent teeth.

Figure 6. Prepared surface follows contour of premolar, barely breaking contact.

Figure 7. Occlusal half of buccal cavo-surface margin is roughly parallel to the buccal surface of tooth and second premolar.

Figure 8.

Figure 9.

Figure 10.

Figure 11. Unreduced MB cusp well evident. Cusp height in harmony with adjacent teeth.

Figure 12.

gingivally than necessary to capture the extension of the previous restoration and provide adequate compliment to the resistance and retention of the rest of the preparation – specifically the mesial hollow grind (Figure 12). The surface of the buccal wall does not follow the buccal contours of the tooth but is made as parallel as possible to the lingual wall, in a mesial-distal direction (Figure 13). This results in the line angle at the juncture of the distal and buccal walls remaining quite precise and not rounded while producing a little peak or "ear" of enamel at the disto-buccal line angle (Figure 12). Care must be taken not to establish the mesial aspect of the buccal wall reduction in the mid-buccal groove (which would impair optimum finishing of the margin with disks at cementation) but rather establish it just beyond the groove while keeping it distal to the buccal height of contour of the mesio-buccal cusp (Figures 12 and 13). The distal wall reduction of the mesial-buccal cusp must draw with the mesial hollow grind (Figure 13). To complete the reduction of the occlusal aspect, counterbevel reduction of the functioning cusp is first performed (Figure 14). The final stage is the occlusal reduction of the mesial-buccal cusp. This is a key step in producing a favourable aesthetic outcome for this preparation. The inner incline must be reduced enough to allow adequate clearance for the opposing functioning cusp without reducing the height or altering the outline of the cusp tip. Using a mechanical pencil perpendicular to the cusp tip, the height of contour of the cusp is defined (Figures 15 and 16). Reduction of the inner incline is done with a #56 straight fissure burr parallel to an imaginary line joining the already established central groove and the height of contour of the cusp tip as defined

Figure 12.

Figure 13.

Figure 14.

Figure 15.

Figure 16.

Figure 17. The contour of the inner incline of the cusp is maintained with a precise cavosurface margin in place of the pencil mark.

Figure 18. Cusp outline is unchanged after reduction of the occlusal portion of the MB cusp.

Figure 19.

Figure 20.

by the pencil line (Figures 17 and 18). If the opposing cusp is quite broad, additional clearance can be attained by steepening the incline of reduction by moving the central groove slightly to the buccal and deepening it at the same time. The rest of the occlusal reduction can be smoothed with the #56 bur or a fine sand or cuttle disk at this time. If desired, the Brassler 8860-012 fine diamond can be used to refine the axial walls and margins.

Final finishing steps can now be performed. The buccal line angle distal to the mesio-buccal cusp is refined with a Suter 42S or 43S off angle hatchet (Suter Dental Mfg. Co., Chico, CA.), first on the distal of the cusp then on the buccal wall (Figures 19 and 20). This provides for a flat, slightly deeper surface of gold to brace the distal aspect of the cusp and compliment the bulk of gold of the mesial hollow grind. It also provides a precise line angle to aid in seating the casting (Figures 21 and 22). The distal wall of the mesio-buccal cusp is planed with a medium garnet disk maintaining a flat surface and providing a straight, precise cavo-surface margin (Figures 23 and 24). The final step in preparation is to place a very fine "counterbevel" along the buccal cusp tip with a fine cuttle disk to eliminate loose enamel rods, taking care not to change the shape of the cusp tip outline while smoothing the margin (Figures 25 and 26). This is not really a true counterbevel as much as it is an almost indiscernible blunting or rolling of the cusp margin. The angle placement of the disk is simply "counter" to the existing plane of reduction of the inner incline. Examination

Figure 22.

Figure 23.

Figure 24.

Figure 25.

Figure 26. Buccal cusp tip smoothed with fine cuttle. Note sharp line angle on distal of MB cusp and slightly deepened occlusal groove to accommodate opposing cusp.

Figure 27.

Figure 28.

Figure 29. Slight excess of gold along cusp tip will be removed with disking during cementation and become "invisible."

Figure 30. Mesial hollow grind draws slightly to lingual.

of the internal of the casting (Figure 27) and the seated casting reveals all details of the preparation steps. From the occlusal, the buccal-axial margin is short of the buccal height of contour and not in the concavity of the buccal groove (Figure 28) while the occlusal-buccal margin finishes at the height of contour of the cusp tip (Figure 29). The gold on the buccal wall distal to the mesial-buccal cusp is blocked from view by the contour of the mesial-buccal cusp (Figure 30). When viewed from the distal, the sharp lineangle between the distal and buccal reductions is reflected by the presence of an "ear" of enamel at the casting margin (Figure 31). The lingual margin can be kept supragingival owing to the extremely retentive design – provided the old restoration and tooth stock allow (Figure 32). On the mesial, the mesial gold of the casting is well hidden in the embrasure (Figure 33). If visible at all it is not readily noticeable, providing the margin is harmonious with the buccal contours of adjacent teeth (Figure 30). In the buccal view, the buccal cusps match the pre-operative form and are harmonious with the second molar and premolar (Figure 34). The mesial-buccal cusp will initially show a slight "plus gold" covering the cusp tip "counterbevel" (Figures 27, 29–31, 33 and 34). However, after proper finishing with disks the "plus gold" is eliminated as it is reduced to blend with the height of contour of the cusp tip at the counterbevel margin (See clinical cases). The finished casting approximates the original cusp height but the cusp appears unrestored owing to the aesthetic margin technique (Figures 1 and 35).

Figure 31.

Figure 32.

Figure 33. Shadows in the mouth also help to hide proximal gold.

Clinical Cases

The following clinical cases demonstrate the type of results that are attainable with this preparation. Of particular value with this technique is the ability to avoid having to prepare subgingival margins on exposed buccal roots. Reconstitution of the tooth's natural colour is a benefit of restoring with gold. The difficulty in seeing any gold in these case photos – taken from very close range with tissue retraction – sustains the premise that from a practical standpoint the ability for others to see small areas of exposed gold in social situations is vastly overstated given that shadows, tissue drape, lip movement etc., all aid in detracting the viewers eye from something that is very difficult to see under optimum conditions.

Figure 34.

Figure 35. Disto-buccal gold hidden by MB height of contour

Case 1

Figure 36. Rubber dam isolation of upper right first molar. Clinical symptoms and signs of cracked tooth syndrome require extra-coronal restoration.

Figure 37. Typical ideal 7/8 crown preparation with buccal axial margin just distal to buccal height of contour and MB margin barely breaking the contact point.

Figure 38. Finished casting. MB gold follows cusp tip.

Figure 39. Preoperative MB cusp was slightly shorter than normal but remains unaltered.

Figure 40.Colour and contours of MB cusp cannot be matched by ceramic restorations.

Case 2

Figure 41. Cracked tooth syndrome of palatal cusp of upper right first molar but buccal wall very sound.

Figure 42. Finished casting.

Figure 43. Note prep modification: Buccal axial margin is held distal to the mid buccal groove for improved aesthetics due to missing second premolar.

Case 3

Figure 44. Natural smile on this young woman shows no gold in spite of only one premolar.

Figure 45. Fracture of DB cusp. Note grey tinge to tooth from old alloy.

Figure 46. Extensive alloy shoeing DL cusp.

Figure 47. Key preparation components with modification of distal wall to follow tooth contours.

Figure 48. Seated casting.

Figure 49. Unaltered MB cusp with return of natural harmonious colour.

Case 4

Figure 50. Typical esthetic buccal 7/8 crown with B margin well distal of buccal height of contour.

Figure 51. Direct view of MB cusp shows a good example of the value in avoiding having to prepare a root exposed from recession and the ability to retain natural colour and contour.

Case 5

Figure 52. Lost lingual cusp of upper right second premolar but with good stock to the remaining mesial and buccal.

Figure 53. Seated casting. The buccal wall reduction is much shorter on a premolar than a molar but still ends distal to the buccal height of contour.

Figure 54. Gold is not visible in the natural smile.

Summary

One can only speculate as to why, in recent years, gold has fallen further and further out of favour as a material for the restoration of posterior teeth. Is it because of the explosion of available tooth-coloured restorative materials and the promotion of their use by the manufacturers; the lack of instruction in the use of gold in dental schools; the media induced perception that gold is visually disagreeable; its cost? Likely it is not singularly any of these but all of them in combination to varying degrees. Regardless of the reasons, it is up to the conscientious clinician to be the driving force behind what serves our patients' needs best and engage them in the decision making process from a position of objective patient education. If clinicians do not have the skills to use all available accepted methods and materials it is incumbent on them to seek to acquire those skills. It is true that the cost of gold has escalated in recent years but the difference between the lab fee for an all gold restoration and alternate labour intensive ceramic crowns is not significant. Isn't retained tooth structure and reduced pulp trauma worth a little more?

The "new technologies" in dental materials provide some excellent methods for restoring teeth which are often the treatment of choice in certain situations. However, embracing the "new technologies" while discarding "old technology," such as the partial veneer gold crown – simply because it's old – is to deny our patients an option that may actually be superior when trying to attain an optimum physiological, functional and esthetic result.

When prepared properly in the right clinical circumstances and using proper finishing techniques, there is no more superior restoration combining preservation of tooth structure, longevity, biocompatibility and optimum aesthetics than the esthetic-buccal 7/8 cast gold crown.

Conflicts

None declared.

Acknowledgements

I learned this procedure under the mentorship of Dr. Richard V. Tucker in a study club setting. I am forever grateful for his tutelage and cannot begin to express my appreciation for all I have gained from his guidance and friendship over the years.

As clinicians we are partners with our laboratory technicians and only as good as their contribution reveals. My sincere thanks to Akos Mankovits of Garden Court Dental Laboratory in Abbotsford, B. C., for his contribution to this article in fabrication of the Ivoreen tooth casting and for all of the clinical castings demonstrated.

Finally, I wish to thank the journal *Operative Dentistry* for allowing publication of this adaptation of an article which first appeared in that journal: *Operative Dentistry*, January/February 2009, Vol. 34, No. 1, pp. 119-123.

Utilisation des incrustations en or avec recouvrement des cuspides dans un cas de réhabilitation extensive. Un rapport de cas

Gold Inlays with Cuspal Coverage for an Extensive Rehabilitation Case. A Case Report

Par Dr Hugo Ciaburro

Biographie sommaire de l'auteur

Le Dr Ciaburro a obtenu son doctorat en médecine dentaire de l'Université de Montréal, suivi d'un certificat de résidence multidisciplinaire de l'hôpital général juif de Montréal et d'une maîtrise en réhabilitation prosthodontique de l'Université de Montréal.

Il est professeur agrégé au département de dentisterie de restauration de l'Université de Montréal où il y enseigne, entre autre, les restaurations en or coulé. Il maintient également à temps partiel à Montréal, une pratique privée limitée à la prosthodontie.

Il est Fellow du Collège royal des chirurgiens dentistes du Canada et membre de la Richard V. Tucker Academy of Study Clubs ainsi de l'American Academy of Gold Foil Operator.

Certains conférenciers affirment qu'il n'y a plus vraiment de raison justifiant l'usage des alliages métalliques en dentisterie aujourd'hui. Toutefois, plusieurs des matériaux esthétiques utilisés aujourd'hui ont été introduit depuis peu sur le marché et disposent par conséquent de peu d'évidences scientifiques pour appuyer de telles affirmations.[1] Par ailleurs, nous avons des décennies de recul clinique avec les restaurations en or coulé. Elles offrent des avantages indéniables sur les matériaux dits esthétiques: Durabilité insurpassée,[2] conservation du tissu dentaire, adaptation marginale inégalée, très faible potentiel abrasif sur les dents antagonistes, biocompatibilité incontestée sont certainement les avantages le plus souvent mentionnés. Certains les considèrent encore comme les restaurations de choix pour les dents postérieures.[3,4] Sommes nous en train de «jeter le bébé avec l'eau du bain»?

Il est plutôt rare de nos jours de voir des restaurations tout en or utilisées dans des cas de réhabilitation extensive. D'une part pour une question d'ordre esthétique, d'autre part pour une question de rentabilité clinique. Certaines situations cliniques ont peut-être encore avantage à avoir recours aux restauration en or coulé pour assurer une certaine pérennité.

Présentation de cas

Le cas dont nous allons discuter est celui d'un jeune homme dans la mi-trentaine dont la plainte principale était une sensibilité généralisée des dents au contact du chaud et du froid. Le dentiste référant pour sa part était surtout préoccupé par la progression d'une attrition généralisée au niveau des surfaces occlusales et des bouts incisifs (Figure 1).

L'examen clinique a révélé, en plus des quelques caries, de multiples surfaces d'attrition et d'érosion sur la totalité des dents. Selon l'échelle de Eccles et Jenkins (4), les lésions érosives obtenaient un score s'échelonnant de 1 à 2. Rappelons qu'un score de 0 est attribué lorsqu'aucune surface est atteinte, un score de 1 est attribué lorsqu'il y a érosion de l'émail sans exposition de la dentine, un score de 2 étant attribué lorsque la dentine est exposée sur moins du tiers de la surface de la dent et un score de 3 lorsque la dentine est exposée sur plus du tiers de la surface de la dent. Après

Figure 1. Vues pré-opératoires.

investigation auprès du patient, il a été établi que l'origine de ces lésions était extrinsèque et non causées par un problème intrinsèque de reflux gastro-oesophagien. Bien qu'il disait avoir arrêté depuis longtemps, le patient a rapporté s'être gargarisé pendant des années alors qu'il buvait plusieurs boissons gazeuses de type cola par jour. Le patient disait aussi être conscient de ses habitudes de bruxisme et de serrement des dents. Point de vue occlusion, malgré des traitements d'orthodontie à l'adolescence, quelques dents postérieures étaient en contact bout à bout, voir même en occlusion croisée.

Les principaux objectifs thérapeutiques visés étaient:

- d'éliminer la carie;
- de diminuer l'hypersensibilité dentinaire;
- de stabiliser la condition dentaire en ralentissant la progression de l'attrition et de l'érosion.

Planification des traitements

Trois plans de traitement ont été proposés afin de répondre en partie ou en totalité aux objectifs thérapeutiques. Ces plans allaient du traitement le moins interventionniste où seule quelques restaurations directes et gouttière occlusale étaient confectionnées, jusqu'au traitement beaucoup plus invasif où la plupart des dents étaient traitées à l'aide de restaurations indirectes. Les différents plans de traitement répondaient conséquemment en partie ou en totalité aux objectifs thérapeutiques visés. Ces plans de traitement ont été clairement exposés et expliqués au patient qui, après une période de réflexion de plusieurs mois, a décidé d'opter pour l'option qui semblait offrir le meilleur pronostic à long terme.

Le plan chosi était le suivant:

- Élimination des caries et stabilisation de la condition dentaire par des restaurations indirectes en or avec recouvrement des cuspides et des surfaces où la dentine est exposée;
- Stabilisation de la condition dentaire et établissement d'une guidance antérieure par des couronnes complètes céramo-métalliques sur les dents antérieures supérieures;
- Port d'une gouttière occlusale afin de protéger les restaurations des parafonctions.

Ce plan de traitement qui peut sembler à prime abord invasif, répond à tous les objectifs thérapeutiques car dans un premier temps, les dents détériorées seront restaurées de façon durable et dans un deuxième temps l'établissement d'une guidance antérieure permettra un désengagement des dents postérieures lors des mouvements de propulsion et de latéralité, réduisant par conséquent l'usure potentielle des restaurations postérieures. Il faut néanmoins être conscient que les couronnes céramo-métalliques planifiées sur les antérieures supérieures ont non seulement un coût biologique important qui leur est associé, mais peuvent engendrer une attrition accélérée des antérieures inférieures au fil des ans.

Procédures cliniques

La façon la plus simple et la plus rapide de procéder à un traitement de cet ampleur aurait certainement été de faire des couronnes complètes sur toutes les dents à restaurer. Cependant, deux facteurs ont été pris en considération lors du choix des modalités thérapeutiques: (1) L'âge du patient: des restaurations moins invasives et durables seraient certainement un choix judicieux. (2) Les habitudes de bruxisme du patient: le choix d'un matériau résistant mieux aux forces occlusales serait aussi un élément clé dans le succès à long terme de ce traitement.

Nous savons tous que toute restauration dentaire aura une durée de vie plus ou moins variable dépendant des matériaux choisis, des techniques de travail, du dentiste traitant et du patient. Même les restaurations en or, bien qu'elles soient encore considérées comme étant parmi les plus durables, devront être possiblement remplacées un jour. Qui plus est, chez un patient bruxeur dans la trentaine. Le fait d'opter pour des incrustations en or avec recouvrement de cuspides apporte par ailleurs une certaine marge de manoeuvre dans le succès à long terme de ce traitement. D'abord elles seront bien plus durables que des couronnes céramo-métalliques ou que des couronnes toute porcelaine. Il est en effet fréquent de constater des bris de porcelaine sur les restaurations toute porcelaine ou céramo-métallique, particulièrement chez les bruxeurs. Ensuite, si elles doivent être remplacées éventuellement, il restera plus de structure

dentaire saine que si on avait choisi de faire des couronnes complètes. Ceci nous amène aussi à réfléchir sur notre conception du succès à long terme. Comme dentiste restaurateur, nous devons non seulement accepter que les matériaux et les restaurations que nous confectionnons à nos patients ont une durée de vie plus ou moins limitée, mais aussi réaliser que c'est en partie les choix thérapeutiques que l'on fait maintenant qui feront de nos traitements un succès à court, moyen ou long terme. Que restera-t-il de notre travail dans 5, 10, 20 ans ou plus? En étant prévoyant aujourd'hui, on se garde des portes ouvertes dans le futur.

Bien que je sois un fervent croyant et pratiquant des principes établis et enseignés par le docteur Richard V. Tucker, un cas de cette envergure doit être traité avec une approche un peu différente. Comme la condition clinique n'imposait pas de procéder à une réhabilitation en une seule étape, c'est à dire où toutes les dents sont restaurées en même temps, nous avons décidé de procéder en 3 étapes espacées de plusieurs mois afin de donner un répit au patient. Nous avons donc procédé d'abord à la restauration des dents postérieures inférieures, ensuite à la restauration des dents postérieures supérieures et finalement aux dents antérieures supérieures. Nous aurions pu tout aussi bien débuter par les antérieures, suivi par les postérieures. Dans ce traitement, la création d'une nouvelle guidance antérieure doit être vue comme une protection additionnelle à long terme des restaurations postérieures et non comme une nécessité absolue de traitement. C'est pourquoi il n'était pas primordial de restaurer les antérieures en premier afin de redéfinir une nouvelle guidance comme c'est parfois le cas dans des réhabilitations complexes. Par ailleurs, la détérioration et la sensibilité plus prononcées de certaines dents inférieures nous suggéraient de débuter par celles-ci (Figure 2).

Les sextants postérieurs ont été préparés en suivant les principes de la technique Tucker, c'est à dire: dépose des restaurations présentes et ablation de la carie, dessin des préparations coronaires, reconstructions avec résine composite auto-polymérisante, taille finale des préparations et temporisation. Au lieu de prendre les empreintes finales avec des porte-empreintes à triple fonction (triple tray), des empreintes d'arcade complète avec porte-empreintes individuels ont été prises, un sextant à la fois, une fois toutes les dents impliquées de l'arcade taillées. Les modèles de travail ont été montés sur articulateur semi-ajustable en relation centrée comme il est de rigueur dans les cas de réhabilitation et non en position d'intercuspidation maximale. L'occlusion des restaurations finales a été ajustée avant la mise en place de la digue et leur scellement. En débutant par l'arcade inférieure, nous avons saisi l'opportunité de corriger des irrégularités mineures du plan occlusal inférieur par les restaurations en or et avons dû modifier les surfaces occusales de certaines dents antagonistes afin d'équilibrer temporairement l'occlusion, en attendant leur restauration. Les molaires inférieures ont été restaurées à l'aide de couronnes 3/4 inversées afin de répondre aux besoins des dents avant tout.

Figure 2.

Figure 3. Couronnes provisoires.

Figure 4. Couronnes permanentes.

Une gouttière occlusale a été confectionnée afin de protéger les restaurations mandibulaires et 6 mois se sont écoulés avant de débuter les traitements au maxillaire. Le même protocole a été respecté pour la restauration des dents postérieures supérieures. Environ 3 mois plus tard, les dents

Figure 5. Restaurations finales.

antérieures ont été taillées et de nouveaux paramètres ont été établis à l'aide des couronnes provisoires. Les provisoires jouent donc un rôle particulièrement important car elles détermineront la forme, la longueur et la guidance que les couronnes définitives devront reproduire. Ces informations critiques sont transmises au prothésiste par le biais d'un duplicata qui servira aussi à régler l'articulateur afin de fidèlement recréer les paramètres établis à l'aide des provisoires. Après s'être assuré du confort du patient par le port des couronnes provisoires plusieurs mois, les couronnes céramo-métalliques sur les antérieures ont été scellées, suivi par la mise en bouche d'une nouvelle gouttière occlusale (Figures 3-5).

Conclusion

Du début à la fin, les traitements ont duré environ un an et demi, incluant des intermissions de quelques mois entre chacune des trois phases. Aucun traitement de canal n'a été requis et le patient éprouve beaucoup moins de sensibilité au froid malgré le fait que les dents aient été restaurées avec des restaurations toutes métalliques. Est-ce que ces restaurations doivent être considérées comme permanentes? En aucun temps! Malgré la longévité insurpassée des restaurations en or coulé, il serait illusoire de croire qu'elles puissent être permanentes surtout chez un bruxeur de jeune âge... Il est donc fort probable que plusieurs de ces restaurations soient appelées à être remplacées au fil des ans. Le point que nous tenions à souligner ici est non pas l'indestructibilité des restaurations en or, mais plutôt le fait que non seulement ces incrustations sont susceptibles de durer plus longtemps que des restaurations en porcelaine, mais que les préparations coronaires ont certainement su être plus conservatrices que celles qui auraient été faites pour des couronnes complètes. Dans l'éventualité où certaines incrustations devront être remplacées, il restera donc plus de structure dentaire disponible pour concevoir de nouvelles restaurations, faisant des restaurations en or un choix doublement conservateur de par leur durabilité et leur économie de tissus dentaires.

Par ailleurs, le potentiel abrasif relativement destructeur des restaurations de porcelaine est sans aucun doute un facteur à prendre en considération lors de la planification de restaurations extensives chez un patient présentant des surfaces d'attrition généralisées sur l'ensemble de ses dents. Encore faut-il que le patient soit objectif dans ses décisions.

Références

1. Christensen GJ. Longevity of posterior tooth dental restorations. J Am Dent Assoc 2005;136(2):201–203.
2. Donovan T, Simonsen RJ, Guertin G, Tucker RV. Retrospective clinical evaluation of 1,314 cast gold restorations in service from 1 to 52 years. J Esthet Restor Dent 2004;16(3):194–204.
3. Donovan TE, Chee WW. Conservative

Conservative and Esthetic Cast Gold Fixed Partial Dentures – Inlay, Onlay, and Partial Veneer Retainers, Custom Composite Pontics, and Stress Breakers: Part II: Utilization of Additional Retentive Features and Fabrication of Custom Pontic Facings

Prothèses partielles fixes conservatrices - incrustations et attaches partiels, pontics individualisés en composite et connecteurs semi-rigides: Partie II Utilisation d'éléments rétentifs additionnels et fabrication de pontics individualisés

By Richard G. Stevenson III, DDS, and Jane A. Refela, DDS

About the Authors

Richard G. Stevenson III, DDS is professor of clinical dentistry and chair, Division of restorative rentistry, UCLA School of Dentistry, Los Angeles, CA.
Jane A. Refela, DDS is a general practice resident, VA Long Beach, CA, USA

ABSTRACT

Although in today's dental world implant restorations are considered the standard of care in the replacement of missing teeth, clinical contraindications and patient nonacceptance of implant placement can be encountered. Several scenarios are discussed here in which a single missing tooth can be restored with conservative fixed partial dentures (FPD) that employ cast gold retainers; each with a customized design in order to preserve tooth structure, maintain esthetics, and provide a long-term prognosis. The abutment teeth are prepared for conservative partial coverage restorations by using Brasseler burs (Brasseler USA, Savannah, GA, USA). Impressions are taken of the preparations, along with any retentive features, utilizing either the Vented Pin Channel technique or the Shooshan Plastic Pin technique. The latter technique utilizes Kodex twist drills and corresponding impression pins (Coltene Whaledent Inc., Mahwah, NJ, USA). The conservative FPD with non-rigid connectors is fabricated by using type III gold alloy. The pontic cage portion is chemically prepared utilizing the Panavia F2.0 cement kit (Kuraray America Inc., Houston, TX, USA) or other dual-polymerizing resin cement and restored with any type of direct composite resin material. A palette of opaquers and tints are used for chairside characterization of the esthetic pontic facing. The final polish of the pontic is completed by using FlexiDisc and FlexiBuff discs (Cosmedent Inc., Chicago, IL, USA).

CLINICAL SIGNIFICANCE

In cases where an implant restoration is contraindicated for replacement of a single tooth, a semi-precision FPD is a conservative, functional, and esthetic alternative.

Although today implants are considered the standard of care in replacing missing teeth, several relative contraindications that prevent implants from being the appropriate treatment option exist.[1,2] Diabetes, a history of chronic heavy smoking, radiation treatment for cancer patients, and other conditions may compromise implant predictability.[1,2] Additionally, some patients elect to replace teeth with more conventional options such as fixed/ removable partial dentures. In selected cases, a posterior tooth may be replaced with a conservative fixed partial denture (FPD) that employs the use of cast gold retainers, which is both esthetic

Figure 1. Proposed abutment teeth with a conservative composite in canine and large amalgam in premolar.

Figure 2. Abutment teeth prepared: canine is prepared for a distal hollow-grind with a lingual dovetail and gingival pin; premolar is prepared for an inlay with a slot. Note the independent lines of draw of each preparation.

Figure 3. Completed Inlay Retained FPD with non-rigid connector.

Figure 4. Distal hollow-grind with pin (note the countersink) preparation for increased retention.

Figure 5. Mesioocclusal inlay with slot preparation for increased retention.

Figure 6. Cast of FPD.

and functional. Several clinical scenarios that can be treated with such conservative FPDs exist, each with a customized design in order to preserve tooth structure, maintain esthetics, and provide a long-term prognosis. Various typical cases will be discussed, each presenting various indications and levels of complexity. A clinical example will also be presented in order to depict how to create an esthetic facing on the pontic of an inlay-retained prosthesis with direct composite resin.

Pin-Retained Inlay Retainers with Nonrigid Connector

The following case shows a canine with a small distal composite and a premolar with a large mesioocclusal amalgam restoration. It should be noted that, if the retainers on the canines and premolar were part of a rigid FPD, both would have to be prepared in the same line of draw. A significant advantage with a stress-broken FPD is that both abutments can be prepared with an independent line of draw and, therefore, in the most conservative manner.[3] The size of each preparation will be determined by the existing restoration and extent of caries (Figures 1–3).

The premolar contains a mesioocclusal inlay that is wide buccolingually. Therefore, a slot is placed in the distal portion of the preparation, in lieu of a more destructive preparation feature, such as a (distal) proximal box, to prevent mesial displacement.[4] As a rule of thumb, a slot (or pinhole) is placed as far from the primary retentive aspect of the preparation (the proximal box) as possible.[5] The slot must be prepared between 1.5 and 2.0 mm deep into the dentin and 2 mm wide for proper retention. For the canine, a hollowgrind is prepared in the distal by using a 7404 bur (Brasseler USA, Savannah, GA, USA) along with a lingual dovetail. For increased retention of the distoocclusal inlay, a pin is placed in the hollow-grind area, away from the lingual dovetail (the most retentive feature) of this inlay. The pin is prepared by first countersinking a concavity with a four-round bur and then preparing a hole 1.5 to 2.0 mm deep with a 0.022″ twist drill. Care should be exercised to ensure that the pin channel has the same line of draw as the remainder of the preparation (Figures 4 and 5). Obtaining an accurate and complete impression of accessory retentive features, such as slots and pinholes, may present the clinician with a significant challenge. Several techniques that are designed to capture retentive features without air entrapment or material distortion exist. Two techniques will be utilized to accomplish this: one utilizes a direct impression of the feature (the *vented pin channel* technique),[6] and the other uses a plastic pin to serve as an analog

Figure 7. Castings of FPD.

Figure 8. Segments depicting non-rigid connector design.

Figure 9. Esthetic appearance of final prosthesis.

Figure 10. Vented Pin Channel Technique: utilizes a modified 30 gauge needle to capture slot preparation in final impression.

Figure 11. Shooshan Plastic Pin Technique: pin is utilized for final impression of pin preparation (note: the pin is incorporated in the wax pattern).

(the *Shooshan plastic pin* technique) to record pin depth and orientation.

CLINICAL EXAMPLE OF FPD #12 [#24] DO INLAY WITH SLOT – #14 [#26] MOD INLAY

A clinical case is shown in Figure 6 in which the retentive slot feature is indicated. The patient presents with an existing distoocclusal restoration on #12 [#24], which is too wide buccolingually for sufficient retention for the planned abutment inlay preparation. Additional retention is achieved with the placement of a slot in the mesial portion of the distoocclusal inlay preparation. By not extending the dimensions of the preparation, the slot provides the required retention while also preserving the conservative inlay preparation. Note that the slot is once again placed in the area most distant from the primary retentive feature, the distal box. In Figures 7 and 8, the mesial and distal segments of the final FPD are shown prior to cementation. The esthetic result is seen in Figure 9 upon the patient's full smile.

Vented Pin Channel Technique

In this scenario, the slot feature is impressed with the use of a 30 gauge needle (Figure 10) that is modified by removing the bevel at the tip by bending the needle with a hemostat until it fatigues and breaks off. This will keep the lumen of the needle patent.[6]

The modified needle is then placed at the base of the slot and is withdrawn, as the impression material is being injected. The needle vents the air out of the slot through the lumen, allowing the impression material to flow readily into the slot without the incorporation of air bubbles. This technique is applicable when the retentive feature (a slot, in this example) is significantly large enough to accommodate the placement of the needle and the tip of the impression syringe.

Shooshan Plastic Pin Technique (Kodex Twistdrills and Plastic Pins: K95 [0.024″ 5 mm], K97 [0.027″ 5 mm], K98 [0.028″ 5 mm], Coltene Whaledent Inc., Mahwah, NJ, USA)

In this technique, the pin feature is recorded by employing plastic pins, which are inserted into the pinhole during the time of impression taking (Figure 11).[7] The pins are nontapered, comprised of nylon, and 0.001″ smaller than the final pin preparation diameter (0.022″). The plastic pins are cut with a scalpel to the desired length and placed in the pinhole for incorporation in the final impression. A dab of Vaseline (Unilever, Greenwich, CT, USA) may be placed on the pin tip prior to making the impression to help secure it on the tooth.

Figure 12. Final impression effectively capturing the slot preparation in the premolar and the pin preparation in the molar

Figure 13. Missing tooth space with adjacent teeth having no existing restorations.

Figure 14. Premolar and canine are prepared for conservative mesioocclusal and distal slot inlays respectively.

Figure 15. Completed Inlay Retained FPD with non-rigid connector.

Figure 16. Carbon steel hand instruments for refinement of internal line angles and external bevel of the preparation (232 Tucker gingival margin trimmer, 233 TRU-BAL gingival margin trimmer, and 45S Off-angle chisel).

Figure 17. Slot design for distal canine inlay (note the acute internal line angles).

The technician will utilize castable pin analogs (0.020″), which are smaller nylon pins, to be incorporated into the wax pattern (Figure 11).

SIMPLE INLAY RETAINERS WITH A NON-RIGID CONNECTOR

The following case shows a missing tooth space adjacent to teeth with no existing restorations. Although this would be ideally restored with an implant, clinical conditions that are contraindicated for implant placement can present.[1,2] In such cases, simple inlay retained FPDs are very conservative and functional alternatives to implant restorations (Figures 13–16).

The preparation on the canine is a slot design, with exaggerated acute internal line angles to maximize retention and allow for a conservative outline preparation (Figure 17). This preparation requires the use of various hand instruments (#45S Off-angle chisel for the facial and lingual axial proximal line angles, #233 TRUBAL gingival margin trimmer to form an acute gingival axial line angle, and #232 Tucker gingival margin trimmer for an external bevel at the gingival finish line) (Suter Hand Instuments Dental Manufacturing Company, Chico, USA) (Figure 16) to properly refine the internal line angles. The lingual outline form is completed with the use of a 7404 bur.[6]

The following clinical case will illustrate the utilization of an inlay FPD with an esthetic custom-made pontic. In this example, the patient has lost a maxillary first premolar and has existing restorations on the adjacent canine and second premolar (Figure 18). The previous restorations are removed, and the preparations are "blocked out" with either glass ionomer restorative material or chemical cure composite resin. In blocking out the preparations, the depth of the cavity can be optimized, the walls of the cavity can be made smooth, and the final outline form can be kept more conservative.[6]

A slot is prepared in the distal of the canine (as described previously) with acute internal line angles, keeping the preparation very conservative. The premolar is prepared for an MOD inlay. Note the outline sizes of the previous restorations and the new preparations in Figures 19 and 20. The final restorations will be very similar in size to the previous restorations as a result of the block-out technique.[6]

The pontic will be restored chairside by the clinician with the use of composite in order to maximize the shade customization to more closely mimic the facial appearance of the

Figure 18. Patient presents with missing tooth #5 [#14].

Figure 19. Teeth adjacent to the missing tooth space have existing restorations, which are removed and blocked-out with glass ionomer.

Figure 20. Abutment teeth are prepared under the isolation of a rubber dam for a slot inlay on the canine and MOD inlay on premolar.

Figure 21. Hollowed-out pontic ("cage" design) for macromechanical retention of composite for the esthetic facing. Note the sandblasted intaglio of the "cage" for micromechanical bonding of the composite.

Figure 22. Alloy primer and primer A and B (components of Panavia F2.0 cement kit) utilized to chemically prepare pontic for micromechanical retention of esthetic composite facing.

Figure 23. Semi-precision FPD tried in mouth for shade selection.

adjacent teeth. Any composite of choice can be used to restore the pontic facing. For composite to micromechanically bond properly to the gold surface of the pontic, the intaglio of the casting must first be mechanically and chemically prepared. The surface is first sandblasted with 50 mm aluminum oxide while ensuring that the margins of the adjacent inlay retainer and polished external surfaces are protected. The metal surface is then prepared chemically utilizing the Panavia F2.0 cement kit (Kuraray America Inc., Houston, TX, USA), which contains an alloy primer bonding system so that custom composite layering can be successfully completed by the clinician. A thin layer of alloy primer is added to the surface, followed by a thin layer of a mixture of primers A and B, and a layer of Panavia cement. The surface is then finished with a thin layer of oxygen-inhibiting gel. Note, the "cage" design of the hollowed-out pontic allows for macromechanical retention of the composite (Figure 21).

The segments for the semiprecision FPD are first tried in the mouth (Figure 23). A shade is selected for the composite resin, while the segments are temporarily positioned in order to optimize final shade match (note: the hue and value of the abutment teeth change with the gold inlay retainers in place). The composite is added in 2-mm increments up to 1 mm of the final contour. A layer of opaque composite may be added to the marginal areas of the pontic facing in order to further conceal the gold. A palette of opaquers and tints (Figure 24) are employed as necessary to maximize the characterization of the pontic facing during the final 1 mm of composite resin placement (Figure 25).

For the composite to be polished to a smooth and natural texture, composite finishing disks are utilized. The disks should rotate from the composite to gold surface so as not to incorporate gold particles into the composite (Figure 26).

Summary

For retention in the conservative inlay abutment preparations to be increased, additional retentive features such as slots and pins can be employed. Through the use of such retentive features, a conservative preparation design is achievable without the loss of retention and resistance forms. As seen in the clinical scenario presented, an acceptable esthetic result can be achieved with a gold inlay–retained FPD. Following the techniques described in this article, the clinician may customize the facing of pontics with layered composite. With the use of a



Figure 24. Palette of opaquers and tints used in the characterization of esthetic pontic facing.

Figure 25. Chairside characterization of esthetic pontic facing.

Figure 26. FlexiDisks and FlexiBuff (Cosmedent Inc., Chicago, IL, USA) disks for final polish of the composite on esthetic facing of pontic.

Figure 27. Buccal view, retracted.

Figure 28. Full smile.

Figure 29. Occlusal view: note excellent marginal adaptation and conservative extensions.

palette of opaquers and tints, it is possible to create esthetic pontics in conjunction with conservative excellent fitting gold retainers (Figures 27–29). By using the techniques described in this article, the objectives of tooth structure conservation, optimal marginal integrity, restoration longevity, and esthetics may be predictably achieved.

Disclosure and Acknowledgements

The authors would like to express gratitude for the mentorship of Dr. Richard V. Tucker and Dr. Warren K. Johnson for their tireless commitment to teaching cast gold excellence and for the description of several of the techniques in this article. The authors do not have any financial interest in the companies whose materials are included in this article.

References

1. Hwang D, Wang HL. Medical contraindications to implant therapy: part I: absolute contraindications. Implant Dent 2006;15(4):353–60.
2. Hwang D, Wang HL. Medical contraindications to implant therapy: part II: relative contraindications. Implant Dent 2007;16(1):13–23.
3. Markley MR. Broken-stress principle and design in fixed bridge prosthesis. J Prosthet Dent 1951;1:416–23.
4. Kishimoto M, Shillingburg HT, Duncanson MG. Influence of preparation features on retention and resistance. Part I. MOD onlays. J Prosthet Dent 1983;49:35–9.
5. Arbo MA. A simple technique for castings with pin retention. Dent Clin North Am 1970;14:19–29.
6. Tucker RV. Member Center—Syllabus. Available at: http://www.rvtucker.org/members/syllabus.htm (accessed September 17, 2008).
7. Shooshan ED. A pin-ledge casting technique—its application in periodontal splinting. Dent Clin North Am 1960;4:189–206.

© 2009, COPYRIGHT THE AUTHORS JOURNAL COMPILATION © 2009, WILEY PERIODICALS, INC. DOI 10.1111/j.1708-8240.2009.00293.x VOLUME 21, NUMBER 6, 2009 375. Reprinted with permission.

Method to Establish Lost Occlusion Plane Using Broadrick Flag: A Review

Méthode pour le rétablissement de la courbe d'occlusion utilisant le drapeau Broadrick

By Dr. Sandeep Garg, MDS, Dr. Sandeep Kumar, and Dr. Aparna Bansal

About the Authors

Dr. Sandeep Garg, MDS, is a professor in the Department of Prosthodontics, M.M. College of Dental Sciences & Research, Mullana, Ambala (Haryana)
Dr. Sandeep Kumar, MDS, is a reader with the Department of Prosthodontics, Surendera Dental College & Research Institute, Sri Ganganagar, Rajasthan.
Dr. Aparna Bansal is a post-graduate student, Department of Prosthodontics, M.M. College of Dental Sciences & Research, Mullana , Ambala (Haryana).

Correspondence can be directed to Dr. Sandeep Garg, MDS at: mdssandy07@gmail.com.

ABSTRACT

Proper management of the occlusion plane is an essential consideration when restoring or replacing most of the posterior teeth. Restoration of altered occlusal plane resulting from tipped, rotated, or extruded teeth can introduce excursive interferences resulting in detrimental sequelae. A Broadrick occlusal plane analyzer is an instrument which is used for analyzing the curve of Spee and developing an acceptable plane of occlusion without introducing protrusive interferences. Consideration must be given to lateral excursive movements also. This article provides valuable information regarding importance of curve of Spee and curve of Wilson in restorative and prosthodontic dentistry and also about the technique to develop an acceptable plane of occlusion by using Broadrick occlusal plane analyzer.

The configuration of the occlusal plane is one of the most beautiful examples of the design that can be found in nature. The plane of occlusion refers to an imaginary surface that touches the incisal edges of the incisors and the tips of the occluding surfaces of the posterior teeth.[1] When we relate to a plane, we initially think of a flat surface, however, this is not the case with the occlusal plane. The plane of occlusion combines a composite of curve of Spee, curve of Wilson, and the curve of incisial edges. Two areas constituting the occlusal plane are anterior and posterior teeth and should be addressed separately. The position of the anterior teeth is determined by esthetics, the demand for anterior guidance and phonetic consideration .The curvature of the posterior plane of occlusion is divided into: (1) An antero-posterior curve called the curve of Spee, and (2) A mediolateral curve referred to as the curve of Wilson.

Compensating Curves and their Importance

Curve of Spee

In natural dentition, there exists an antero-posterior curve that passes through the cusp tip of the mandibular canine and buccal cusp tip of the mandibular premolars and molars, and that extends in a posterior direction to pass through the most anterior point of mandibular

Figure 1. The Curve of Spee.

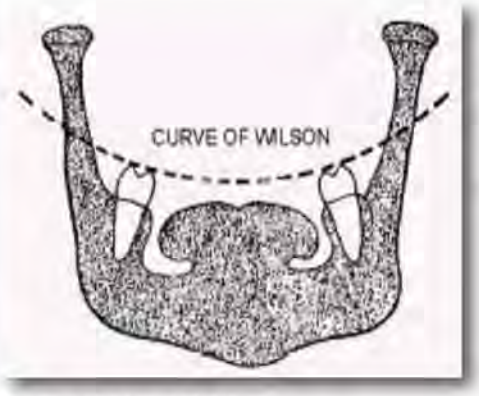

Figure 2. The Curve of Wilson

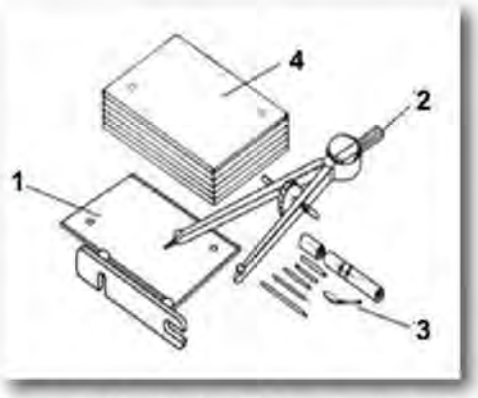

Figure 3. (1) Card index. (2) Bow compass with graphite leads, an extra center point and a needle point; (3) Scribing knife. (4) Plastic record cards.

condyle,[2] originally described by Ferdinand Graf Spee[2] a German anatomist in 1890. This curve exists in sagittal plane and is best viewed from a lateral aspect. Spee located the center of the curve passing through the middle of the orbits behind the crista lachryma posterior (Figure 1).

Spee's idea was advanced in 1920 by George Monson.[3] Based on anthro-pological observations, he described a three-dimensional sphere that passed through the incisal edges of the mandibular anterior teeth and occlusal surfaces of mandibular posterior teeth, the center of rotation of which is located in the region of glabella. The radius of this curve is reported to be 4 inches (10.4cm).

There is a purpose behind the curve of Spee design as well as its location in relation to the condyle. If occlusal plane is established on an arc that passes through the condyle, the posterior part of the occlusal plane will always be flat and low enough to be discluded by mandibular protrusion; this is even so with a flat anterior guidance.[1] Hyperactivity in temporalis and masseter muscles has been demonstrated during mandibular protrusive movements when occlusal interferences are present.[4] These interferences may result in wear, fracture of restorations, and temporomandibular joint dysfunction. Thus, this separation of the posterior teeth in protrusive movement prevent possibility of damage to the teeth, the joints and the periodontal structure.

Curve of Wilson

It is a mediolateral curve that contacts the buccal and lingual cusp tips on each side of the arch, results in inward inclination of lower posterior teeth making the lingual cusps lower than the buccal cusps on the mandibular arch.[5] This lingual inclination of lower teeth permits easy access for food to get to the occlusal table with no blockage by lower lingual cusps, also it facilitates lateral excursion without interferences (Figure 2).

Technique

The path of occlusion may be pathologically altered in situations resulting from rotation, tipping and excursion of teeth. Restoration of dentition to such an altered occlusal plane can introduce posterior protrusive interferences.[6] These interferences can be avoided by establishing the plane of occlusion on a curve that passes through the mandibular condyle, which has been demonstrated to allow posterior disclusion with mandibular protrusion,[7] as the angle of condylar guidance is greater than the curve of Spee.[8]

There are three practical methods for establishing an acceptable plane of occlusion and they are discussed below.[1]

Analysis on Natural Teeth through Selective Grinding

There is no need to change the plane of occlusion, if it is possible to eliminate the excursive interferences without losing centric occlusal contacts. Teeth can be reshaped until they are discluded by the anterior guidance in excursion. If it appears that sensitivity may be the problems after the adjustments, the operator should be prepared to proceed with the preparation for the provisional restorations. This method does not eliminate the need for the mounted diagnosed casts, in fact it should only be considered after mounted casts have been studied and a decision made to equilibrate the occlusion.

Analysis of Facebow Mounted Casts with Properly Set Condylar Paths

Any articulator that can accept a face bow transfer and can duplicate condylar border paths can be used to analyze or establish correct occlusal plane. The need for fully adjustable articulator is no longer as critical as once believed, since there is rarely a need for posterior group functional on the working side and there is never a need for excursive contact on the posterior teeth in protrusion or on the non working side. Disclusion can be affected by any articulator setting that is flatter than the actual condylar path in the patient. Selective grinding or preliminary wax-up or both can be done on the casts to show the outer limits of the occlusal plane contour and position. This wax-up can also be used for fabrication of provisional restorations.

Use of Pankey-Mann-Schuyler Method (PMS) of Occlusal Plane Analysis

In selecting the method for a particular patient, remember that the purpose of entire procedure is to cause posterior disclusion in mandibular excursion. PMS technique provides an excellent and practical method for determining an occlusal plane that will fulfill all the requirements of a correct occlusion. The simplest method of implementing this part of

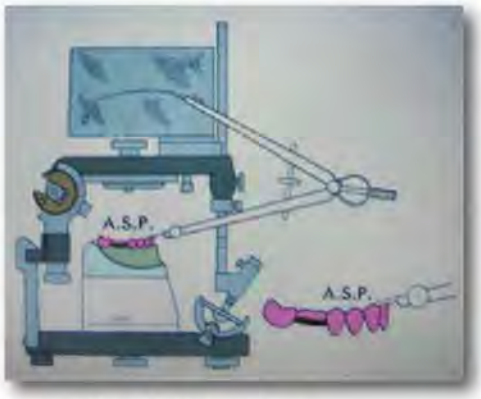

Figure 4. The anterior survey line.

Figure 5. The posterior survey point.

Figure 6. The condylar survey line

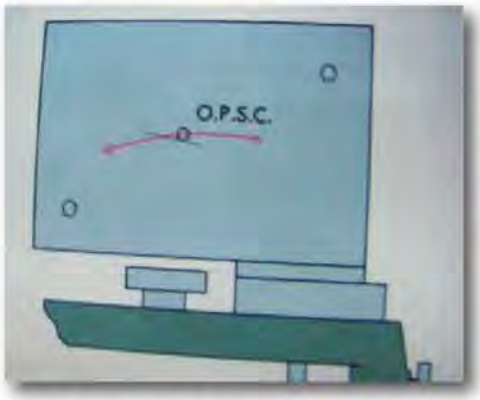

Figure 7. Shifting the occlusal plane survey center (OPSC) on the long arc of anterior survey line until the most acceptable line and occlusal plane is found.

Figure 8. The line represents the height of buccal cusp tips.

Figure 9. This represents the height of the buccal cusps after teeth have been prepared.

technique is through the use of Broadrick occlusal plane analyser. It permits reconstruction of occlusion plane in harmony with anterior and condylar guidance, allowing total posterior tooth disclusion in mandibular protrusion. Its use assumes proper function and esthetic positioning of mandibular incisiors, should the anterior guidance be inappropriate, it must be redesigned prior to use of Broadrick flag. This type of instrument is used in conjunction with Hanau and Denar articulators. It consists of[9]: (1) Card index; (2) Bow compass with graphite leads, an extra center point and a needle point; (3) Scribing knife; and (4) Plastic record cards (Figure 3).

Steps

Mount maxillary cast to the articulator by a facebow transfer and relate mandibular cast to the maxillary in centric relation. Secure the flag to the upper bow of the articulator and snap the plastic sheet onto one side. Insert the lead pencil into one end of the caliper and set at a radius of 4 inches from needle point to lead point. The maxillary cast is removed from the articulator and the point on the lower cuspid (anterior survey point) from which an esthetically pleasing occlusal plane would emanate is located. It will fall somewhere between the tip of the cuspid and distoincisal line angle. Generally speaking, flatter the cusp tip, closer the point will be to the line angle. The more pointed the cuspid, closer the survey point will be to the cusp tip. The needle point of the caliper is placed against the selected point on the cuspid and an arc is scribed on the flag. This arc will be referred to as the anterior survey line (Figure 4).

Now select the posterior survey point (PSP) at the distobuccal cusp of the last lower molar and scribe an arc (Figure 5). Needle7 noted that to ensure posterior disclusion on mandibular protrusion, the curve should extend through the condyle. When the PSP is located, the level and orientation of the distal molar tooth may not always be suitable. Should this be the scenario or should no molars exist, an alternate is a position of condyle represented by condylar element of the articulator. Position the center point of the compass on this condylar posterior survey point (CPSP.) and apply an arc to intersect the arc formed from the ASP (Figure 6). This arc will be referred to as the condylar survey line.

Figure 10. Occlusion plane cutting guide.

Figure 11. A cutting guide is placed snugly against the buccal surfaces of the dried teeth and a pencil line is drawn on the teeth according to the guide.

Figure 12. Altering the length of the radius of the curve.

The survey center for scribing the occlusal plane on the lower model is usually at the point where the lines intersect. To determine the acceptability of intersect as a survey center, calipers are turned around and sweep the needle point on the occlusal surfaces of the lower posterior teeth to see how the arc conforms to the existing occlusion plane. Shift the occlusal plane survey center (OPSC) on the long arc of anterior survey line, until the most acceptable line and occlusal plane is found (Figure 7). To raise the line and plane of occlusion at the distal end, move the center point anterior to the arc intersection. To lower the line and plane of occlusion, move the center point posterior to the arc intersection.

When an acceptable height has been established for the lower distal tooth, a line is scribed on the lower model from that tooth forward to the cuspid. This line will represent the height of buccal cusp tips (Figure 8).

To determine the preparation line, the calipers are opened an amount equal to the desired occlusal thickness of the proposed restoration (usually about 1.5 mm) and a second line is scribed. This will represent the height of the buccal cusps after teeth have been prepared (Figure 9).

Now some softened base plate wax is adapted to the buccal surfaces of the model and is cut carefully back to the preparation line, it is also trimmed along the mucobuccal fold line so that the wax can be fitted accurately in the mouth against the teeth. This is called occlusion plane cutting guide (Figure 10).

When the lower posterior teeth are to be prepared, cutting guide is placed snugly against the buccal surfaces of the dried teeth and a pencil line is drawn on the teeth according to the guide (Figure 11). Wax is removed and entire occlusal surface of each tooth is reduced down to the preparation line. The preparation should be about 1.5mm lower on the lingual than it is on the buccal to accommodate for the curve of Wilson. After reduction for proper cusp height has been completed, it is still necessary to reduce the central groove area to permit correct cusp-fossae contouring of the restorations. After occlusion reduction has been accomplished, the preparation is completed according to the predetermined treatment plan.

Same procedure can also be used most effectively to establish the correct occlusion plane on the wax patterns. By using special wax cutting blade in the caliper, the over waxed pattern can be cut back to the correct height. The angle of the blade automatically produces an acceptable curve of Wilson, making the lingual cusps lower than the buccal cusps. Once the occlusion plane has been established on the wax patterns, the locations of the cusp tips, the carving of buccal and lingual anatomy, and contouring of fossae, ridges and grooves can be accomplished easily and accurately.

When the occlusion plane is predetermined before the preparation of the teeth there is no need to make anything other than the most minor occlusal adjustment on the finished restoration. However, dentists must record condylar guide angle at the beginning of the treatment to verify the outcome of the treatment plan and to do any adjustments if needed later on.

Discussion

The Broadrick flag is a useful tool in prosthodontic and restorative dentistry, as it identifies the most likely position of the center of curve of Spee.[10] However, In unusual cases like in small arches, where there is an extreme curve to the occlusal plane occurring naturally,

a standard 4-inch curve would result in a flat posterior curve. This flat posterior surface presents no major problems, since it cannot interfere with the basic requirement of protrusive and balancing side disclusion. However, it can create a poor esthetic results, can cause excessive stress on the upper teeth by requiring an unfavourable crown-root ratio, and could conceivably reduce function in some mouths by causing too much separation of the posterior teeth in protrusion. Conversely, a 4-inch curve would create a steep posterior curve in patient with a class III skeletal relationship, leading to further posterior interferences. Compromise can be made by altering the length of the radius of the curve. This effect can be achieved by varying the center of curve. The center should always lie along the long arc drawn from the anterior survey point and may be moved in anterior or posterior direction from the intersection of this arc. This alteration will not affect the position of the anterior survey point, an important fact when the position of the mandibular anterior teeth is esthetically and functionally suitable (Figure 12).

Such cases are rare and their uniqueness will be readily apparent to anyone who understands the basic requirements of an acceptable occlusal plane.

Summary

The Broadrick flag is a valuable tool to locate an acceptable plane of occlusion. By using this, the prosthodontist can predictably produce high-quality restorations in harmony with anterior and posterior guidance without posterior interferences in mandibular excursions.

References

1. Dawson PE. Evaluation, diagnosis and treatment of occlusal problems. 2nd ed. St. Louis: Mosby, 1989.
2. Spee FG. Die Verschiebungsbahn des Unterkiefers am Schadel. Arch Anat Physiol1890;16:285–94.
3. Monson GS. Occlusion as applied to crown and bridgework. J Nat Dent Assoc1920;7:399–413.
4. Williamson EH, Lundquist DO. Anterior guidance: its effect on electromyographic activity of the temporal and masseter muscles. J Prosthet Dent1983;49:816–23.
5. Wilson GH. A manual of dental prosthetics. Philadelphia: Lea & Febiger, 1911.
6. Shilinburg HT, Hobo S, Whitsett LD. Fundamentals of fixed prosthodontics. 3rd ed. Chicago: Quintessence;1997:85-86.
7. Needles JW. Practical uses of the curve of spee. JADA1923;10:918–27.
8. Needles JW. Mandibular movements and articulator design. JADA1923;10:927–35.
9. Broadrik occlusal plane analyzer.
10. Lynch CD, McConnell RJ. Prosthodontic management of the curve of Spee: Use of the Broadrick flag. J Prosthet Dent 2002;87:593–97.

Obstructive Sleep Apnea: Guidelines For Evaluation, Management, and Long-Term Care
Apnée obstructive du sommeil: Directives pour l'évaluation, la gestion et les soins à long terme

By Dr. Savithri Dattatreya, BDS, MDS; Dr. Ravindra C. Savadi, MDS; Dr Malathi Dayalan, MDS; and Dr. Shweta Pradeep Poovani, MDS

About the Authors

DR. SAVITHRI DATTATREYA, BDS, MDS, is an assistant professor, Department of Prosthodontics, The Oxford Dental College and Hospital, Bangalore, India. Dr. Dattareya can be reached by e-mail at: drsavithri@rediffmail.com.

Dr. Ravindra C Savadi, MDS is a professor and head of the Department Department Of Prosthodontics at The Oxford Dental College and Hospital, Bangalore, India.

Dr. Malathi Dayalan, MDS is a professor in the Department of Prosthodontics at the Oxford Dental College and Hospital, Bangalore, India.

Dr. Shweta Pradeep Poovani, MDS is an assistant professor in the Department of Prosthodontics at the Oxford Dental College and Hospital, Bangalore, India.

ABSTRACT

Obstructive sleep apnea (OSA) is a disturbance in normal sleep patterns which when combined with daytime symptoms, is termed obstructive sleep apnea syndrome. Patients with undiagnosed (OSA) represent a major public health problem.

OSA involves blockage of the upper airway during sleep manifested in the patient as snoring. Simple snoring is a common complaint affecting 45% of adults occasionally and 25% of adults habitually. Dental professionals have a unique doctor-patient relationship that allows them to recognize sleep disorders in patients and to co-manage patients having simple snoring and mild to moderate OSA. Diagnosis of OSA includes taking a sleep-oriented history, a physical examination, performing objective testing, and educating the patient. The presence/absence and severity of OSA must be determined before initiating treatment to identify those patients at risk of developing complications of sleep apnea. Once diagnosis is established, the patient should be included in formulating an appropriate treatment strategy that may include positive airway pressure devices, oral appliances, behavioural treatments, surgery, and/or adjunctive treatments. OSA should be approached as a chronic disease requiring long-term, multidisciplinary management.

Obstructive sleep apnea (OSA) is a common disorder that affects at least 2to 4% of the adult population and is associated with serious health consequences.[1,2] Clinically, OSA is defined by the occurrence of daytime sleepiness, nocturnal loud snoring, witnessed breathing interruptions, or awakenings due to gasping or choking in the presence of with at least five obstructive respiratory events (apneas, hypopneas or respiratory effort related arousals) per hour of sleep.[1,3,4] According to The American Academy of Sleep Medicine (AASM) presence of 15 or more obstructive respiratory events per hour of sleep in the absence of sleep related symptoms is also

sufficient for the diagnosis of OSA.[1,5,6] Snoring is a common complaint that affects 45% of adults occasionally and 25% of adults habitually. It has also been identified as a possible risk factor for hypertension, ischemic heart disease and stroke.[1,5]

The primary concern with OSA is the periodic collapse of the pharyngeal airway while sleeping. During apneas caused by obstruction, the collapsed pharynx prevents airflow, which is propagated by the continued effort of the diaphragm to breathe. This causes progressive asphyxia, which increasingly stimulates breathing efforts against the collapsed airway, typically until the person is awakened.[7] As the disorder progresses, sleepiness becomes increasingly irresistible and dangerous and if left untreated is often associated with motor vehicle accidents, poor work performance, occupational accidents and reduced quality of life thus affecting patients on personal, social and, often, professional levels.[7,8]

The dental practitioner can assist the patient at various levels starting with recognition of a sleep related disorder, referral to a physician and in management of the disorder.

Epidemiology

OSA occurs in 2 to 4% of the adult population between the ages of 30 to 60. While sleep apnea does affect children, the etiology, clinical presentation and treatment differs from that of adults.[9] In addition to age-related differences, there also may be genetic,[10] sex and ethnic differences also.[6,8] Sleep-disordered breathing (SDB) occurs in 24% of young-middle aged men and 9% of women and in 70% of older men and 56% of older women.[6]

Etiology

The etiology of OSA is a complex interplay between neural, hormonal, muscular and structural anatomical factors.[8] The upper airway is basically a soft tissue tube, the patency of which is mainly maintained by muscular groups including the tensor veli and genioglossus.[4] The genioglossus receives input that can modify its activity from the sleep/wake centres of the brain, respiratory-pattern-generating neurons, chemoreceptors, and negative pressure receptors in the airway that can modify its activity. When a patient falls asleep in the supine position muscle relaxation causes the base of the tongue to approach the base of the pharynx. This results in reduced air flow which the patient must increase to maintain the required oxygen concentration in the lungs. This increase in airflow velocity causes vibration of the soft palate, which produces snoring.[11]

Predisposing Factors

Obesity (in patients with collar size greater than 16–17 inches and BMR >25) is a major predisposing factor for OSA.[4] In these patients the diaphragm is displaced to a higher and flatter position, decreasing the inspiratory strength of the diaphragm resulting in reduced lung volumes and decreased oxygen stores.[4,12]

Anatomical factors considered to be associated with the presence of OSA include: increased airway length, lateral wall thickness,[4] tongue volume, enlarged palatine tonsil, enlarged uvula, deviated nasal septum, inferiorly displaced hyoid bone as well as skeletal anomalies like retrognathia and micrognathia, are also considered to be associated with the presence of OSA.[11] Habits like smoking, alcohol consumption, and the taking of sedatives may aggravate an existing disorder.

Another predisposing factor for OSA is hormonal. Studies have shown that differing levels of hormones starting from puberty, further modified by later hormonal changes (menopause), affect OSA development.[6]

Clinical Features

Various clinically detectable signs and symptoms may be present in these patients. They may present with sleep restlessness, diaphoresis, choking, and gasping, excessive night drooling of saliva, excessive daytime drowsiness, difficulty in concentration, depression, irritability, xerostomia, memory problems, morning headaches, gastro-esophageal reflux disease, decreased libido, and impotence.[4,8] In severe cases, epileptic attacks, asthma and hypertension have also been reported.[4]

Diagnosis

Dentists should be able to identify potential apnea patients, refer them to a physician for definitive diagnoses and treatment planning, and serve as a part of the treatment team.

The diagnosis of OSA starts with a sleep history that is typically obtained in one of three phases: first, as part of routine health maintenance evaluation, second, as part of an evaluation of symptoms of obstructive sleep apnea, and third, as part of the comprehensive evaluation of patients at high risk for OSA. A thorough physical examination may suggest increased risk which could include the respiratory, cardiovascular, and neurologic systems.[1]

The gold standard for diagnosing OSA involves having the patient complete a polysomnography (an overnight sleep study) conducted in the laboratory.[8]

Noctornal Attended Polysomnogrphy records sleep staging and physiologic variables such as: sleep positioning, respiratory activity, oxygen saturations, blood pressure and ECG.

Unattended polysomnogrphy measures the nasal airflow using a snoring microphone, thoracic and abdominal effort channels, ECG, EOG and pulse oximetry.

Split-Night Polysomnography refers to a single night of unattended sleep testing. In addition to aiding in diagnosis, it also has a therapeutic component namely a nasal continuous positive airway pressure (CPAP) titration, which helps in assessment of a positive airway pressure. It also serves to maintain the patency of the patients airway on the night of the test.

If the PSG reveals the existence of sleep apnea, further diagnostic tests, such as a complete blood count and thyroid function, may be helpful in evaluating these patients.[13]

Apnea is defined as the cessation of airflow: a complete obstruction for at least 10 seconds with a concomitant 2 to 4% drop in arterial oxygen saturation. The definition of hypopnea is thought of as a reduction in airflow of at least 30 to 50% with a drop in oxygen saturation. The apnea-hypopnea index (AHI) is the average number of apneas and hypopneas per hour of sleep.[4]

The severity of OSA is classified based on the patient's AHI (Apnea-Hypopnea Index) into 3 categories: (1) Mild OSA (5–15 events her