


Canadian

Hearing Report

Revue canadienne d'audition

VOL. 13 NO. 1 2018



ISSN: 1718-1860



Published by
ANDREW JOHN
PUBLISHING INC.



andrewjohnpublishing.com

Canadian

Hearing Report

Revue canadienne d'audition

VOL. 13 NO. 1 2018

Editorial Board Members

Madalina Georgescu

Associate Professor, University of Medicine and Pharmacy, Bucharest, Romania.

Alyssa Needleman

Clinical Director and Associate Professor, Department of Audiology, College of Health Care Sciences, Nova Southeastern University, Florida, USA.

Ozlem Konukseven

President of Turkish Society of Audiology & Speech-Voice, Turkey

Georg M. Sprinzl

Professor of Otolaryngology-Head & Neck Surgery and leads the Implant team of the Department of Otolaryngology-Head & Neck Surgery in St. Polten, Lower Austria

Jurek Olszewski

Dean of Military Medical Faculty Medical University of Lodz, Representative of Poland in European Federation of Audiology Societies, Poland.

O. Nuri Ozgirgin

President, The European Academy of Otolology and Neurotology and Vertigo Academy International.

Piotr H. Skarzynski

Associate Professor, World Hearing Center of Institute of Physiology and Pathology of Hearing, Medical University of Warsaw and Institute of Sensory Organs, Warsaw, Poland.

Navid Shahnaz

School of Audiology & Speech Sciences Faculty of Medicine University of British Columbia Vancouver, Canada

Patricia Gaffney

Associate Professor, Department of Audiology, Nova Southeastern University, Florida, USA.

Jackie M. Davie

Associate Professor, Department of Audiology, Nova Southeastern University, Florida, USA.

Erica B. Friedland

Chair and Associate Professor, Department of Audiology, College of Health Care Sciences, Nova Southeastern University, USA.

We welcome any type of article related to audiology and otology. Please send them at

editor.chr@andrewjohnpublishing.com

FEEDBACK:

We welcome your views and comments. Please send them to

hearingreport@andrewjohnpublishing.com

contents

Research

- 1 Hearing Intervention in Early Years
- 2-6 Cochlear Implantation in Patients with Special Situation
- 7-11 Central Vestibular Compensation
- 12-16 Successful Cochlear Implantation under Local Anesthesia and Sedation: A case Report

Follow us on Twitter @hearing_report.

BACK ISSUES CAN BE FOUND AT
WWW.CHR-SEARCH.COM



Published by
**ANDREW JOHN
PUBLISHING INC.**



andrewjohnpublishing.com

Hearing Intervention in Early Years

Ruchita Mehta*

EDITORIAL

Surely, early intervention does make a difference in the life of young ones with special needs, once it is detected. Parents of special children are also aware of the importance of timely intervention. But what if despite all the awareness of the special needs and efforts taken by the parents, things don't go as planned for that special young one? Who and where should we pick to put a finger on? Is it our system where not many concrete regulations are in place in medical world? Is it lack of funding due to which we don't have enough instruments and man power to take the responsibility of achieving the goals of early intervention? Or is it the personnel handling the case on hand, and their lack of motivation to handle the many pending cases waiting in queue? Pick one or all the reasons from the above to suit the best explanation, but nothing justifies to the loss of timely intervention to this young one with Down's syndrome.

Hearing impairment is one of the conditions that may not be detected at the time of birth. Also, not many hospitals are equipped to provide neonatal

hearing screening. In such cases, hearing impairment is not detected until sometime after birth and thus, losing many early years of hearing intervention. A variety of autosomal chromosome abnormalities can affect not only hearing channels but also communication development. One such case is of Down's syndrome, Down's syndrome appears in about 1 of every 800 live births in United States. Besides, the symptoms of hypotonia, mild to moderate mental retardation, characteristic facial features, and hyper flexibility of joints, there are ear abnormalities such as small ear canals and may have conductive or sensorineural hearing loss or both related to Otitis Media. With already so much going on, what if the child is missed out on getting provision of hearing screening at the time of birth in a hospital setting. To add to this plight, when the child is brought for hearing tests, at the age of 3 years, and once again his hearing abilities are not confirmed in a private practice setting. So much is lost on the way to its speech, language and communication development and also in the journey of getting adequate treatment options.

Even if hearing ability could not be confirmed at the time of testing, there are ways to handle the case in many pending cases waiting in queue-

1. The parents of the child should have been given counseling on the testing results.
2. The personnel should have counseled to the parents to do home- training of conditioning the child and re-scheduling for another appointment of hearing testing.
3. Despite all the efforts failing with PTA, personnel could have chosen another hearing test from the various battery of hearing tests that have come into existence in today's time.

So much could have been done in this case; however, it was just left alone with no concrete report nor help. After all the ordeal of last 5 years, the child is brought for speech therapy, he is 8 years old now and is finally going for a thorough hearing check- up, hoping that there wouldn't be any hidden hearing impairment and further loss of time.

Cochlear Implantation in Patients with Special Situation

Hisashi Sugimoto¹, Makoto Ito², Miyako Hatano¹, Hiroki Hasegawa¹, Masao Noda¹, Tomokazu Yoshizaki^{1*}

ABSTRACT

Objectives: We have been using the "Subtotal petrosectomy" or "Canal wall down mastoidectomy" technique for the cochlear implantation of difficult cases. We also added the "Blind sac closure of external auditory canal (EAC)" and "Middle ear and mastoid Obliteration by abdominal fat" technique as necessary.

Methods: Retrospective analysis of seven special cases of cochlear implantation was carried out. The detailed breakdown of the cases is as follows: Post radical mastoidectomy -- 2 cases, Adhesive otitis media -- 1 case, Eosinophilic otitis media -- 2 cases, Temporal bone malformation -- 2 cases. Complications, hearing threshold results, word recognition, and bleeding were analyzed.

Results: For one of the cases of Post radical mastoidectomy, the patient suffered from a breakdown of the EAC closure. The hearing threshold following the procedures ranged from 25 to 35 dB with an average of 30.3dB. The word recognition results were 0 to 96% with an average of 60% and sentence recognition results ranged from 0 to 100% with an average of 62%. The volume of blood loss ranged between less than 5 mL and 170 mL.

Conclusions: The combination of these techniques has potential to be effective for the cochlear implantation of such difficult cases.

KEYWORDS: Petrosectomy, Cochlear implantation, Auditory canal, Post radical mastoidectomy

INTRODUCTION

Patients with profound hearing loss are able to acquire the ability to hear by receiving an operation to emplace a cochlear implant, and this result in a remarkable improvement in their quality of life. As of this time, many patients have enjoyed the benefits of this procedure. For patients in which the middle and inner ear present a normal form and in which there is no pathological change to the temporal bone, the classical facial recess technique is usually used with extremely few resultant complications. Previous studies of the classic technique report major complication rates of between 3.0 and 13.7% [1-4]. On the other hand, there are quite a few difficult cases for which classical facial recess technique for

cochlear implant cannot be employed. Fisch et al. proposed subtotal petrosectomy in 1988, and five years after that Parnes et al. employed this approach for the first time in a difficult cochlear implant case. This procedure involved a closure of the external auditory canal (EAC) and the Eustachian tube and obliteration of the surgical cavity. Following this case, this procedure became the standard cochlear implant method used for difficult cases, and this in turn has led to debate over the usefulness and safety of the procedure [5-14]. However, since the total number of cases is small, the validity and safety cannot be irrefutably established. Thus, it is extremely important to ascertain the as of yet hypothetical usefulness and safety for patients undergoing such special cases of cochlear implant procedures. In this report we present our experiences with seven such special cases of cochlear implants. In this report we wish to

contribute further to the investigation about the safety and suitability so that even if only by a small amount more patients with difficult cases can enjoy the benefit of cochlear implant.

MATERIAL AND METHODS

PATIENTS

We did a retrospective analysis of seven special cases of cochlear implantation carried out in the Department of Otorhinolaryngology at the Kanazawa University Hospital between 2012 and 2016. The detailed breakdown of the cases is as follows: Post radical mastoidectomy -- 2 cases, Adhesive otitis media -- 1 case, Eosinophilic otitis media -- 2 cases, Temporal bone malformation -- 2 cases (Table 1). For the two cases of eosinophilic otitis media subtotal petrosectomy, cochlear implantation, and obliteration of the mastoid using abdominal fat was carried out (Fig. 1).

¹Department of Otolaryngology-Head and Neck Surgery, Kanazawa University Graduate School of Medical Science, Kanazawa, Japan,

²Pediatric Otolaryngology, Jichi Children's Medical Center Tochigi, Jichi Medical University

*tomoy@med.kanazawa-u.ac.jp.

Table 1. Summary of seven special cases.

| Patient | Age | Sex | Side | Etiology | Operative procedure | Complications | Bleeding | Implant | Electrode outside cochlear | Hearing threshold before CI | Hearing threshold after CI | Speech preception (CI2004) | Follow up |
|---------|-----|-----|------|---------------------------|--|-----------------------|----------|---------------|----------------------------|-----------------------------|----------------------------|----------------------------|-----------|
| 1 | 69 | F | Lt | Redical cavity | Simple suture of EAC Canal wall mastoidectomy closure of the eustachian tube | Suture failuer of EAC | 100 ml | Cochlear CI24 | 0/22 | 105dB | 30dB | Word 48% Sentense 61% | 45M |
| 2 | 72 | M | Rt | Redical cavity | Blind sac closure to EAC Canal wall down mastoidectomy middle ear and mastoid obliteration by abdominal fat closure of the eustachian tube | No | <5 ml | Cochlear CI24 | 0/22 | 105dB | 28dB | Word 60% Sentense 40% | 31M |
| 3 | 79 | M | Lt | atelectasis | Subtotal petrosectomy blind sac closure of EAC middle ear and mastoid obliteration by abdominal fat closure of the eustachian tube | No | <5 ml | Cochlear CI24 | 0/22 | 103.8dB | 25dB | Word 64% Sentense 71% | 21M |
| 4 | 64 | M | Lt | Eosinophilic otitis media | Subtotal petrosectomy blind sac closure of EAC middle ear and mastoid obliteration by abdominal fat closure of the eustachian tube | No | 170 ml | Cochlear CI24 | 0/22 | 105dB | 30dB | Word 96% Sentense 91% | 31M |
| 5 | 71 | M | Rt | Eosinophilic otitis media | Subtotal petrosectomy blind sac closure of EAC middle ear and mastoid obliteration by abdominal fat closure of the eustachian tube | No | 50 ml | Cochlear CI24 | 0/22 | 102.5dB | 34dB | Word 60% Sentense 71% | 18M |
| 6 | 9 | M | Lt | Inner ear Malformation | Blind sac closure of EAC Canal wall down mastoidectomy | No | 50 ml | Cochlear CI24 | 0/22 | 105dB | 35dB | Word 0% Sentense 0% | 57M |
| 7 | 41 | M | Rt | Inner ear Malformation | Blind sac closure of EAC Canal wall down mastoidectomy | No | <5 ml | Cochlear CI24 | 0/22 | 97.5dB | 30dB | Word 2% Sentense 100% | 52M |

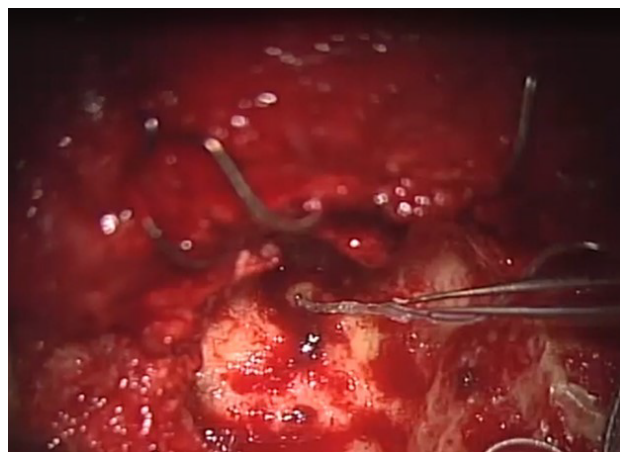


Fig 1. Left ear of patient 4 after subtotal petrosectomy. A good field of view and ample working space was ensured.

For one of the two cases of post radical mastoidectomy closure of the external auditory canal using blind sac closure, cochlear implantation, and obliteration of the mastoid using abdominal fat were carried out (Fig. 2). For the other case of

Post radical mastoidectomy, the external auditory canal was closed, but blind sac closure was not used. Mastoid obliteration was also not performed. For a case of Adhesive otitis media, canal wall down mastoidectomy, cochlear implantation,

and mastoid obliteration using abdominal fat were carried out. For the two cases of Temporal bone malformation, closure of the external auditory canal using blind sac closure, canal wall down mastoidectomy and cochlear implantation were carried

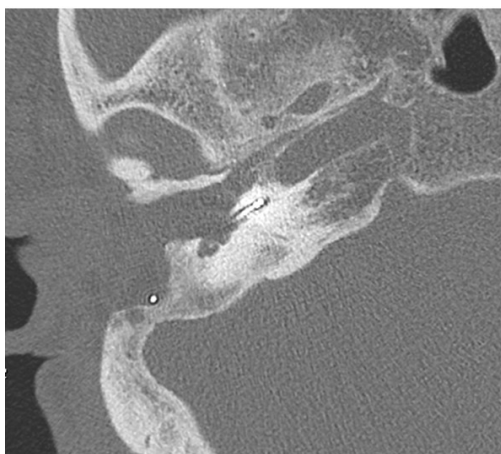


Fig 2. Postoperative CT scan of Patient 2 (right ear).

out. Obliteration of the mastoid was not carried out. Complications, hearing threshold results, word recognition, and bleeding were the four items analyzed in these seven cases. Permission for this retrospective study was obtained from the Kanazawa University Hospital, the local Ethics Committee approved the study protocol. Informed written consent was obtained from all patients.

RESULTS

The average period of observation was 36.4 months. Six of the patients were male, and one was female. Patient age ranged from nine to 79 years with an average age of 57.9. All of the surgical techniques employed in each case were carried out as one combined operation. For all of the cases cochlear implantation was performed using Cochlear CI24 with zero electrodes outside of the cochlear. For one of the cases of Post radical mastoidectomy the patient suffered a breakdown of the EAC closure. In this case ear discharge continued for three months following the procedure, but this complication disappeared with the EAC finally closing again naturally. In this case blind sac closure was not performed and the middle ear and the mastoid were not obliterated. There were no complications in any of the other cases. Hearing threshold results following the procedures ranged from 25 to 35dB with an average of 30.3dB. Word recognition results were 0 to 96% with an average of 60% in the case of words, and 0 to 100% with an average of 62% in the case of sentences. The volume of blood loss

varied between less than 5 mL and 170 mL. Blood transfusion was not required in any of the cases.

DISCUSSION

We have used the "Subtotal petrosectomy" or "Canal wall down mastoidectomy" technique to approach for kinds of difficult cases related to cochlear implantation. A detailed discussion of the cochlear implant technique as it was applied in each of these four clinical states follows.

EARS AFTER RADICAL MASTOIDECTOMY

Of the two cases of ears following radical mastoidectomy in this study, there was a suture failure of the EAC in the first case. In this case we didn't use the blind sac closure technique when suturing the EAC. Furthermore, obliteration of the mastoid was not carried out. Since the diameter of the EAC following radical mastoidectomy is larger as compared to that of a normal EAC, a simple suturing of the EAC may lead to imperfect closure. Fisch considered the EAC suturing using blind sac closure to be a safe, effective procedure [15]. It is also an advisable application when carrying out cochlear implantations in radical cavities. In the second case, the lateral semicircular canal in the right ear had been destroyed in a previous operation. Prior to this operation a caloric test was conducted and CP (canal paresis) was pointed out. Due to this and in order to preserve vestibular function, an operation was carried out on the previously destroyed lateral semicircular canal in the right ear.

The period of hearing loss in the right ear had been long, but following the operation an improvement in the hearing level of up to 25dB was attained. The canal paresis on the right side caused a remarkable reduction in the patient's QOL. Therefore, despite the long period of hearing loss, it is recommended to proceed with caution.

ADHESIVE OTITIS MEDIA

Xenellis et al. reported about cochlear implantations for four patients who were suffering from adhesive otitis media. They concluded that Blind-sac closure of the external auditory canal without obliteration is a rather safe surgical procedure in cases with atelectasis, and a 2-stage procedure may not always be necessary and indeed might best be limited to those patients who have active inflammatory disease at the time of the primary procedure [16]. The cases that we dealt with in this study had no inflammation, so the operations were carried out as single, comprehensive procedures. There were no complications in these cases. The difference between our cases and those reported by Xenellis et al. was as concerns the inclusion of Mastoid obliteration. We perform mastoid obliteration to prevent hemorrhage effusion and prevent infection in the post-operative dead space. However, we believe that the most important purpose of mastoid obliteration is to counter post-operative spinal fluid leakage. It is not necessarily always required to take these precautions in cases of adhesive otitis media in which these risks are not present. In order to determine which is

best, more reports from further cases are required. In the cases related to this study a caloric test was carried out, the absence of canal paresis was confirmed, and the operative side was selected. Similar to the cases of mastoidectomy, we feel that consideration of the vestibular function in cases of adhesive otitis media is important for selecting the operative side.

EOSINOPHILIC OTITIS MEDIA

In this study there were two cases of eosinophilic otitis media for which cochlear implantation was performed. The surgical procedure was a subtotal petrosectomy. The concepts of the surgery consist of the following two points: (i) Removal of mucosa from the middle ear and the mastoid cavity as completely as possible in order to remove the theater of eosinophilic infiltration; (ii) Closure of the Eustachian tube and the external auditory canal in order to prevent leaching of foreign substances and entry of stimuli which are the cause of eosinophilic inflammations. There were no complications or recurrent inflammation following surgery in the cases of both patients. Following the procedure, the hearing threshold results of the two patients were 30dB and 34dB [17]. This is the first discussion focusing on cochlear implantations for cases of eosinophilic otitis media. To further confirm the efficacy and safety of our surgical concept, we need to administer this treatment concept for a larger number of cases in a future study.

TEMPORAL BONE MALFORMATION

As for the cases of temporal bone malformation, because the anatomical landmark cannot be trusted, the identification of the place to open the cochlea is problematic. Furthermore, in cases of temporal bone malformation it has been reported that carrying out the cochleostomy can result in gushers. Therefore, for temporal bone malformation cases we feel it is critical to ensure that there is a good operative field of view and ample working space. Canal wall down mastoidectomy technique resolves these two problems. Mistakes in the location for opening the cochlea are reduced. What's more, the measures for dealing with gushers become much easier.

In the first temporal bone malformation case in this study, the first operation employed was a classical facial recess technique. However, due to a traveling abnormality of the facial nerve and a deformity in the inner ear, we couldn't identify the location to open the cochlea. In the second operation a subtotal petrosectomy was employed resulting in a good operative field of view. Thus, we could open the cochlea. Therefore, we think that in cases of temporal bone malformation this canal wall down technique is extremely useful for cochlear implantation.

SUBTOTAL PETROSECTOMY AND CANAL WALL DOWN MASTOIDECTOMY

Ensuring a good operative field and ample working space are two common, important points when performing cochlear implantation for special cases. Use of subtotal petrosectomy and canal wall down mastoidectomy can overcome difficulties related to these two points. Also, closure of the Eustachian tube and the EAC can isolate them from the exterior preventing operation related infection [18]. Thus we feel that for special cases this is a useful procedure.

STAGED OPERATION

Linder et al. recommended a staged operation for cases with the following four conditions: 1. Suppurative and continuously draining otitis media, 2. Previous tympanomastoid surgeries with "unstable" disease, 3. Extended cholesteatomas, and 4. Previously irradiated temporal bone [14]. We regard this strategy as appropriate. For the cases in this study none of these four conditions applied. Thus, a single operation was selected. There were no severe complications.

MASTOID OBLITERATION

Whether or not to employ mastoid obliteration is an essential topic that must be discussed. In cases where mastoid obliteration is employed, the choice of the obliterating materials is also an important issue. We feel that it is necessary to fill the mastoid space in cases for which post-operative inflammation is possible. We especially feel that in cases in which

dura mater is exposed or in which there is CSF leakage, filling the mastoid space is necessary. Following radical mastoidectomy, eosinophilic otitis media, and adhesive otitis media, amongst other conditions, it is favorable to fill the mastoid space to prevent inflammation caused by exuded liquid or blood. On the other hand, in cases such as temporal bone malformation in which there has been no inflammation and the dura mater or CSF leakage is not occurring, filling the mastoid space is not necessary. Previous reports indicate that for blood flow in the temporal muscle, abdominal fat is the filling material used. Hellingman suggests that the most suitable material to obliterate the cavity appears to be abdominal fat because of its resistance to necrosis and easy removal if cochlear implantation is performed later. On the other hand, Fisch et al. propose that, after subtotal petrosectomy, if dura mater exposure or CSF leakage are involved and there is inflammation, then the temporal muscle with blood flow or the sternocleidomastoid muscle should be adopted [15]. For our cases in this study there was no exposure of dura mater nor was there any CSF leakage involved, so abdominal fat was adopted as the filling material, and there were no post-operative complications.

VESTIBULAR FUNCTION

When selecting on which side to perform the procedure, evaluation of the vestibular function is essential. Especially in cases of Radical cavity or ears following inner ear procedures, it is necessary to administer the caloric test and confirm the presence or absence of paralysis of the semicircular canal. Bilateral loss of vestibular function is a complication that must be avoided, and we believe this takes priority over post-operative hearing acquisition. We think that compared to more mainstream cases, cochlear implantation following radical mastoidectomies and other special cases can result in a higher risk of deterioration of vestibular function, so as much as possible it is necessary to make pre-operative evaluations.

CONCLUSION

We have performed cochlear implantations in cases of Radical cavity,

Adhesive otitis media, Eosinophilic otitis media, and Temporal bone malformation. For all of the cases subtotal petrosectomy or canal wall down mastoidectomy was applied. We also added the "Blind sac closure of EAC" and "Middle ear and mastoid Obliteration by abdominal fat" technique as necessary. As a result of the combination of these methods, a good field of view and ample working space were ensured. Except for EAC breakdown, there were no complications. Hearing threshold results and word recognition were markedly improved following the operation, and blood loss volume was extremely small. In the future we hope to increase the number of patients with special cases who will receive the benefits of this cochlear implant method.

REFERENCES

1. Proops DW, Stoddart RL, Donaldson I (1999) Medical, surgical and audiological complications of the first 100 adult cochlear implant patients in Birmingham. *The Journal of Laryngology & Otology* 113: 14-17. doi: 10.1017/s002221510014602x PMID: 10664723
2. Hoffman RA, Cohen NL (1995) Complications of cochlear implant surgery. *The Annals of otology, rhinology & laryngology. Supplement* 166: 420-422. PMID: 7668733
3. Collins MM, Hawthorne MH, El-Hmd K (1997) Cochlear implantation in a district general hospital: problems and complications in the first five years. *The Journal of Laryngology & Otology* 111: 325-332. doi: 10.1017/s0022215100137235 PMID: 9176612
4. Aschendorff A, Marangos N, Laszig R (1997) Complications and reimplantation. *Advances in Oto-Rhino-Laryngology* 52: 167-170. doi: 10.1159/00058982
5. Hellingman CA, Dunnebie EA (2009) Cochlear implantation in patients with acute or chronic middle ear infectious disease: a review of the literature. *European Archives of Oto-Rhino-Laryngology* 266: 171-176. doi: 10.1007/s00405-008-0828-0
6. Baranano CF, Kopelovich JC, Dunn CC, Gantz BJ, Hansen MR (2013) Subtotal petrosectomy and mastoid obliteration in adult and pediatric cochlear implant recipients. *Otology & Neurotology* 34: 1656-1659. doi: 10.1097/mao.0b013e3182a006b6 PMID: 24136310
7. Basavaraj S, Shanks M, Sivaji N, Allen AA (2005) Cochlear implantation and management of chronic suppurative otitis media: single stage procedure?. *European Archives of Oto-Rhino-Laryngology* 262: 852-855. doi: 10.1007/s00405-004-0907-9 PMID: 15756568
8. Pasanisi E, Vincenti V, Bacciu A, Guida M, Berghenti T et al. (2002) Multichannel cochlear implantation in radical mastoidectomy cavities. *Otolaryngology-Head and Neck Surgery* 127: 432-436. doi: 10.1067/mhn.2002.129822 PMID: 12447237
9. Babighian, G (1993) Problems in cochlear implant surgery. *Advances in Oto-Rhino-Laryngology*, 48: 65-69. doi: 10.1159/000422560
10. Axon PR, Mawman DJ, Upile T, Ramsden RT (1997) Cochlear implantation in the presence of chronic suppurative otitis media. *The Journal of Laryngology & Otology* 111: 228-232. doi: 10.1017/s0022215100136977 PMID: 9156058
11. Leung, R, Briggs RJ (2007) Indications for and outcomes of mastoid obliteration in cochlear implantation. *Otology & Neurotology* 28: 330-334. doi: 10.1097/mao.0b013e318031161f PMID: 17414038
12. Issing PR, Schonermark MP, Winkelmann S, Kempf HG, Ernst A (1998) Cochlear implantation in patients with chronic otitis: indications for subtotal petrosectomy and obliteration of the middle ear. *Skull base surgery* 8: 127-131. doi: 10.1055/s-2008-1058571 PMID: 17171047
13. Polo R, Del Mar Medina M, Aristegui M, Lassaletta L, Gutierrez A, et al. (2015) Subtotal Petrosectomy for Cochlear Implantation: Lessons Learned After 110 Cases. *The Annals of otology, rhinology, and laryngology* 25: 485-494. doi: 10.1177/0003489415620427 PMID: 26658067
14. Szymanski M, Ataide A, Linder T (2016) The use of subtotal petrosectomy in cochlear implant candidates with chronic otitis media. *European archives of oto-rhino-laryngology* 273: 363-370. doi: 10.1007/s00405-015-3573-1 PMID: 25708413
15. Fisch U, Mattox, D (1998) Microsurgery of the skull base. Thieme.
16. Xenellis J, Nikolopoulos TP, Marangoudakis P, Vlastarakos PV, Tsangaroulakis A, et al. (2008) Cochlear implantation in atelectasis and chronic otitis media: long-term follow-up." *Otology & neurotology* 29: 499-501. doi: 10.1097/MAO.0b013e31816a8986 PMID: 18520585
17. Sugimoto H, Hatano M, Noda M, Hasegawa H, Yoshizaki T (2016) Cochlear implantation in deaf patients with eosinophilic otitis media using subtotal petrosectomy and mastoid obliteration. *European archives of oto-rhino-laryngology* 274: 1173-1177. doi: 10.1007/s00405-016-4091-5 PMID: 27168402
18. Polo R, Del Mar Medina M, Aristegui M, Lassaletta L, Gutierrez A, et al. (2015) Subtotal Petrosectomy for Cochlear Implantation: Lessons Learned After 110 Cases. *The Annals of otology, rhinology, and laryngology* 125 (2015): 485-494.

Central Vestibular Compensation

Madalina Georgescu*

ABSTRACT

Vestibular system is one of the three sensorial systems involved in equilibrium. Any lesion at this level has consequences on quality of life, in terms of dizziness and/or disequilibrium or ataxia. Unilateral vestibular loss (UVL) represents a stable permanent peripheral vestibular lesion with long-term effects and symptoms. These symptoms are caused by lower than normal gains of vestibulo ocular and vestibulospinal reflexes secondary to UVL. Central vestibular compensation is a natural healing model for UVL, based on the neuroplasticity of the central vestibular structures. It is a long-lasting and incomplete phenomenon, but it enables a comfortable daily life. It can be accelerated and enlarged by customised vestibular rehabilitation programmes and appropriate drug treatment.

KEYWORDS: Unilateral vestibular loss, Central vestibular compensation, Neuroplasticity, Vestibular rehabilitation

INTRODUCTION

Equilibrium is essential for normal daily life. It allows normal walking, performing basic activities (housekeeping, grocery, and working) without risk of fall and injury. Three sensorial systems are involved in this process, a real network based on normal sensorial input and good matching in between the information: somatosensorial, visual and vestibular system. Disequilibrium worsen the health-related quality of life (HRQoL) with a negative impact on their social life and work performance, leading not only to psychological damage (low self-confidence, depression, frustration), but also economic losses (long medical leave, poor concentration, and performance).

Briefly, from anatomical point of view, it is important to know that the peripheral vestibular system includes five sensorial structures for each inner ear, three ampullary cristae and two maculae. The ampullary crista is located in the ampule of each semi-circular canal (horizontal, superior and posterior) and senses angular movements of head or body due to their position-perpendicular one to each other, so in all directions of the three-dimensional space we are living in. The maculae are located one in the utricle and one in the saccule and senses

linear movements due to the otolithic membrane which increases specific weight of the maculae, compared with endolymph density (fig. 1).

From these sensorial structures, information is transmitted in the vestibular nerve in a very specific manner – horizontal and superior semi-circular canals ampullary cristae and utricular macula are connected to the superior vestibular nerve and posterior semi-circular canal ampullary crista and saccular macula are connected to the inferior vestibular nerve (fig. 2).

Vestibular nuclei are made up of a group

of neurons placed on the floor of the IV ventricle, laterally bounded by the restiform body, ventrally by the nucleus and spinal tract of the trigeminal nerve, and medially by the pontine reticular substance. From the anatomical point of view, four groups of neurons can be identified: medial, lateral, superior and inferior. Although there is overlapping, most of the fibers in the utricle and saccule reach the lateral and inferior nuclei, and most of the fibers coming from the semi-circular canals reach the upper and middle nuclei.

Vestibular nuclei receive information from

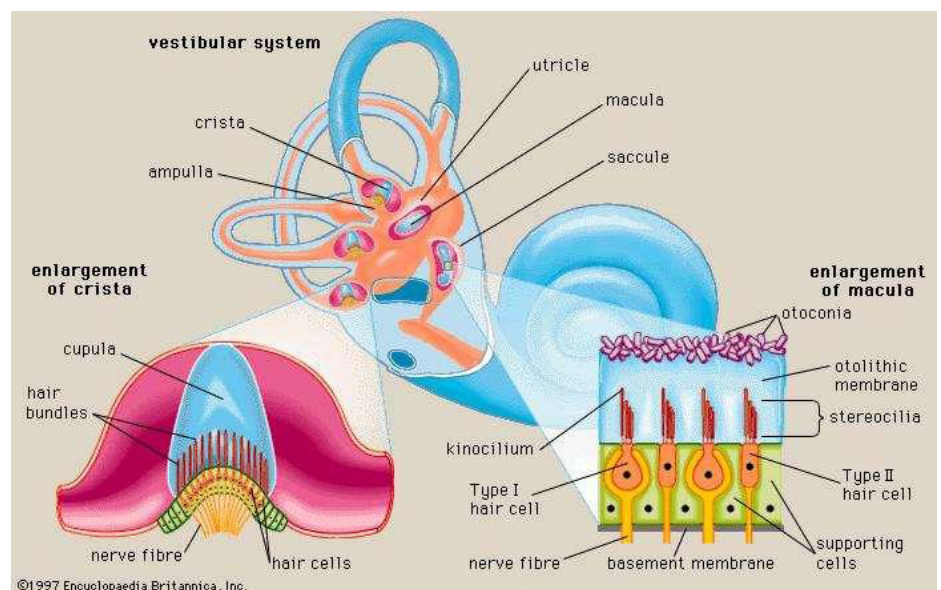


Fig. 1. Sensorial vestibular structures in the inner ear *Encyclopedia Britannica*.

University of Medicine and Pharmacy 'Carol Davila' Bucharest, Romania

*madalina.georgescu@gecad.com

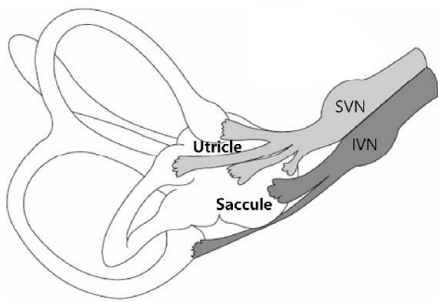


Fig. 2. Vestibular nerve.

the cerebellum, spinal cord, and adjacent reticular substance, in addition to the information received from the vestibular afferent fibers projections. Also, there are many commissural fibers linking the two groups of vestibular nuclei (right and left). Based on the combined connections between afferent and afferent fibers, the lateral and inferior vestibular nuclei are important linking stations in vestibulo-spinal reflex control, while upper and middle nuclei are critical stations in the control of vestibulo ocular reflexes (fig. 3).

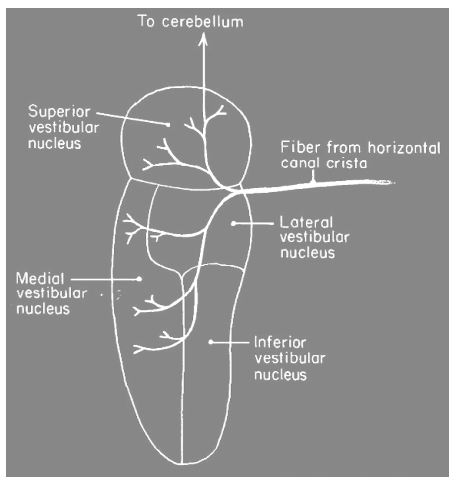


Fig. 3. Vestibular nuclei.

Vestibular system is anatomically developed at birth, but it gets functional in the child's first year of life. While getting control on his neck muscles, crawling, standing, and walking, vestibular cortex develops reaction patterns specific to each movement activity. Based on these patterns, equilibrium is a subconscious process as long as vestibular system works normally and sense motion of head and body and uses this information to control movement and posture. This is based on rest discharging rate from vestibular hair cells and changes in firing rate secondary to rotations which stimulates the inner

towards the movement is performed and inhibits the other ear (fig. 4).

Vestibular lesions impede on this normal reaction and patients experience disequilibrium, vertigo or dizziness. Loss of peripheral vestibular function induces an asymmetry in vestibular sensorial discharge (lesion in the inner ear) or in vestibular ganglia cells activity (in neural lesions). This asymmetry reaching the vestibular nuclei level is interpreted as a rotation towards the part with higher activity, so vertigo sensation and accompanying nystagmus appears.

In unilateral vestibular lesions (UVL) a central process becomes available – central compensation, which aims regaining symmetry between the two vestibular pathways.

Vestibular system ensures equilibrium by two different reflexes-vestibuloocular and vestibulospinal reflex which enables an **oculomotor effect** (stable image on the retina while movement), a **postural effect** (head aligned with body, vertical stance, and walking) and also an appropriate cortical **perception** (verticality, orientation in space). All these three have to be taken into account when assessing a vestibular lesion, because when vestibular pathways become imbalanced, they do not react fully to head, or body movements and pathological symptoms related to all three effects should be addressed in management of UVL.

There are three main categories of UVL- stable deficit (like vestibular neuritis), fluctuant deficit (like in Menière disease) and slowly progressive deficit (like

in vestibular schwannoma/acoustic neurinoma).

Central vestibular compensation process acts only in stable deficits with sudden onset or progressive course and it is visible and very important for recovery in sudden UVL with total vestibular impairment (complete vestibular neuritis, for example). Fluctuant vestibular function cannot trigger central compensation because of irregular error signals coming from the affected ear (Menière disease or vestibular paroxysmia). ENTE UVL leads to two main different categories of impairments: **static** and **dynamic vestibular deficit**.

Static deficits are present from the very beginning of the lesion onset due to asymmetry in vestibular nuclei activity, are very severe as symptoms and characteristic signs are present without any head or body movement. They resume completely at most in one week. Static deficit signs are:

- Oculomotor reaction – spontaneous nystagmus, skew-deviation (vertical misalignment of the eyes).
- Postural reactions – postural asymmetry (head and/or body tilt), ocular-tilt reaction (fig. 5) (OTR=skew-deviation, head tilt and ocular torsion), severe imbalance.
- Perception signs – vertigo, subjective vertical deviation.

Dynamic deficits appear due to changes in the vestibular reflexes gain and are present only during head movements. Their highest degree of severity is at one week after the UVL onset, but they

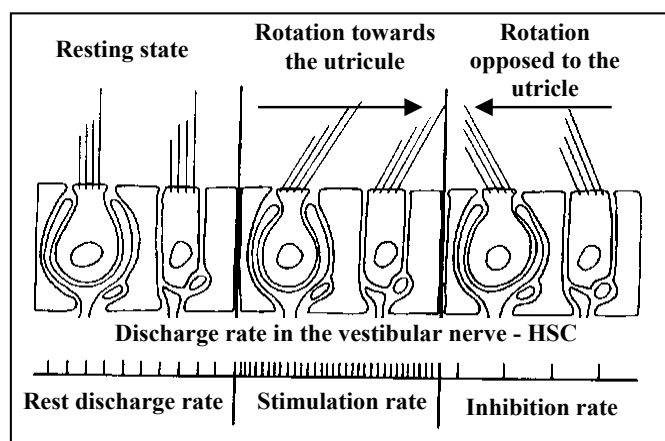


Fig. 4. Changes in firing rate from hair cells in horizontal semi-circular canal (HSC).




Fig. 5. Ocular tilt reaction.

last for longer periods (one year) and might never be fully compensated in the recovery process. For example, high frequency movements of the head (over 2Hz) might always induce dizziness and disequilibrium. Head-shaking induced nystagmus is used to assess long-term level of recovery of the UVL.

Dynamic deficit signs are present from all three vestibular effects mentioned:

- Oculomotor signs – diminished vestibuloocular reflex induces limitations in head's velocity movements due to movement-induced visual disturbances and secondary dizziness.
- Postural signs – decreased gain of vestibulospinal reflex leads to weaker balance skills, ataxia, and gait disturbances which all induce behavioural changes in order to minimise the risk of fall: stance becomes conscious, a voluntary act, patients are more cautious while moving and former daily activities like running, jumping, high heights activity, sports in general are limited.
- Perception signs of vestibular dynamic deficit might include spatial disorientation, oculo-gravitational illusions (objects are tilted, corners appear rounded) or incorrect perception of acceleration (patients develop motion sickness).

All these dynamic deficits lead to avoidance behaviour to sudden or challenging movements, difficulties in tender, subtle or complex motor activities.

Vestibular compensation, known as **CENTRAL COMPENSATION** is a central nervous system process for physiological healing after a vestibular deficit, aiming to reinforce symmetry in vestibular

pathways' tone and to readjust the gain of vestibular reflexes in order to equal gain I, as in healthy persons. Of course, any lesion of the central vestibular structures involved in central compensation process (vestibular nuclei, thalamus, limbic system, vestibular cortical areas, or cerebellum) impairs recovery of the UVL [1-3]. For this reason, central vestibular compensation research focussed mainly on peripheral vestibular lesions.

Vestibular central compensation is a model of neuroplasticity phenomena which allows spontaneous recovery after a UVL (fig. 6). In complete unilateral vestibular deficit, central compensation is a long-lasting process (over three months), imperfect and incomplete (high acceleration or velocity head movements are not always compensated). This natural recovery process can be improved and accelerated by vestibular rehabilitation programmes and appropriate drug treatment.

In sudden UVL, the following changes occur in the vestibular pathway [4-9]:

A. High asymmetry between the two vestibular nuclei complex in the acute phase due to:

- a. Inactivity on the lesion side.
- b. Increased resting discharge rate on the contralateral side due to lack of inhibitory feedback from the injured side through the flocculus (commissural inhibitory inputs are removed by the UVL) [10,11].

B. Regaining symmetry in vestibular nuclei resting discharge by:

- a. Regeneration of a new basic discharge on the lesion side through various mechanisms [12,13]:

- i. Opening of existing synapses in the ipsilateral peripheral vestibular structures.
- ii. New sprouting in the peripheral vestibular pathway.
- iii. Recovery and maintenance of the medial vestibular nucleus spontaneous activity on the lesion side in chronic stage of the UVL by slowing down the inhibitory cerebellar activity and activation of the vestibular-hypothalamic-vestibular loop.
- iv. Adaptive changes in the sensitivity of central vestibular neurons to inhibitory neurotransmitters.
- v. Changes in the intrinsic cell membrane properties of the vestibular nuclei neurons.
- vi. Higher density receptors on vestibular nuclei surface; both last two mechanisms reflect the internal rebalancing of the vestibular brainstem related to internal feedback loops.
- vii. Inhibition of the resting discharge rate in contralateral medial vestibular nucleus during acute phase of sudden UVL through high cerebellar inhibitory signals.

The effect of central compensation differs greatly between static and dynamic symptoms. Static oculomotor, postural and perception signs are rapidly and completely compensated due to important recovery of spontaneous resting firing rate in the ipsilateral vestibular nuclei, denervation hypersensitivity to vestibular input in the vestibular nucleus and greater reliance on commissures, deep cerebellar nuclei, and inferior olive. This occurs immediately after the acute onset of the UVL and for this reason patients must move their head as soon as possible and they must not stay still in bed more than 2-3 days after the onset of the vestibular lesion.

Dynamic symptoms evolution is very different-in significant much longer period of time (one year, even) symptoms compensate variably due to different methods of compensation involved in recovery and also because functional changes occur in cerebellum and hippocampus, anatomical structures with huge influence on central compensation process. Recent studies showed the importance of otolithic system

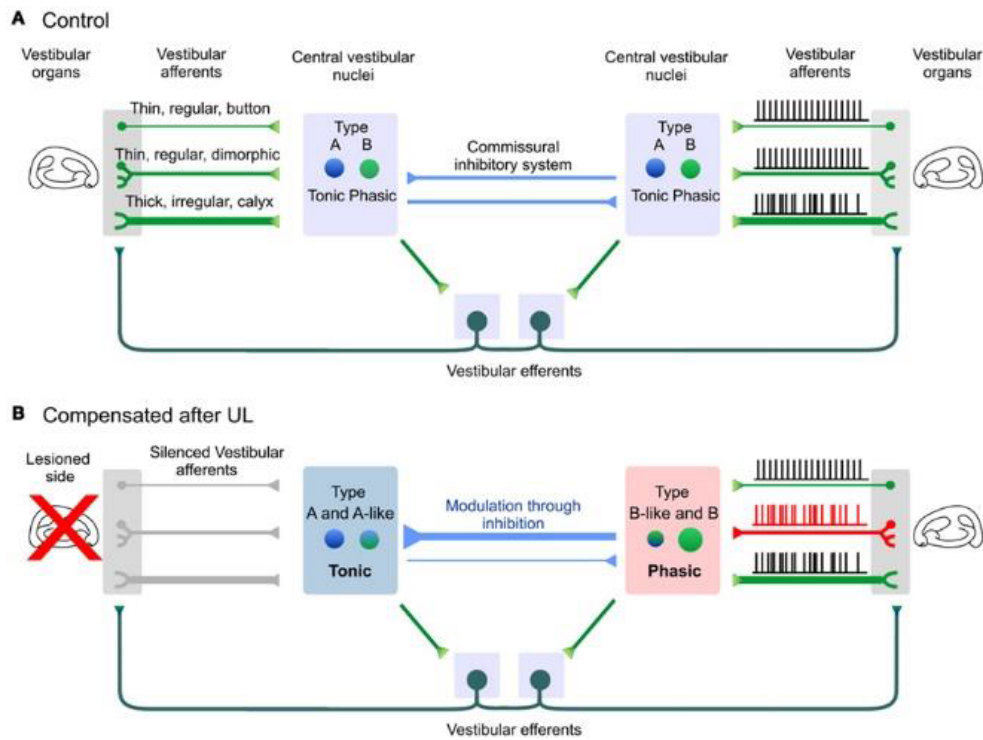


Fig. 6. Central vestibular compensation (with Mylan Company permission).

in facilitating the central vestibular compensation [14-16].

The degree of central compensation depends on the severity degree of stable vestibular lesion, quantified by caloric, head-impulse (HIT) and vestibular evoked cervical myogenic potentials (cVEMP) test. Caloric reflexivity and HIT allows evaluation of the superior vestibular nerve function and cVEMP of the inferior vestibular nerve (fig.7). Dynamic vestibular symptoms are better compensated (disappearance of head-shaking induced nystagmus and of motion-induced dizziness) when initial vestibular deficit is smaller (lower caloric canal paresis and lower asymmetry in cVEMP's amplitude). Recovery is best for low velocities and/or accelerations, maybe due to saturation phenomena or substitution strategies used for regaining equilibrium [17-20].

As previously mentioned, central compensation of dynamic symptoms involves multiple processes:

- Restoration of peripheral function.
- Compensatory readjustments of brainstem vestibular processing.
- Sensorial substitution of the impaired vestibular function by other sensorial

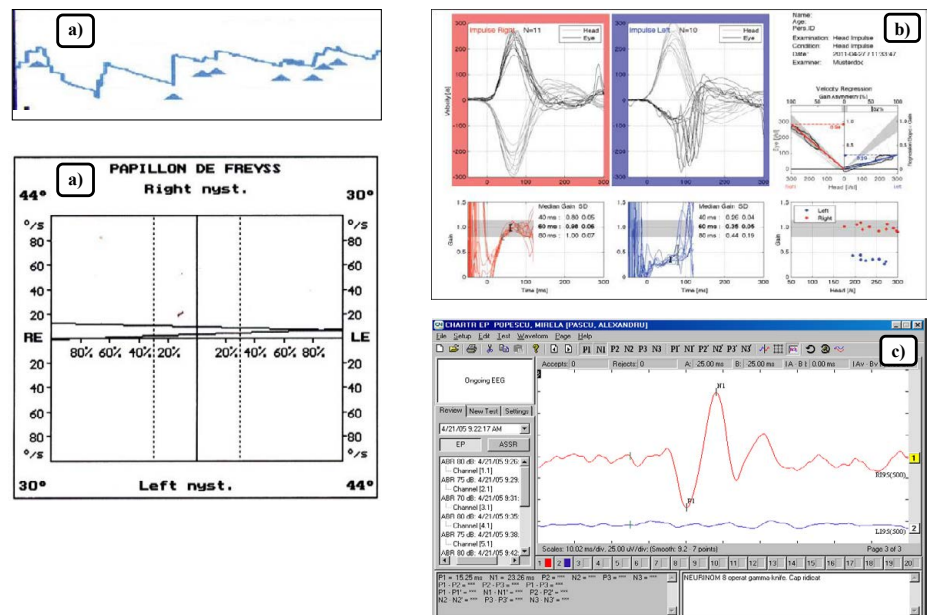


Fig. 7. Pathological results in a patient with left complete UVL:
 a) 100% caloric paresis and right-beating spontaneous nystagmus.
 b) positive HIT test on left ear - (gain<0.7, "overt" and "covert" saccades).
 c) absent cVEMP in left ear.

- systems (visual and somatosensorial) – use of smooth pursuit instead of the non-functional vestibulocular reflex (VOR), for example.
- Functional substitution – use of alternative strategies, with different

- effectors than the damaged vestibular ones: prediction, saccades instead of VOR or extensive use of cervical inputs.
- Behavioural changes in order to minimise vestibular challenges and demands.

All above mentioned processes except the first one (restoration of peripheral function) acts competitively: all start simultaneously and act redundantly but using of one of them may eliminate the need for others. This selection of main central compensation process is one of the explanations for variable outcomes of the same process in different patients – dependence on visual substitution impedes upon somatosensorial substitution mechanisms and vice versa. Customised vestibular rehabilitation programmes might diminish this limit of the natural recovery phenomena [21-25], as well as specific drug therapy [26]. The overall outcome of central compensation process is also influenced by its delay in action. There is a critical period when neuroplasticity of the vestibular central structures is highest (first month after the acute injury) and patients must take advantage of this time-window opportunity in order to trigger early recovery mechanisms [27,28]. Lying still in bed, stiffed neck movements and vestibular suppressants should be limited to three days at most, in order to manage properly the UVL's long-term functional symptoms.

CONCLUSION

Central compensation represents a natural, physiologic healing process of an acute unilateral vestibular loss. Its benefit is greater if process starts early, vestibular central structures are lesion-free, substitution sensorial systems (vision and somatosensorial) are normal and early available. Customised vestibular rehabilitation programmes and drugs which facilitate specific neurotransmitters discharge in vestibular pathway are recommended in order to enhance, enlarge and fulfil recovery of the dynamic vestibular deficits.

REFERENCES

- de Waele C, Vidal PP, Tran Ba Huy P, Freyss G (1990) Vestibular compensation. Review of the literature and clinical applications. *Ann Otolaryngol Chir Cervicofac.* 107: 285-98. PMID: 2221721.
- Lacour M (1989) *Vestibular Compensation: Facts, Theories, and Clinical Perspectives.* Elsevier, Amsterdam.
- Pfaltz CR, Kamath R (1970) Central compensation of vestibular dysfunction-peripheral lesion. *Pract Otorhinolaryngol* 32: 335-349. doi: 10.1159/000274957 PMID: 5313795.
- Markham CH, Yagi T, Curthoys IS (1977) The contribution of the contralateral labyrinth to second order vestibular neural activity in the cat. *Brain Res* 138: 99-109. doi: 10.1016/0006-8993(77)90786-7 PMID: 589471.
- Markham CH, Yagi T (1984) Brainstem changes in vestibular compensation. *Acta Otol Suppl* 406: 83-86. doi: 10.3109/00016488309123009 PMID: 6591718.
- Melville Jones G (1996) How and why does the vestibulo-ocular reflex adapt? In: Baloh and Halmagyi (ed), *Disorders of the Vestibular System*, Oxford.
- Newlands SD, Perachio AA (1990) Compensation of horizontal canal related activity in the medial vestibular nucleus following unilateral labyrinth ablation in the decerebrate gerbil. I. Type I neurons *Exp Brain Res* 82: 359-372. doi: 10.1007/BF00231255 PMID: 2286238.
- Newlands SD, Perachio AA (1990) Compensation of horizontal canal related activity in the medial vestibular nucleus following unilateral labyrinth ablation in the decerebrate gerbil. II. Type II neurons *Exp Brain Res* 82: 373-383. doi: 10.1007/BF00231256 PMID: 2286239.
- Lacour M, Sterkers O. (2001) *CNS drugs.* 15: 853-570.
- Courjon JH, Flandrin JM, Jeannerod M, Schmid R (1982) The role of the flocculus in vestibular compensation after hemilabyrinthectomy. *Brain Res* 239: 251-257. doi: 10.1016/0006-8993(82)90847-2 PMID: 7093679
- Llinas R, Walton K (1977) Significance of the olivo-cerebellar system in compensation of ocular position following unilateral labyrinthectomy. In: Baker R, Berthoz A (Eds). *Control of gaze by brainstem neurons* pp 399-408.
- Darlington CL, Smith PF (2000) Molecular mechanisms of recovery from vestibular damage in mammals: recent advances. *Prog Neurobiol* 62: 313-325. doi: 10.1016/S0301-0082(00)00002-2 PMID: 10840152.
- Kitahara T, Takeda N, Kiyama H, Kubo T (198) Molecular mechanisms of vestibular compensation in the central vestibular system-review. *Acta Otolaryngol Suppl* 539: 19-27. doi: 10.1080/00016489850182675-1 PMID: 10095856.
- Allum JHJ, Yamane M, Pfaltz CR (1988) Long-term modifications of vertical and horizontal vestibulo-ocular reflex dynamics in man. *Acta Otolaryngol* 105: 328-337. doi: 10.3109/00016488809097015 PMID: 3389119.
- Baloh RW, Honrubia V, Yee RD, Hess K (1984) Changes in human vestibulo-ocular reflex after loss of peripheral sensitivity. *Ann Neurol* 16: 222-228. doi: 10.1002/ana.410160209 PMID: 6476793.
- McDonnell MN, Hillier SL (2015) Vestibular rehabilitation for unilateral peripheral vestibular dysfunction. *Cochrane Database Syst Rev* 17: CD005397. doi: 10.1002/14651858.CD005397 PMID: 25581507.
- Bronstein Am, Hood JD (1986) The cervico-ocular reflex in normal subjects and patients with absent vestibular function. *Brain Res* 373: 399-408. doi: 10.1016/0006-8993(86)90355-0 PMID: 3487371.
- Halmagyi GM, Curthoys IS, Cremer PD, Henderson CJ, Todd MJ, et al. (1990) The human horizontal vestibulo-ocular reflex in response to high-acceleration stimulation before and after unilateral vestibular neurectomy. *Exp Brain Res* 81: 479-490. doi: 10.1007/bf02423496 PMID: 2226683
- Halmagyi M, Curthoys I (1996) How does the brain compensate for vestibular lesions? In: Baloh, Halmagyi (editors), *Disorders of the Vestibular System*. Oxford.
- Maioli C, Precht W (1983) On the role of vestibulo-ocular reflex plasticity in recovery after unilateral peripheral vestibular lesions. *Exp Brain Res* 59: 267-272. doi: 10.1007/bf00230906 PMID: 3875498.
- Hall CDI, Herdman SJ, Whitney SL, Cass SP, Clendaniel RA, et al. (2016) Vestibular Rehabilitation for Peripheral Vestibular Hypofunction: An Evidence-Based Clinical Practice Guideline. *J Neurol Phys Ther* 40: 124-155. doi: 10.1097/NPT.000000000000120 PMID: 26913496.
- Georgescu M, Sorina S (2011) Vestibular neuronitis in pregnancy, *Gineco eu* 7: 58-61.
- Georgescu Madalina, Stoian Sorina, Mogoanță Carmen Aurelia, Ciubotaru Gh.V. Vestibular rehabilitation – election treatment method for compensating vestibular impairment, *Romanian Journal of Morphology and Embryology* 2012, 53 (3):651-656, ISSN (print) 1220-0522, ISSN (online) 2066-8279.
- Georgescu M (2017) Vestibular Rehabilitation – Recommended Treatment for Permanent Unilateral Vestibular Loss, *Int J Neurorehabilitation Eng* 4: 4. doi: 10.4172/2376-0281.1000282.
- Herdman SJ (2014) *Vestibular Rehabilitation* 4th Edition.
- Smith PF, Darlington CL, Curthoys IS (1986) Vestibular compensation without brainstem commissures in the guinea pig. *Neurosci Lett* 65: 209-21. doi: 10.1016/0304-3940(86)90306-x PMID: 3487051.
- Smith PF, Darlington CL, Curthoys IS (1986) The effect of visual deprivation in vestibular compensation in the guinea pig. *Brain Res* 364: 195-198. doi: 10.1016/0006-8993(86)91004-8.
- Zee DS. Vestibular Adaptation in Vestibular Rehabilitation. In: Herdman S (editor) *F.A. Davis*, 19.

Successful Cochlear Implantation under Local Anesthesia and Sedation: A case Report

Barbara Stanek, Bernhard Gradl, Astrid Magele, Georg Mathias Sprinzl*

ABSTRACT

With the increasing life expectancy, also the number of patients suffering from age-related severe to profound hearing loss is rising. In the past Cochlear Implantation in elderly was performed with low expectations in improved hearing performance and handled as a high risk intervention due to age related health challenges. Latest studies showed that Cochlear Implantation is a safe procedure in elderly patients and that this group of patients is able to benefit regarding speech perception and life quality. Usually hearing device implantations are performed under general anesthesia, which may pose a restrictive factor for surgery, especially in elderly patients presenting with comorbidities. The here presented case describes how anesthesia may be circumvented by performing Cochlear Implantation under local anesthesia and sedation. A 72-year old man presented himself with acute severe to profound sensorineural hearing loss in his right ear, due to herpes zoster oticus. In addition he suffered from pre-existing deafness in his left ear. No improvement in hearing and no benefit after trialing a conventional hearing aid for a period of six months were noted. Further examinations revealed the patient to be a suitable candidate for Cochlear Implantation in his right ear. Due to significant comorbidities, general anesthesia was contraindicated. Thus surgery was performed under local anesthesia and sedation. The procedure was successfully performed and no adverse events or surgical complications occurred. Cochlear Implantation under local anesthesia and sedation may serve as a valuable option for patients not suitable for general anesthesia.

KEYWORDS: Cochlear implantation, Elderly patients, Local anesthesia

INTRODUCTION

Hearing loss is one of the most common sensory impairments with the elderly population being predominantly affected. Depending on the degree of hearing loss, many candidates can be successfully fitted with hearing aids. Cochlear Implants represent the current treatment for patients of all ages affected by profound sensorineural hearing loss in one or both ears. For individuals with this type of hearing loss, hearing aids provide little or no benefit. Thus surgery has been performed for more than 30 years featuring a low rate of complications [1]. Due to the increasing life expectancy, interest in hearing rehabilitation of elderly patients has progressively risen in the recent years. Demographic data reports that in industrialized countries the proportion of people over the age of

65 years will increase from 28% in 2015 to 40% in 2035 [2]. Age-related processes within the Cochlear cause damage of the inner hair cells followed by a low to moderate hearing loss which may progress into severe hearing loss up to deafness. In cases where conventional hearing aids do not achieve any improvement in hearing, Cochlear Implantation poses a feasible and safe treatment option. Unfortunately in many elderly patients the decision of hearing rehabilitation surgery is often handled reluctantly as the risk of surgery is deliberated against the benefits of hearing gain. Additional reasons against a Cochlear Implantation are possible difficulties with the handling of the audio processor as well as comorbidities prohibiting general anesthesia. This paper describes a case in which Cochlear Implantation was performed under local anesthesia and sedation in a 72 year old male.

CASE REPORT

A 72-year-old male with herpes zoster oticus with a vestibulocochlear lesion and accompanying acute profound sensorineural hearing loss and a neuropathy vestibularis in the right ear presented to our clinic. The patient suffered from a right sided facial palsy occurring a few days after his visit. The left ear was diagnosed 20 years ago with chronic recidivating otorrhea in terms of otitis media chronica simplex resulting in a deaf left ear. Further anesthesia hindering co-morbidities were coronary heart disease, left ventricular dysfunction, COPD (chronic obstructive pulmonary disease), diabetes mellitus, essential hypertension and dyslipidemia. The audiogram showed a decline in bone conduction thresholds on the right side from 50dB HL at 250Hz to 80dB HL at 3000Hz with an air-bone gap of 10dB. On the left side the air- and bone conduction

Department of Otolaryngology, University Hospital St. Pölten, Karl Landsteiner University, Austria

*GeorgMathias.Sprinzl@stpoelten.lknoe.at

threshold were 90dB HL to 110dB HL (Fig. 1). Monosyllabic intelligibility tests scored 10% at 95dB and 55% at 110dB on his right ear and 0% at 110dB on his left ear (Fig. 2). Given the severity of his hearing loss, communication of the patient was only possible in written form. At that time the patient was already suffering from social exclusion and incipient depression. The patient was administered to hospital and received intravenously valaciclovir and corticosteroids. Despite of six months of treatment therapy no improvement in hearing on his right ear was observed. The patient was provided with a behind-the-ear hearing aid, which did not generate subjective nor audiological benefit. The recognition of speech was 0% at 65dB and 10% at 80dB with its best possible setting. Thereupon the evaluation regarding Cochlear Implantation started: Computed Tomography of the

petrous bone conducted for previous diagnosis purposes, further audiological examinations, Magnetic Resonance Tomography and a Vestibulometry were initiated. The patient met the indication criteria for Cochlear Implantation. Pre-operative multidisciplinary examinations (echocardiography, pulmonary function, ECG, internal survey) revealed that general anesthesia was too risky due to afore mentioned comorbidities. After discussing the options with the patient, it was decided to perform Cochlear Implantation under local anesthesia.

SURGICAL RECORD

A Cochlear SYNCHRONY Standard Electrode from MED-EL (Innsbruck, Austria) was implanted. Due to the local anesthesia no facial monitoring was performed. The local anesthesia protocol included at first 5 ml Xylonest® 1% with epinephrine 1:200.000 injection

solution submitted into the retro auricular region. A retro auricular cut, following a mastoidectomy and posterior tympanotomy with a bony implant bed were performed. Cochleostomy approach for electrode insertion was conducted due to the round window anatomy. ART (auditory nerve response telemetry) and impedance measurements were undertaken intra-operatively without abnormal occurrences. The surgical intervention lasted 60 minutes and no complications were reported. No pain of the patient himself was indicated during the intervention.

ANESTHESIA RECORD

The surgery was executed with an anesthesiology in standby. Pre-operatively the patient received Midazolam. Intra-operative monitoring included an ECG, a pulse oximetry as well as constant blood pressure measurements. Oxygen (4 L

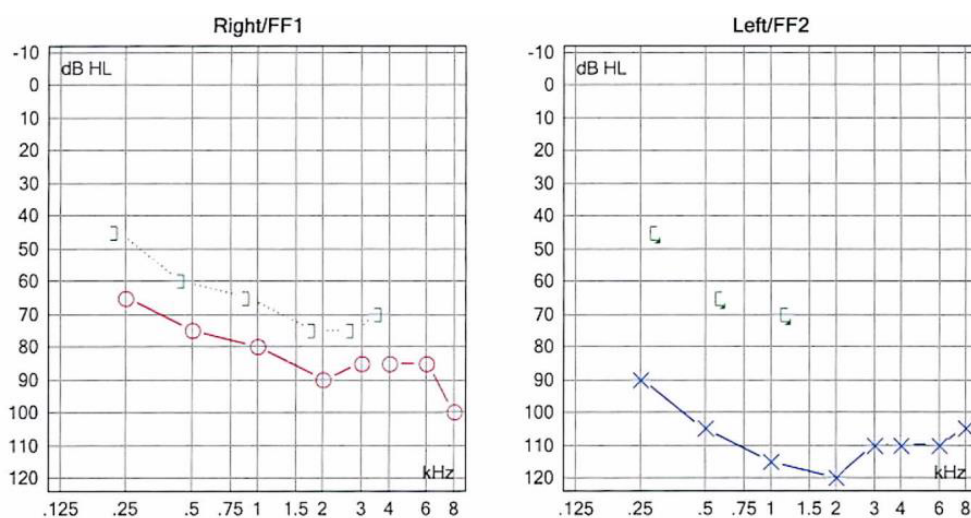


Fig 1. Pre- operative pure tone audiogram.

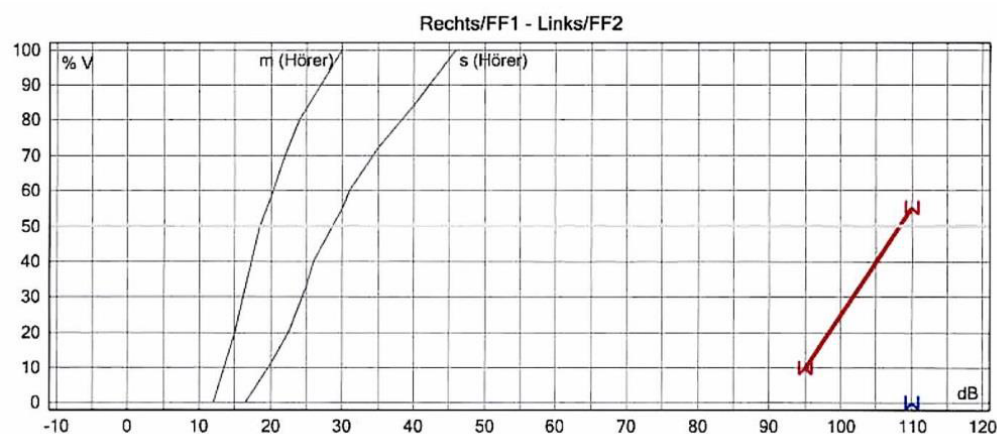


Fig 2. Pre- operative speech audiometry (red-right ear, blue-left ear) (monosyllables).

SUCCESSFUL COCHLEAR IMPLANTATION UNDER LOCAL ANESTHESIA AND SEDATION: A CASE REPORT

min) was delivered through an oronasal mask. To initiate and maintain a mild sedation, the patient received in total 0.05 mg Fentanyl and 10 mg Ketanest administered in a small bolus based on patients' comfort. Furthermore 4 mg of Dexamethasone and 4 mg of Zofran were given as a prophylactic antiemetic.

RESULTS

Post-operatively no pain, nausea or vomiting occurred. The patient reported dizziness which was already present pre-operatively. For infection prevention intravenous antibiotics were applied for five days. The patient was released on the fifth post-operative day. Following implant activation, one month after surgery, verbal communication was immediately possible, which was not feasible pre-operatively. CI-aided free field measurements on the right ear revealed 45dB HL at 250Hz, 30dB at 1.000Hz, 35dB HL at 2.000Hz

and 35dB at 4.000Hz (Fig. 3). The Freiburg monosyllables test revealed 10% word recognition scores at 65dB and 40% at 80dB in the CI aided condition after one month. The Freiburg number test resulted in 100% understanding at 65dB (Fig. 4). The three months follow-up free field measurements remained constant. The monosyllabic intelligibility of the patient improved about 35% at 65dB and 55% at 80dB (Fig. 5). The satisfaction and benefit of the patient remained high and he stated to undergo surgery under local anesthesia again.

DISCUSSION

Due to the increasing life expectancy typical diseases related to elderly people are undoubtedly rising as well. For instance the WHO estimates disabling hearing loss in persons above 65 years of age in over 30% of the population. Understandably, due to this demographic tendency,

hearing impaired patients as well as the public's interest on possible treatment options is ever increasing. At the St. Pölten University Medical Center the average implantation age raised from 48 years in 2014 to 51 years in 2017. Studies revealed that untreated hearing loss poses a risk factor for the development of dementia, cognitive decline, anxiety and depression [3-5]. The here presented case reported of such depressive moods due to the distinctive discomfort and isolation already shortly after losing his hearing. Unfortunately, Cochlear Implantation in elderly is often associated with increased operative risks and therefore other, less satisfying, therapies are opted for. Coelho et al. and Büchschütz et al. proved that Cochlear Implantation is a safe procedure in healthy patients regardless of age [6,7] also vertigo and wound healing difficulties were not reported more frequently in the elderly population [8]. Importantly,

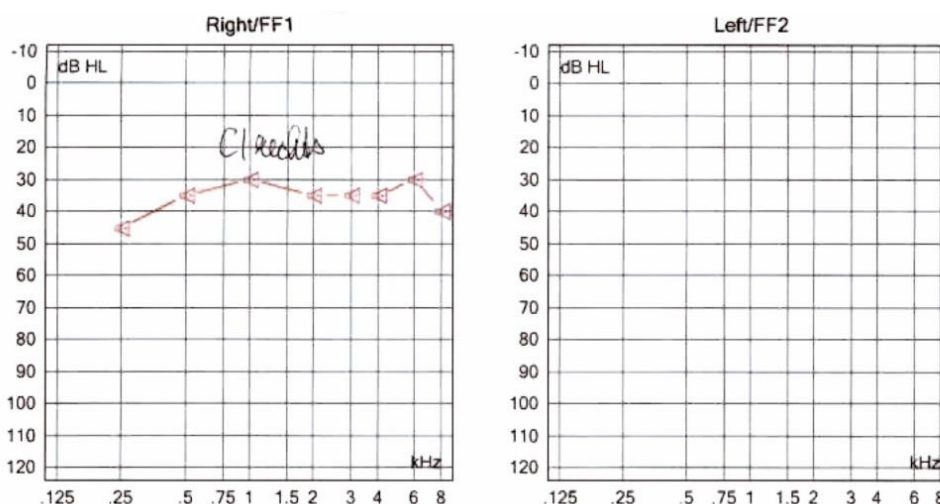


Fig 3. Free field audiogram 1 month post-operative.

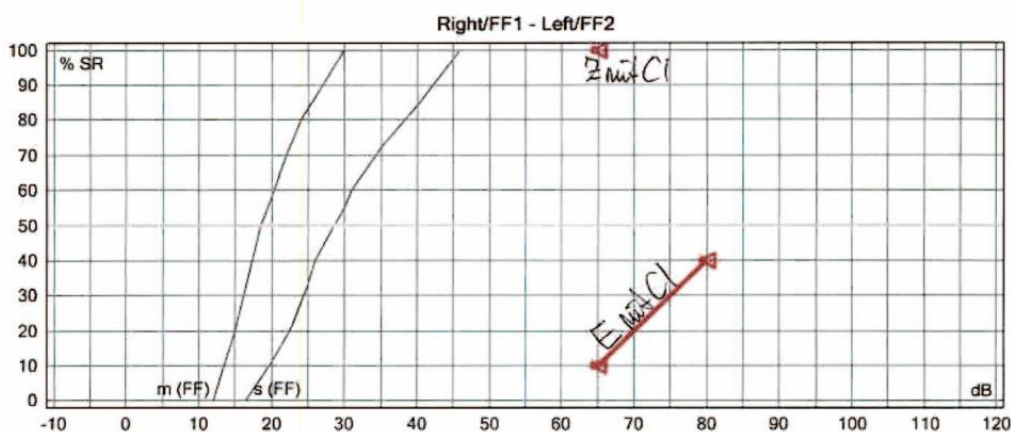


Fig 4. Speech Audiometry 1 month post-operative [Numbers (Z) and Monosyllables (E)].

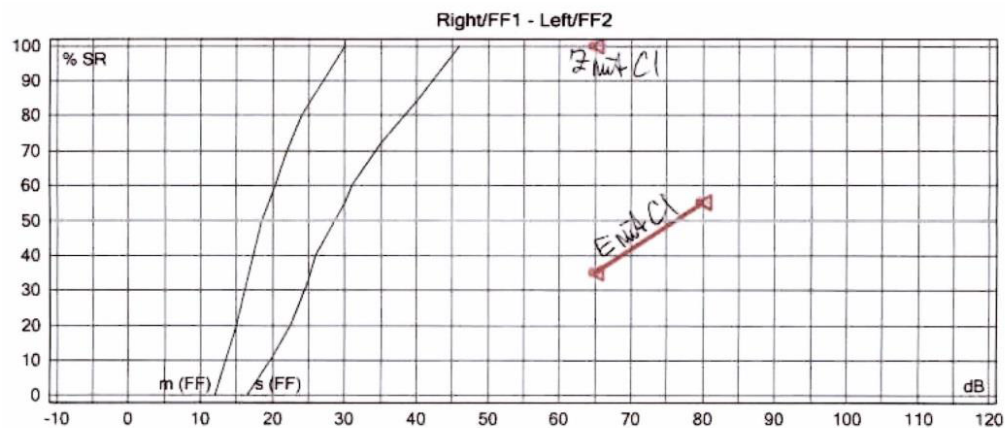


Fig 5. Speech Audiometry 3 months post-operative [Numbers (Z) and Monosyllables (E)].

this group of patients benefits especially from an implantation in terms of speech recognition and improved Quality of Life [9,10]. Typically Cochlear Implantation is undertaken under general anesthesia representing an additional risk factor for elderly people. If comorbidities are present, as in the here presented case, general anesthesia poses a considerable risk, which may, even given appropriate indication for Cochlear Implantation, results in a rejection of surgery for the patient. Since a number of different ear surgeries are routinely performed under local anesthesia, it only seems obvious, that Cochlear Implantation may be performed under local anesthesia as well. Previous studies clearly showed that the complication rate and the post-operative duration of hospitalization of Cochlear Implantation under local anesthesia did not differ compared to general anesthesia. No differences related to vertigo, nausea and post-operative pain were observed. This is in agreement with our observation. The mean duration of the surgical intervention in the group of the Cochlear Implants under local anesthesia was significantly lower compared to surgeries under general anesthesia, representing an additional positive effect for elderly patients [11-13].

CONCLUSION

Cochlear implantation surgery proved to be a good and viable option for hearing rehabilitation in the elderly population. Profoundly deaf patients may still be implanted under local anesthesia without generating additional health issues caused by present comorbidities.

SUMMARY

- Case report of a 72-year old man.
- Patient suffered acute severe to profound sensorineural hearing loss (right ear) and pre-existing deafness (left ear).
- Patient reported social isolation followed by depression due to hearing impairment.
- The patient unsuccessfully trialed conventional hearing aids for 6 months.
- Patient was indicated for Cochlear Implantation (right ear) but significant comorbidities contraindicated surgery under general anesthesia.
- Therefore surgery was performed under local anesthesia and sedation.
- Intervention lasted 60 minutes and procedure was successfully performed and no adverse events or surgical complications occurred.
- Hearing rehabilitation was successful one month post-operative and improved further. Communication immediately possible again after activation.
- The patient reported improved hearing benefit and Quality of Life.

REFERENCES

1. Lenarz T (2017) Cochlear Implant - State of the Art. *Laryngo-rhino-otologie* 96: S123-S151. DOI: 10.1055/s-0043-101812 PMID: 28499298
2. Nations U (2015) World Population Prospects: The 2015 Revision, Methodology of the United Nations Population Estimates and Projections.

3. Contrera KJ, Betz J, Deal JA, Choi JS, Ayonayon HN, et al. (2016) Association of hearing impairment and emotional vitality in older adults. *J Gerontol B Psychol Sci Soc Sci* 71: 400-404. doi: 10.1093/geronb/gbw005 PMID: 26883806.
4. Deal JA, Betz J, Yaffe K, Harris T, Purchase-Helzner E, et al. (2017) Hearing impairment and incident dementia and cognitive decline in older adults: the health abc study. *J Gerontol A Biol Sci Med Sci* 72: 703-709. doi: 10.1093/gerona/glw069 PMID: 27071780.
5. Lin FR, Metter EJ, O'Brien RJ, Resnick SM, Zonderman AB, et al. (2011) Hearing loss and incident dementia. *Arch Neurol* 68: 214-20. doi: 10.1001/archneurol.2010.362 PMID: 21320988.
6. Coelho DH, Yeh J, Kim JT, Lalwani AK (2009) Cochlear implantation is associated with minimal anesthetic risk in the elderly. *Laryngoscope* 119: 355-358. doi: 10.1002/lary.20067 PMID: 19160385.
7. Büchsenstütz K, Arnolds J, Bagus H, Fahimi F, Günnicker M, et al. (2015) Surgical risk profile and audiological outcome in the elderly after cochlea-implantation. *Laryngo-rhino-otologie* 94: 670-675. doi: 10.1055/s-0034-1390454 PMID: 25437836.
8. Holinski F, Elhajzein F, Scholz G, Sedlmaier B (2012) Vestibular disorders after cochlear implant in adults. *HNO* 60: 880-885. doi: 10.1007/s00106-012-2526-x PMID: 22733278.
9. Ramos A, Guerra-Jiménez G, Rodríguez C, Borkoski S, Falcón JC, et al. (2013) Cochlear implants in adults over 60: a study of communicative benefits and the impact on quality of life. *Cochlear Implants Int* 14: 241-245. doi: 10.1179/1754762812Y.0000000028 PMID: 23510755.
10. Jin SH, Liu C, Sladen DP (2014) The effects of aging on speech perception in noise: comparison between normal-hearing and cochlear-implant listeners. *J Am Acad Audiol* 25: 656-665. doi: 10.3766/jaaa.25.7.4 PMID: 25365368.
11. Mistry SG, Carr S, Martin J, Strachan DR, Raine CH, et al. (2017) Cochlear implantation

SUCCESSFUL COCHLEAR IMPLANTATION UNDER LOCAL ANESTHESIA AND SEDATION: A CASE REPORT

under local anaesthesia - Our experience and a validated patient satisfaction questionnaire. *Cochlear Implants Int*, 18: 180-185. doi: 10.1080/14670100.2017.1296986 PMID: 28274186.

12. Toner F, Jackson CP, Toner JG (2013) How we do it: Local anaesthetic cochlear implantation. *Cochlear Implants Int*, 2013. 14: 232-235. doi: 10.1179/1754762812Y.0000000016 PMID: 24001710.

13. Hamerschmidt R, Moreira AT, Wiemes GR, Tenório SB, Tâmbara EM (2013) Cochlear implant surgery with local anesthesia and sedation: comparison with general anesthesia. *Otol Neurotol* 34: 75-78. doi: 10.1097/MAO.0b013e318278c1b2 PMID: 23187931.